

The BACJAC™ Interspinous Device in the Treatment of Lumbar Spine Degenerative Disorders: A Prospective Study and 2-Year Follow-Up Results

Irace C*, Giannachi L, Amato V and Corona C

Department of Neurosurgery, Hospital IGEA, Milan, Italy

*Corresponding author: Claudio Irace, Department of Neurosurgery, Hospital IGEA, via Marcona 69, 20129 Milan, Italy, Tel: +393398168539; Fax: +390270142409; E-mail: neurosurgery@casadicuraigea.it

Received: Feb 05, 2014; Accepted: Apr 12, 2014; Published: Apr 15, 2014

Copyright: © 2014 Irace C, et al. This is an open-access article distributed under the terms of the Creative Commons Attribution License, which permits unrestricted use, distribution, and reproduction in any medium, provided the original author and source are credited.

Abstract

Background: In the last two decades lumbar interspinous decompression systems have gained a wide and often uncontrolled diffusion. Such devices, usually made of titanium or PEEK (polyetheretherketone), are currently implanted in different lumbar spine degenerative disorders, and clinical indications to their use are often confounding.

Methods: This is a single center, single arm, 2-year prospective study of 50 patients undergoing lumbar surgical interspinous decompression, in which the BacJac all-PEEK device was implanted. Preoperative diagnosis was: central (CLS) or foraminal (FLS) spinal stenosis, degenerative antero/retro listhesis < grade I (LAL/RAL), Degenerative Disc Disease (DDD), Recurrent Disc Protrusion (RDP), Lumbar Synovial Cyst (LSC). Clinical and neuroradiological assessment was performed by means of Visual Analog Scale (VAS) plus a novel 3-arm scale (IGEA), Computed Tomography (CT), Magnetic Resonance (MR) and x-rays images.

Results: The 2-year follow-up examination was performed in 47 patients (94%); three patients were lost. Thirty-nine out of forty-seven (83%) patients improved, and the remaining eight were considered unchanged. The VAS score improved from 7.5 preoperatively to 3.0 postoperatively; the IGEA-L score improved from 3.0 to 1.7; the IGEA-R score passed from 2.93 to 1.5; the IGEA-CI improved from 3.5 to 1.5. No major complications were observed; in five cases rupture of a spinous process was observed.

Conclusions: Our series is the first prospective study concerning the use of a PEEK interspinous device in the treatment of lumbar spine degenerative disorders. We think the BacJac interspinous spacer, as stand-alone implant or following uni or bilateral decompression, may provide mid-term relief of low-back and radicular pain, as assessed by VAS and IGEA scales, and improvement of neurogenic intermittent claudication, in some lumbar spine degenerative disorders, mainly in central and foraminal stenosis.

Keywords: BacJac spacer; Interspinous process decompression; Interspinous spacer; Irace method; Lumbar spine surgery; Neurogenic intermittent claudication

Introduction

In the last two decades interspinous devices have gained a wide popularity in lumbar spine surgery. The Wallis implant, made of PEEK (polyetheretherketone) and Dacron bands, was one of the first spacers to be largely used in patients affected by lumbar spinal stenosis, particularly in non-English speaking countries [1]. Subsequently the DIAM spacer gave a new impulse to this kind of surgery, due to its properties of posterior dynamic stabilization, meaning the 'desire to restore or maintain segmental stability without arthrodesis' [2]; this conceptualization of semi-rigidity probably opened the road to the adoption of these spacers in degenerative lumbar spine disorders other than stenosis. Basing upon strong research and clinical evidences, the X-STOP device has been recognized as having a role in the surgical treatment of lumbar spinal stenosis causing Neurogenic Intermittent Claudication (NIC), particularly if compared with non-operative therapy and decompressive surgery [3]. The Coflex U-shaped titanium implant has

been used in same clinical scenarios [4] and in its latest version it is used as an adjunct to interbody fusion.

We here report our experience concerning a series of patients, who received surgical implant of the BacJac Interspinous device for the treatment of some lumbar spine degenerative disorders, aiming to shed a light over features of this device and try delineating well-defined indications for its clinical (proper!) use (many other Interspinous devices are currently used in lumbar spine surgery; however the heterogeneity of clinical indications has made difficult enough the definition of when and why these systems be recommended and implanted).

Materials and Methods

The device and technique of implantation

The BacJac™ (Pioneer Surgical Technology, Marquette, MI, USA) is a radiolucent spacer made of PEEK (polyetheretherketone) Optima (PEEK Optima, Invibio, Greenville, NC, USA); PEEK is a thermoplastic with an elastic modulus close to that of bone [5] (Figure 1). This implant produces a significant restriction of lumbar extension in the flexion-extension motion.

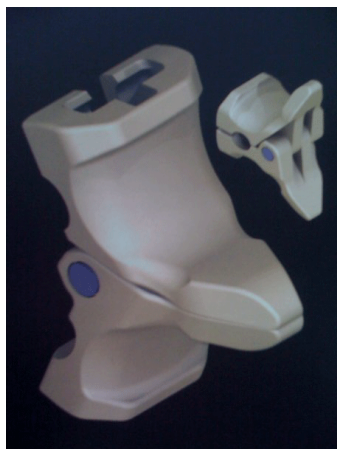

Figure 1: The BacJac device. The big image shows the device in its asset before implant; the small image represents it once deployed. The violet circle is the Ti-pivot which serves as radiological marker

Under local or mild general anesthesia, with the patient being prone in a very mild de-lordosis, a 5 cm skin incision is done centered over the affected lumbar interspinous space. After application of two different dilators and subsequent sizer, the self-installing spacer is inserted through the interspinous ligament (with the supraspinous ligament being left intact). Intraoperative x-ray or fluoroscopy is done before skin incision (Irace method) [6] and once the spacer is implanted (Figure 2). This unilateral procedure may be also done after a uni- or bilateral decompressive surgical step (Figure 3).

Five different sizes (8,10,12,14 and 16 mm) are available; the BacJac device is also designed to be implanted at L5-S1.

Patient population and data

From July 10, 2010 until January 31, 2012, 50 patients underwent a lumbar surgical procedure in which a BacJac device was implanted; these operations were performed by the first author (I.C.) at the Department of Neurosurgery of IGEA Hospital (Milan, Italy). The index operation was performed in different lumbar spine degenerative disorders (Table 1); all of the patients complained of a combination of low-back pain, leg pain and NIC, that had not been resolved by means of a regimen of at least one month of anti-inflammatory medication and physical therapy (Figure 4). They all presented with a Visual Analog Scale (VAS) score for low-back pain ≥ 6 (1-10 cm scale).

Patients with severe osteoporosis, osteopenia, metabolic bone disease, evidence of fracture of the vertebral bodies and/or the spinous processes planned for implant, spondylolisthesis > grade 1, spondylolysis, significant scoliosis, extreme obesity (BMI > 40), malignancies and major medical disease, were excluded for surgery. Patients who had undergone previous posterior instrumentation operations were also not considered for BacJac implant.

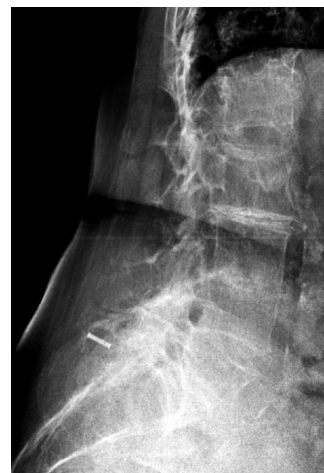

Figure 2: X-ray lateral view. The BacJac spacer implanted at L5-S1, as confirmed by the radiopaque Ti-pivot

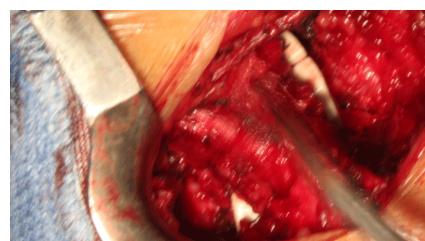

Figure 3: Intraoperative photograph of the BacJac spacer. The suction tube points the intact supraspinous ligament; on both sides parts of the deployed device may be seen

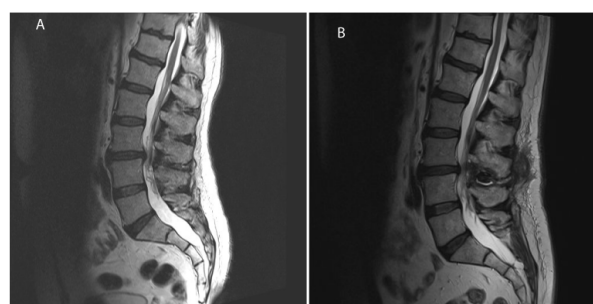


Figure 4: MR sagittal T2-weighted images of a patient affected by an L3-L4 central stenosis. Preoperative (a); the 2-year postoperative (b) scan shows the correct positioning of the BacJac device and the maintenance of a good lumbar alignment

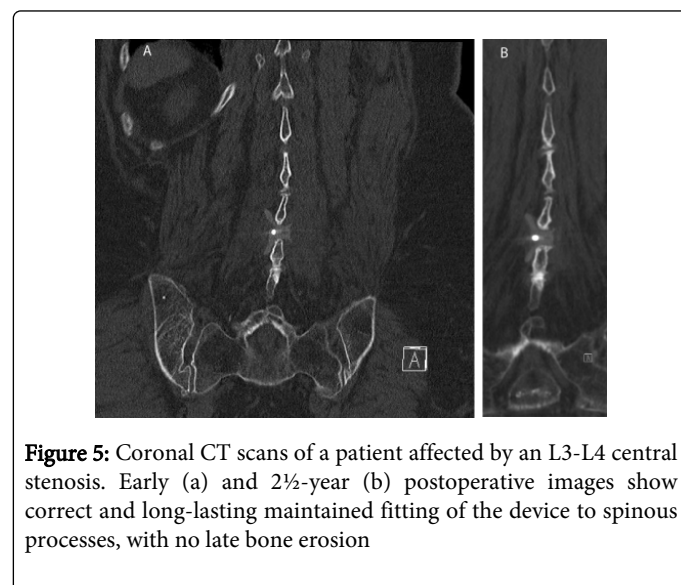
Clinical, functional and neuroradiological assessment

Pain and disability were assessed using the VAS score for low-back pain and novel 3-arms rating system developed in our Department: the 'IGEA' Lumbar (IGEA-L), Radicular (IGEA-R) and Claudication (IGEA-CI) scales (from the name of our institution). These three scales

represent a relevant, quick and user-friendly assessment system which, unlike others, evaluates main symptoms of degenerative lumbar spine disorders: low-back pain, radicular pain and neurogenic claudication. These scales assess the following items respectively: low-back pain (rated 1 to 4), radicular pain (1 to 4) and claudication (0 to 5); the global score rates 2 to 13 (Table 2). Preoperative VAS and three-IGEA scores were collected from all of our patients and were then compared with those registered at the scheduled 2-year follow-up evaluation. Preoperative neuroradiological assessment included Computed Tomography (CT) and Magnetic Resonance (MR) images for all patients; plain and flexion/extension x-rays of the lumbar spine were also performed when instability was suspected. All patients performed CT scan early postoperatively, at 6 and 12 months (Figure 5); MR scan and dynamic lumbar x-rays were done at 12 and 24 months.

Diagnosis	nr of cases / (%)
Central lumbar stenosis (CLS)	18/(36)
Foraminal lumbar stenosis (FLS)	5/(10)
Degenerative disc disease (DDD)	7/(14)
Recurrent disc protrusion (RDP)	10/(20)
Lumbar synovial cyst (LSC)	2/(4)
Lumbar antero/retrolisthesis (LAL/LRL)	8/(16)
Total	50/(100)

Table 1: Indications to BacJac implant



Statistical analyses (performed by the second Author, G.L.) were based upon all available data for those patients who had completed the 2-year follow-up. The statistical significance value (p-value) was calculated by means of paired T-test based on the difference; longitudinal change between pre- and postoperative scores was determined. The results were analyzed following T Student distribution table for degrees of freedom (e.g., 46 patients=n-1), calculating the standard deviation as the mean difference between pre- and postoperative values.

Low-back pain (IGEA-L)	Radiculopathy (IGEA-R)	Claudication (IGEA-CI)
1 (absent)	1 (absent)	0 (absent)
2 (mild) - occasional use of drugs	2 (mild)	1 (>1000 metres)
3 (moderate) - frequent use of drugs	3 (moderate)	2 (500-1000 metres)
4 (severe)	4 (severe)	3 (200-500 metres)
- uninterrupted use of drugs		4 (100-200 metres)
- severe functional limitation		5 (<100 metres)

Table 2: 'IGEA' Lumbar (IGEA-L), Radicular (IGEA-R) and Claudication (IGEA-CI) scales

Results

Of the 50 implanted patients, 21 (42%) were male and 29 (58%) female. The mean age at the time of surgery was 60.5 years (range 38-83). A single device was inserted in all of our patients and the BacJac instrumented levels were: L1-L2 in 2 cases (4%), L2-L3 in 4 (8%), L3-L4 in 11 (22%), L4-L5 in 23 (46%), L5-S1 in 8 (16%), L4-L5 (transitional) in 2 (4%). The implant sizes are listed in Table 3.

Implant size (mm)	nr of implants (%)
8	16 (32)
10	18 (36)
12	13 (26)
14	2 (4)
16	1 (2)
Total	50(100)

Table 3: BacJac device size in implanted patients

The 2-year follow-up examination was performed in 47 patients (94%); three patients were lost. The mean VAS score improved from 7.5 preoperatively to 3.0 ($p<0.025$; $t=2.109$); the IGEA-L score also improved from 3.0 preoperatively to 1.7 ($p<0.01$; $t=2.459$) at the study-end control; the preoperative IGEA-R score was 2.93 preoperatively and 1.5 ($p<0.005$; $t=2.922$) 2-year postoperatively; the IGEA-CI improved from 3.5 to 1.5 ($p<0.02$; $t=2.27$) (Table 4). Particularly, 39 out of 47 patients (83%) were considered improved (reduction of VAS, IGEA-L, IGEA-R and IGEA-CI scores); 8 out of 47 (17%) patients were considered slightly improved or unchanged; no patient frankly deteriorated after the BacJac implant.

In 14 out of 50 patients an additional evaluation was done 3 years after surgery: reduction of VAS, IGEA-L, IGEA-R, IGEA-CI scores was confirmed in 12 out of 14 and neuroradiological assessment revealed a good outcome too (Figure 6).

Outcome scale (range)	Preoperative	2-year postoperative	p (paired t-test)
	Mean score	Mean score	
VAS (cm) (0-10)	7.5	3.0	p<0.025
IGEA-L (1 - 4)	3.0	1.7	p<0.001
IGEA-R (1 - 4)	2.9	1.5	p<0.005
IGEA-CI (0 - 5)	3.5	1.5	p<0.02

Table 4: Preoperative and 2-year follow-up: functional assessment

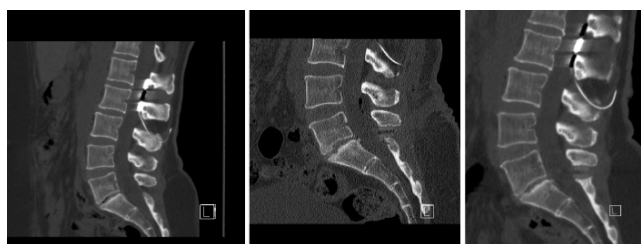


Figure 6: Sagittal CT reformatted scans of a patient affected by L5-S1 DDD (two previous surgeries for disc herniation+epidural lead for spinal cord stimulation). Preoperative (a); early (b) and 3-year postoperative (c) images show good positioning of the BacJac device, disappearing of gas in the disc space, no late bone erosion

At last follow-up none of the patients underwent surgery at different lumbar levels; in one case plain lumbar x-rays performed 30 months after surgery, following a car accident, revealed an impressively unexpected corticalization of the L5-S1 BacJac device and the development of a transitional syndrome; this patient is under observation for future L4-L5 posterior arthrodesis (Figure 7).

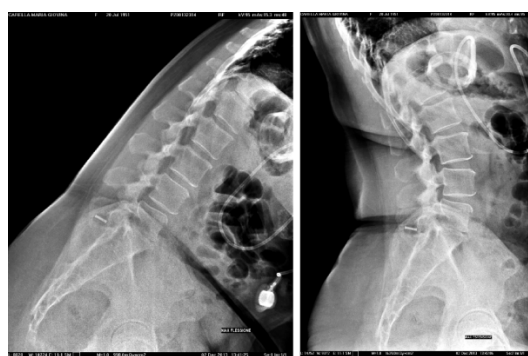


Figure 7: Flexion-extension lumbar x-rays of a patient affected by post-surgical L5-S1 retrolisthesis. Corticalization (heterotopic ossification?) may be seen superficial to the device and de-novo anterolisthesis at the adjacent level

Complications

The only complication in this series was fracture of the spinous process, which occurred in 5 out of 50 patients (10%). The involved

level was L4-L5 and the fracture involved the cranial spinous process in all but one case. Interestingly, no 'pain-sentinel' was reported, and such complication was discovered only by means of CT scan, performed routinely on postoperative day 1. All of these affected patients were treated by means of lumbar corset for two months; late follow-up CT scan showed good healing of the fracture (Figure 8).

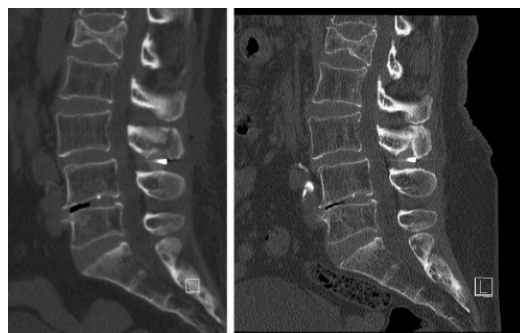


Figure 8: Sagittal CT reformatted scans of a patient affected by L3-L4 anterolisthesis. Early (a) and 6-month (b) postoperative images show fracture of the spinous process cranial to the device and subsequent good healing; no subsidence of the spacer is seen

Discussion

An overview

One of current trends in spinal surgery is the development and adoption of minimally invasive approaches and this is particularly true for lumbar posterior stabilization; in this context different techniques have been refined and percutaneous procedures have been introduced. In this scenario two effects have been occurred: widening of the spectrum of clinical indications for lumbar spine stabilization (transpedicular, interspinous, etc) and an uncontrolled potentially dangerous diffusion of lots of devices.

The choice

Why to implant an interspinous device? There are basically three main reasons. The first is to treat NIC caused by lumbar spinal stenosis, as sole treatment or following uni- or bilateral decompression; the second reason is to achieve a certain degree of stability in hypermobile lumbar spine segments, while trying to preserve intervertebral motility; as third [7], in lumbar stenosis patients the interspinous process decompression may represent 'an intermediate step in the continuum of care'.

When starting this kind of surgery, about twenty interspinous blockers were available in the Italian market (their number has now risen up to about thirty). After an experience with the Wallis device (unpublished data: good outcome in a series of more than 50 cases, blurred by a not trivial rate of wound seromas, requiring multiple tapings over several days), we decided to start implanting the BacJac spacer in those degenerative lumbar spine disorders associated with no or mild-to-moderate segmental instability. Our choice based upon the following BacJac's features: minimal invasiveness, unilateral approach preserving supraspinous ligament, self-deploying mechanism; moreover it's made of PEEK, which has an elastic modulus close to

that of bone [5] [e.g., human femur has a flexural modulus of about 20 GigaPascal (GPa), and PEEK Optima has about the same value].

Our series is the first prospective study concerning the use of an all-PEEK interspinous device in the treatment of lumbar spine degenerative disorders.

Our experience

A marked improvement in terms of lumbar and radicular pain relief and improvement of claudication was observed in 18 out of 23 (78.2%) patients affected by central (CLS) and foraminal (FLS) stenosis; our results well compare with those reported in main literature. Recently Sobottke et al. retrospectively compared the Wallis device with two different interspinous implants (DIAM[®], X-Stop[®]) in the treatment of lumbar spinal stenosis: in 18 out of 129 patients who received the Wallis implant the VAS score significantly decreased at 1-year follow-up, although this pain relief did not well correlate with the observed radiographic changes; one of the final author's statements is that these three interspinous implants did not worsen low-grade spondylolisthesis [8]. Zucherman et al. reported 'satisfaction' in the 73.1% of NIC patients treated by means of X STOP, doubling (about 36%) the rate of satisfied patients in the control group [3].

Six out of seven (85.7%) patients who received the BacJac implant for degenerative disc disease (DDD) showed a good outcome in terms of relief of both low-back and radicular pain.

Considering the subgroup of patients implanted for recurrent disc protrusion (RDP), the functional outcome was excellent in all of them; in our daily practice we visit several patients operated upon for lumbar disc herniation who develop recurring symptoms, and CT or MR scan reveal a 'crowded' pre-foraminal area, in which it may be difficult to distinguish a true recurrent disc fragment from degenerative changes narrowing the neural foramen; the above results encouraged us to go on implanting BacJac in some selected cases of RDP.

Six out of eight (75%) patients affected by mild antero- or retrolisthesis (LAL/LRL) showed good reduction of low-back pain (mean VAS score improved from 7.8 to 4.5); two patients were unchanged. Anderson et al. reported overall clinical success rate of more than 60% in patients with 'mild' spondylolisthesis treated by means of the X STOP device [10].

Those very few patients affected by lumbar synovial cysts (LSC) had excellent results in terms of pain relief and improvement of walking. This disorder is expression of malfunctioning of the lumbar articular process from which the cyst arises; so a satellite pseudospondylolisthesis, which is often diagnosed already in the preoperative course, may be worsened after surgical excision of the cyst. In this light implantation of an interspinous device contextually to cyst removal warrants a primary stabilization, strongly reducing the probability of future fixation. The BacJac system enabled us to keep the operated lumbar segment aligned, following cyst excision, very satisfactorily (Figure 9).

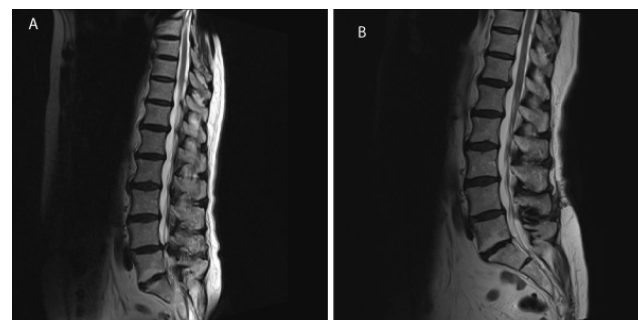


Figure 9: MR sagittal T2-weighted images of a patient affected by an L4-L5 synovial cyst. (a) preoperative scan shows the cyst and satellite pseudospondylolisthesis; (b) 2½-year postoperative scan shows no recurrence of the removed cyst and good alignment of the lumbar segment with reduction of listhesis.

Complications

The rate of spinous process fracture observed in our series (10%) could appear a little bit high; however clinical and radiological follow-up enabled us to consider such a complication as inconsequential: no increasing pain was referred by the involved patients, no additional surgeries were required, no late (at 2-year control, at least) bone erosion or segmental instability was observed. Fracture of the spinous process is a well-known complication of interspinous devices; for example, Kim et al reported 3 similar adverse events in a group of 31 patients who received DIAM implant [2]; one spinous process fracture (1%) was observed in an X-STOP series [3].

Moreover other device-related complications may occur. Floman et al reported a 16% rate of non-infected serous wound collections using an interspinous PEEK device (e.g., Wallis) [9]. Taylor et al reported 20 adverse events in a series of 104 DIAM patients; three out of these 20 cases were considered 'direct wound complications, including two pseudomeningoceles and one draining wound' [11]. It must be here stressed that in our series neurological deterioration directly correlated to the procedure, early or late dislocation of the spacer, device breakage, allergy to BacJac components, wrong level implant [12] were not encountered.

Conclusions

Although our study suffers the obvious limits to have no randomisation and no control/different implant groups, we think the BacJac interspinous spacer, as stand-alone implant or following uni- or bilateral decompression, provides mid-term relief of low-back and radicular pain, as assessed by VAS and IGEA scales, and improvement of neurogenic intermittens claudication, in the following lumbar spine disorders: central and foraminal stenosis, recurrent disc protrusion associated to foraminal stenosis, mild antero- or retrolisthesis, DDD, synovial cysts associated with pseudospondylolisthesis.

When considering these disorders, the BacJac seems to provide a primary stabilizing effect; a 2-year follow-up confirms that this effect is still active, with no need of subsequent more invasive fixation surgical procedures.

Post-study considerations

We went on to implant the BacJac device and 81 patients, in addition to the 50 ones of the present study, have been implanted until January 31, 2014; in general, patients continue to be satisfied in terms of relief of low-back and radicular pain and improvement of walking; clinical indication to BacJac implant has been maintained for most of patients affected by CLS, FLS, RDP and LSC, as patients with DDD and LAL/LRL are evaluated preoperatively for lamino-spinous arthrodesis vs BacJac spacer on a case-by-case basis.

Acknowledgements

This study was partially supported by outside funds.

References

1. S  n  gas J (2002) Mechanical supplementation by non-rigid fixation in degenerative intervertebral lumbar segments: the Wallis system. *Eur Spine J* 11 Suppl 2: S164-169.
2. Kim KA, McDonald M, Pik JH, Khoueir P, Wang MY (2007) Dynamic intraspinal spacer technology for posterior stabilization: case-control study on the safety, sagittal angulation, and pain outcome at 1-year follow-up evaluation. *Neurosurg Focus* 22: E7.
3. Zucherman JF, Hsu KY, Hartjen CA, Mehalic TF, Implicito DA, et al. (2005) A multicenter, prospective, randomized trial evaluating the X STOP interspinous process decompression system for the treatment of neurogenic intermittent claudication: two-year follow-up results. *Spine (Phila Pa 1976)* 30: 1351-1358.
4. Richter A, Sch  tz C, Hauck M, Halm H (2010) Does an interspinous device (Coflex) improve the outcome of decompressive surgery in lumbar spinal stenosis? One-year follow up of a prospective case control study of 60 patients. *Eur Spine J* 19: 283-289.
5. Giltaij L, Timothy J, Derks M (2008) BacJac interspinous decompression system: another me-too or an improvement? *Spinal Surgery News*.
6. Irace C, Corona C (2010) How to avoid wrong-level and wrong-side errors in lumbar microdiscectomy. *J Neurosurg Spine* 12: 660-665.
7. Lauryssen C (2007) Appropriate selection of patients with lumbar spinal stenosis for interspinous process decompression with the X STOP device. *Neurosurg Focus* 22: E5.
8. Sobottke R, Schl  ter-Brust K, Kaulhausen T, R  llinghoff M, Joswig B, et al. (2009) Interspinous implants (X Stop, Wallis, Diam) for the treatment of LSS: is there a correlation between radiological parameters and clinical outcome? *Eur Spine J* 18: 1494-1503.
9. Floman Y, Millgram MA, Smorgick Y, Rand N, Ashkenazi E (2007) Failure of the Wallis interspinous implant to lower the incidence of recurrent lumbar disc herniations in patients undergoing primary disc excision. *J Spinal Disord Tech* 20: 337-341.
10. Anderson PA, Tribus CB, Kitchel SH (2006) Treatment of neurogenic claudication by interspinous decompression: application of the X STOP device in patients with lumbar degenerative spondylolisthesis. *J Neurosurg Spine* 4: 463-471.
11. Taylor J, Pupin P, Delajoux S, Palmer S (2007) Device for intervertebral assisted motion: technique and initial results. *Neurosurg Focus* 22: E6.
12. Fountas KN (2013) Novel frontiers of advanced neuroimaging. InTech, Rijeka, Croatia.