

The Application of Density Spectral Array Monitoring in Digital Electroencephalography for Levetiracetam-Induced Non-Convulsive Status Epilepticus in a Patient with Lennox-Gastaut Syndrome

Kenichi Isoda^{1,2*}

¹Department of Pediatrics, Matsushita Memorial Hospital, Japan

²Department of Pediatrics, Fukuchiyama City Hospital, Japan

*Corresponding author: Kenichi Isoda, Director, Department of Pediatrics, Matsushita Memorial Hospital, Japan; Tel: +8169921231; E-mail: k-isd@koto.kpu-m.ac.jp

Received date: July 29, 2017; Accepted date: September 05, 2017; Published date: September 12, 2017

Copyright: © 2017 Isoda K. This is an open-access article distributed under the terms of the Creative Commons Attribution License, which permits unrestricted use, distribution, and reproduction in any medium, provided the original author and source are credited.

Abstract

Objective: To analyze the density spectral array (DSA) on the digital electroencephalography (EEG) in a patient with Lennox-Gastaut syndrome (LGS) who developed non-convulsive status epilepticus (NCSE) after initiation of oral levetiracetam (LEV).

Methods: Digital EEG was performed on the patient for a 30 min period during the daytime while he was asleep status without hypnotic drugs. The DSA, which incorporated a conventional program of the digital EEG, was sequentially evaluated.

Result: The DSA demonstrated that the continuous and periodic high voltages and broad ranges of oscillation, reflecting epileptic activity and the clinical conditions. The EEG demonstrated obvious bilateral frontopolar and/or diffuses 2-3 Hz slow spike-and-wave complex activities, which were not evident before initiation of LEV. Development of LEV-induced NCSE was suspected. Discontinuation of LEV and increasing the dose of clobazam resulted in recovery from NCSE, followed by gradual restoration of the original DSA and EEG findings.

Conclusion: On administering of LEV for patients with LGS, the occurrence of NCSE should be carefully monitored. The DSA based on digital EEG was useful for both the diagnosis of NCSE as a drug side-effect and the recovery from its epileptic status.

Keywords: Lennox-Gastaut syndrome; Levetiracetam; Density spectral array; Non-convulsive status epilepticus

Introduction

Lennox-Gastaut syndrome (LGS) is characterized by frequent daily refractive seizures and serious intellectual disability. Various therapeutic strategies for LGS have attempted to combine antiepileptic drug therapy and/or ketogenic diets; however, complete control of epileptic seizures improvement in patients' quality of life (QoL) have remained elusive [1]. Furthermore, more than one-half of patients with LGS experience episodes of non-convulsive status epilepticus (NCSE) episodes [1,2]. NCSE usually presents with continuous atypical absence of seizures with altered consciousness due to recurring brief tonic seizures, which lead to impaired sleep qualities. The non-convulsive status lasts hours to weeks, and it is particularly difficult to recognize its initiation and disappearance in patients with severe cognitive impairments [1,2]. Modification of several antiepileptic regimens has been reported to exacerbate seizures and trigger NCSE or status epilepticus in patients with LGS [1].

In contrast, levetiracetam (LEV) is novel anticonvulsants with diminished risks for harmful risks for drug-drug interactions because of its lack of interference with the metabolism of other drugs [3-6]. Its efficacy and tolerability with regard to improvement in patient' QoL and seizure-control in various refractory epilepsies, including LGS,

have been evaluated in several reports [5,7,8]. LEV was recently approved also in Japan as a monotherapy for focal seizure, or as adjunctive therapy for generalized tonic onset seizures in both adults and children older than 4 years of age.

We presented the case of a patient with LGS who developed NCSE after oral administration of LEV [9]. Because the number of seizures he experienced increased during titration of LEV, it was reasonable to believe the reasons were a drug-specific side effect or an inadequate dosage (i.e., insufficient to suppress epileptic activity). We assessed several sequences of a density spectral array (DSA) of digital electroencephalography (EEG) in a prototype program in the Nihon Kohden utility (Neurofax EEG-1000, Tokyo, Japan). These digital EEGs were performed over a 30 min period during the daytime under hypnagogic states in physiological conditions without hypnotic drugs.

Case Report

A nine year old boy was born to non-consanguineous, with an unremarkable family medical history. Pregnancy and delivery were uneventful. He was diagnosed with Down syndrome based on chromosomal analysis [47,XY,+21] performed because of his gestalt findings after birth. He developed West syndrome at 3 months of age. Therapeutic use of sodium valproate (VPA), vitamin B6 and thyrotropin-releasing hormone relieved his tonic spasms, and hysarrhythmia in EEG disappeared with the exception of residual

focal epileptic discharges. He had severe intellectual disabilities and attended a special-needs elementary school with family support. He developed LGS at 7 years age, which was reflected by daily tonic and drop seizures, and EEG findings in both slow spike-and-wave complexes at rest and fast rhythms while asleep. The initiation of clobazam (CLB) only transiently reduced the frequency of his seizures. Subsequently, an attempt of topiramate (TPM) treatment failed because of serious hypothermia and activity loss. Furthermore, lamotrigine (LTG) was prescribed according to guidelines for concomitant VPA usage. Despite achievement to apparent reduction of his seizures, the dosage of LTG did not reach adequate levels because of his somnolence with day-night reversal behavior and serious appetite loss. The frequency of epileptic seizures gradually increased, and his parents requested LEV to treat his epilepsy and improve QoL. Informed written consent was obtained after sufficient explanation of an off-label use in Japan, given the situation and 125 mg/day (4.6 mg/kg/day) of LEV was prescribed more than 6 months after a stable state of blood concentration of other concomitant drugs was achieved. Combined medications at LEV initiation were VPA (700 mg/day), zonisamide (ZNS, 200 mg/day), CLB (6 mg/day) and LTG (10 mg/day). The original DSA in digital EEG revealed short, intermittent bursts of various ranges of wave frequency in 30 min recordings under his sleep conditions before LEV initiation (Figure 1a).

Following 2 weeks of LEV administration at 125 mg/day, the dose was increased to 250 mg/day. No tonic seizures occurred in the first 2 weeks; however, 1-4 tonic seizures occurred daily during the following 2 week observation interval. The dose of LEV was increased to 500 mg/day (18 mg/kg/day); however, the patient then developed drowsiness and gait disturbance during the 2 week follow-up. Frequent tonic seizures gradually came to disturb his sleep. The following week, LEV dose was increased up to 750 mg/day, but his condition was confirmed to be worse. The DSA of C3-4 in digital EEG demonstrated continuous high voltage resulting from epileptic discharges while being both asleep and awake (Figures 1b and 2c). EEG revealed almost continuous 2-3 Hz slow spike-and-wave activities in the frontopolar and/or diffuse channels (Figures 2a and 2b), which confirmed the diagnosis of NCSE [8].

LEV was discontinued during hospitalization. Laboratory data revealed no abnormalities. Blood levels of concomitant antiepileptics were unchanged (VPA, 108 µg/mL; ZNS, 18.8 µg/mL; CLB, 57 ng/mL; desmethyl-CLB, 1921 ng/mL; LTG, 0.98 µg/mL) in compared with those before initiation of LEV. Brain magnetic resonance imaging yielded no findings.

His parents refused a therapeutic course of intravenous anticonvulsants in order to relieve his NCSE, because they feared further deterioration of significant somnolence by intravenous treatment. Under their informed consents, a suppository of diazepam both as a seizure controller and as a sleep-aid at night, reduced the frequency of his tonic seizures was released to twice daily and improved his activities. Thus, dose of CLB, which is an alternative type of benzodiazepine, was increased up to 8 mg/day. Until 2-3 weeks after cessation of LEV, the patient recovered to maintain a sitting posture and showed an increase in conversational ability. Three weeks after LEV cessation, he was discharged on foot without supports.

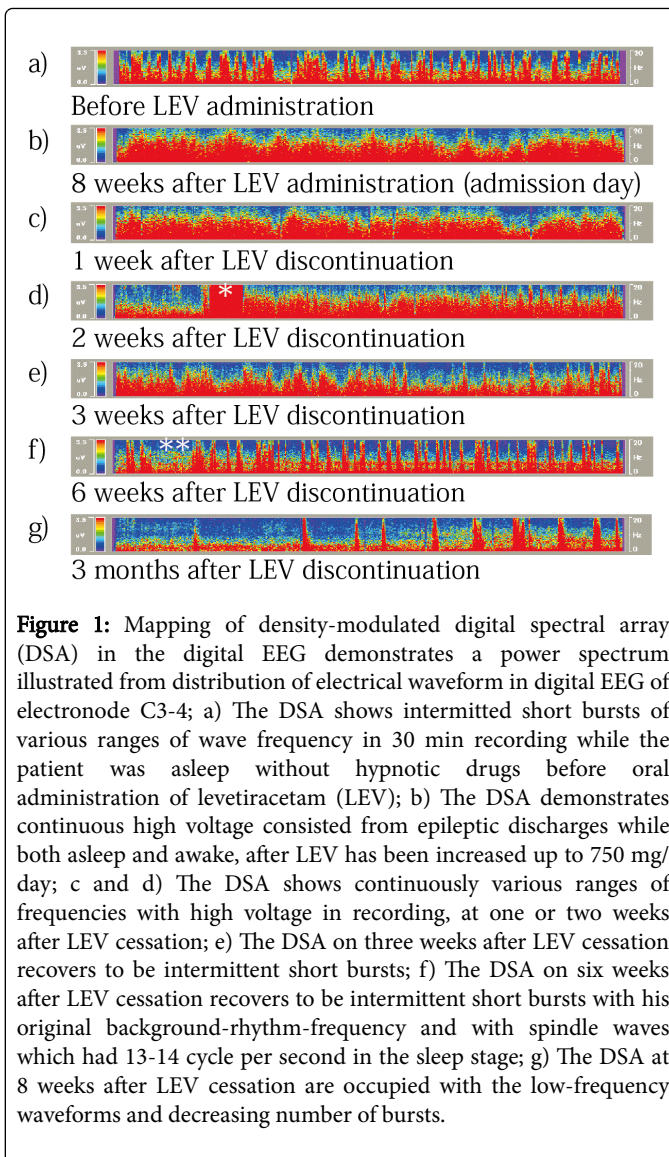


Figure 1: Mapping of density-modulated digital spectral array (DSA) in the digital EEG demonstrates a power spectrum illustrated from distribution of electrical waveform in digital EEG of electrode C3-4; a) The DSA shows intermittent short bursts of various ranges of wave frequency in 30 min recording while the patient was asleep without hypnotic drugs before oral administration of levetiracetam (LEV); b) The DSA demonstrates continuous high voltage consisted from epileptic discharges while both asleep and awake, after LEV has been increased up to 750 mg/day; c and d) The DSA shows continuously various ranges of frequencies with high voltage in recording, at one or two weeks after LEV cessation; e) The DSA on three weeks after LEV cessation recovers to be intermittent short bursts; f) The DSA on six weeks after LEV cessation recovers to be intermittent short bursts with his original background-rhythm-frequency and with spindle waves which had 13-14 cycle per second in the sleep stage; g) The DSA at 8 weeks after LEV cessation are occupied with the low-frequency waveforms and decreasing number of bursts.

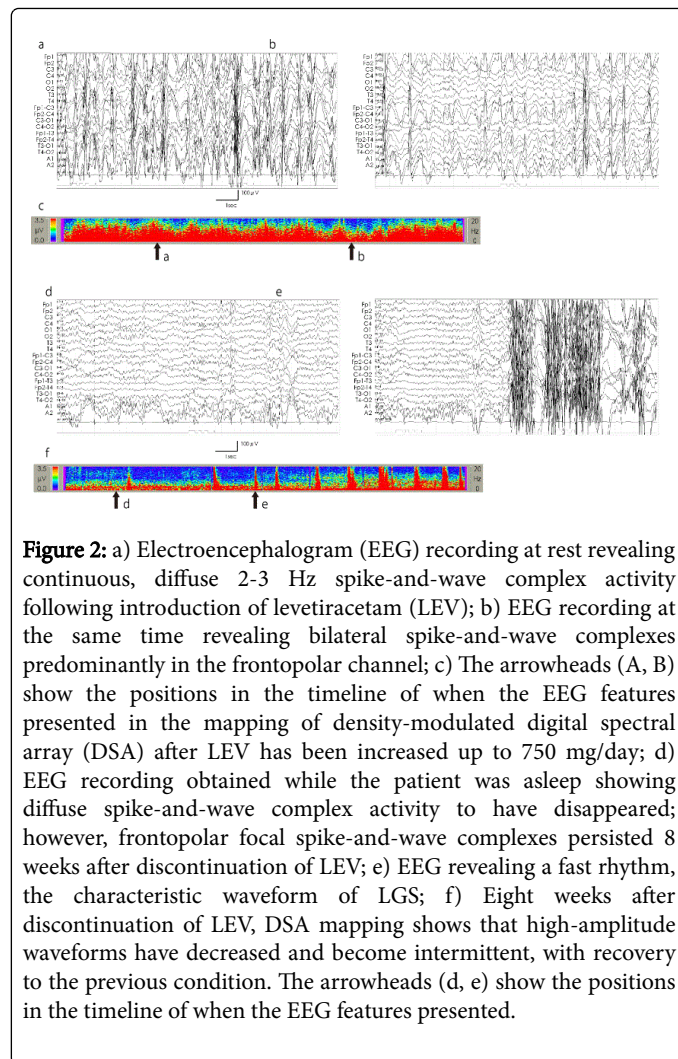


Figure 2: a) Electroencephalogram (EEG) recording at rest revealing continuous, diffuse 2-3 Hz spike-and-wave complex activity following introduction of levetiracetam (LEV); b) EEG recording at the same time revealing bilateral spike-and-wave complexes predominantly in the frontopolar channel; c) The arrowheads (A, B) show the positions in the timeline of when the EEG features presented in the mapping of density-modulated digital spectral array (DSA) after LEV has been increased up to 750 mg/day; d) EEG recording obtained while the patient was asleep showing diffuse spike-and-wave complex activity to have disappeared; however, frontopolar focal spike-and-wave complexes persisted 8 weeks after discontinuation of LEV; e) EEG revealing a fast rhythm, the characteristic waveform of LGS; f) Eight weeks after discontinuation of LEV, DSA mapping shows that high-amplitude waveforms have decreased and become intermittent, with recovery to the previous condition. The arrowheads (d, e) show the positions in the timeline of when the EEG features presented.

Discussion

This was the first episode of drug-induced NCSE recognized by the EEG monitoring during the patient's life. Because he had a history of adverse events from TPM and LTG, LEV was carefully initiated at a dose of 4.6 mg/kg/day, which is below the standard regimen of starting at 10 mg/kg in two divided doses, which would achieve plasma concentrations of LEV similar to those in adults on the recommended 500 mg twice daily dose [7,10]. A favorable effect in seizure frequency was temporarily observed during the initial weeks of LEV titration; however LEV was not tolerable due to the development of NCSE and resulting impairment of his QoL. To our knowledge, there are no previous reports to describing safer methods of LEV titration in patients with similarly severe epilepsy.

The DSA illustrates a power spectrum from the distribution of electrical waveforms in digital EEG. The most significant advantage of DSA is its ability to configure and to summarize a compact picture by color mapping an overall time-course of digital EEG data. The DSA aspect is not specific of NCSE, and then the diagnosis on NCSE needs to confirm with simultaneous analysis of the EEG in the recording timeline, for example to exclude misleading aspects of DSA from artifact signals like movements, chewing, or problems with the

electrode resistance. DSA in digital EEG is, however, an appropriate tool to mitigate the difficulty in diagnosing NCSE with supportive evidence for seizures reflected by changes in the predominant waveform.

LEV-induced NCSE did not occur because of increased blood levels of concomitant drugs. Increasing the dose of CLB dose was effective for seizure control and NCSE cessation, although benzodiazepines have been reported to occasionally aggravate tonic seizures [1,10]. The major side effects of LEV have been reported to be mostly mild and transient in nature, and include irritability, aggression and somnolence [3-6,10]. Recently, however, some patients with refractory childhood epilepsy (e.g. LGS), had to discontinue LEV, because of serious side effects such as worsening seizures [3,4,10-12]. Nakken et al. [10] reported LEV-induced seizure worsening at doses >30 mg/kg/day occurring after 5 to 7 months of administration among studies involving 78 adults and 44 children with intractable epilepsy. The patient pool included the development of status epilepticus in three adults and four children, and NCSE in two adults and two children. Atefy et al. [12] also reported two adult patients with symptomatic epilepsy who developed NCSE on treatment with LEV, and who had never previously experienced status epilepticus before. In this case, it was noted LEV was prescribed more than 6 months after a stable state of blood concentration of other concomitant drugs was achieved and the patient haven't changed into behavior accompanied with continuous DSA and/or EEG abnormality. And then, LEV administration supposed to trigger the strong cue. But unfortunately it could not perfectly deny the natural course of worsening conditions because of uncertain onset.

In terms of seizure control and improved QoL in LGS patients, LEV is regarded to be an adjunctive antiepileptic option. However, LGS patients undergoing LEV therapy should be monitored for the emergence of NCSE.

Conflict of Interest

The authors have no conflicts of interest to declare.

References

1. Arzimanoglou A, French J, Blume WT (2009) Lennox-Gastaut syndrome: A consensus approach on diagnosis, assessment, management and trial methodology. *Lancet Neurol* 8: 82-93.
2. Korff CM, Nordli DR, Jr. (2007) Diagnosis and management of non-convulsive status epilepticus in children. *Nat Clin Pract Neurol* 3: 505-516.
3. De Los Reyes EC, Sharp GB, Williams JP, Hale SE (2004) Levetiracetam in the treatment of Lennox-Gastaut syndrome. *Pediatr Neurol* 30: 254-256.
4. Grosso S, Franzoni E, Coppola G (2005) Efficacy and safety of levetiracetam: An add-on trial in children with refractory epilepsy. *Seizure* 14: 248-253.
5. Chhun S, Troude P, Villeneuve N (2011) A prospective open-labeled trial with levetiracetam in pediatric epilepsy syndromes: Continuous spikes and waves during sleep is definitely a target. *Seizure* 20: 320-325.
6. Negrillo AD, Valle FMD, Salices MG, Jurczynska CJ, Ruiz JC (2011) Levetiracetam efficacy in patients with Lennox-Gastaut syndrome. Presentation of a case. *Neurologia* 26: 285-290.
7. Chhun S, Jullien V, Rey E, Dulac O, Chiron C, et al. (2009) Population pharmacokinetics of levetiracetam and dosing recommendation in children with epilepsy. *Epilepsia* 50: 1150-1157.
8. Kim HJ, Kim SH, Kang HC, Lee JS, Chung HJ (2014) Adjunctive levetiracetam treatment in pediatric Lennox-Gastaut syndrome. *Pediatr Neurol* 51: 527-531.

-
9. Isoda K, Tomoyasu C, Fujii N, Nishimura A (2012) Levetiracetam-induced aggravation to non-convulsive status epilepticus in a boy with Lennox-Gastaut syndrome. *Brain Dev* 44: 401-402.
 10. Nakken KO, Eriksson AS, Lossius R, Johannessen SI (2003) A paradoxical effect of levetiracetam may be seen in both children and adults with refractory epilepsy. *Seizure* 12: 42-46.
 11. Yang Z, Liu X, Qin J, Zhang Y, Bao X, et al. (2008) Partial seizures and atypical absence seizures as a single ictal event in a patient with Lennox-Gastaut syndrome. *J Child Neurol* 23: 1319-1323.
 12. Atefy R, Tettenborn B (2005) Non-convulsive status epilepticus on treatment with levetiracetam. *Epilepsy Behav* 6: 613-616.