

## Survey of Traumatic Glaucoma in a Tertiary Hospital

Kayode Olumide Ajite\*, Funmilayo Christianah Fadamiro, Iyiade Adeseye Ajayi, Omotoye Olusola Joseph and Emmanuel Chiwendu Abah

Department of Ophthalmology, Ekiti State University Teaching Hospital, Ado Ekiti, Ekiti State, Nigeria

\*Corresponding author: Kayode Olumide Ajite, Department of Ophthalmology, Ekiti State University Teaching Hospital, Ado Ekiti, Ekiti State, Nigeria, Tel: +07003682265; E-mail: bidemi\_kayode@yahoo.com

Rec date: Jan 30, 2017; Acc date: Mar 16, 2017; Pub date: Mar 18, 2017

Copyright: © 2017 Ajite KO, et al. This is an open-access article distributed under the terms of the creative commons attribution license, which permits unrestricted use, distribution, and reproduction in any medium, provided the original author and source are credited.

### Abstract

**Background:** Traumatic eye injury is one of the most common causes of unilateral blindness worldwide and it remains a core root of avoidable blindness worldwide. Traumatic glaucoma can result in severe visual impairment. Recognition of factors related to poor visual outcome, appropriate medical therapy, surgical intervention when indicated and careful follow up will help in preserving vision in these patients. This study is aimed at determining the frequency, clinical forms and types of therapy of traumatic glaucomas as seen in our hospital.

**Methods:** All consecutive patients with ocular injury who received treatment at the eye clinic of Ekiti state university teaching hospital, Ado Ekiti, from January 2012 to December 2014 were selected for the study. All subjects had thorough ophthalmic examinations. The patients with ocular injury and subsequently developed glaucoma were selected extracting from the medical records the demographic data, visual acuity at presentation, clinical form of glaucoma and various therapies for management. The data were analysed using SPSS version 18 (Illinois, Chicago, USA) and presented as tables, and figures, in frequencies, percentage.

**Result:** A total of 5568 patients were seen during this study at the ophthalmology clinic, 365 of them had ocular trauma out of which 31(8.5%) was traumatic glaucoma. Peripheral anterior synerchae (29%), adherent leucoma (16.1%) and Hyphema (16.1%) were the common clinical manifestations (anatomic changes) of traumatic glaucoma. The clinical types of traumatic glaucoma are secondary open angle glaucoma (54.8%) which is higher than the secondary closed angle type (45.2%). 22 (71%) of these patients had medical interventions with antiglaucoma drugs.

**Conclusion:** The prevalence of traumatic glaucoma is 8.5%, this glaucoma may result in severe visual impairment if treatment is not instituted early.

**Keywords:** Traumatic glaucoma; Visual impairment; Early treatment

### Introduction

Traumatic eye injury is one of the most common causes of unilateral blindness worldwide and it remains a core root of avoidable blindness worldwide [1]. It can occur as closed globe injury or open globe injury. Traumatic glaucoma can occur soon after the injury or many years later. Traumatic glaucoma refers to a heterogeneous group of post-traumatic ocular disorders with different underlying mechanisms that lead to the common pathway of abnormal elevation of intraocular pressure (IOP) and increased risk of optic neuropathy [2]. It is a secondary glaucoma and it indicates the severity of the eye injury. It appears in 5% to 10% of the injured eyes [3]. When traumatic eye injury occurs, glaucomatous optic nerve damage may complicate it either early or late. Recognition of factors related to poor visual outcome, appropriate medical therapy, surgical intervention when indicated and careful follow up will help in preserving vision in these patients. Furthermore, a high index of suspicion will be needed to help in the accurate diagnosis and management of this potentially blinding disease. Blunt eye injury is commoner in unilateral cases and traumatic glaucoma in unilateral occurrence can be seen in any type such as angle recession glaucoma, phacolytic glaucoma, red cell glaucoma and hyphema [4]. Hyphema and concomitant injuries to ocular structures following blunt trauma are not an infrequent cause of presentation to

the emergency unit in many hospitals [4,5]. Blood and cells from the injury can block the trabecular meshwork, damaging the trabecular meshwork and resulting trabeculitis. These can cause increased intraocular pressure which eventually leads to glaucomatous optic nerve damage. Glaucoma may appear in different clinical forms and in different periods after eye injury. The causes of poor vision after blunt injury include black ball hyphema, secondary glaucoma, cataract, vitreous haemorrhage, commotio retinae and retinal detachment [6].

Angle-recession glaucoma is classified as a type of traumatic secondary open-angle glaucoma [7]. It may be underdiagnosed due to the fact that onset is often delayed and because a history of eye injury might have been forgotten. It is a common sequela of blunt ocular trauma and one characterized by a variable degree of cleavage between the circular and the longitudinal fibers of the ciliary muscle [7,8].

This study is aimed at determining the frequency, clinical forms and types of therapy of traumatic glaucomas as seen in our hospital.

### Background Information on Study Location

The Ekiti state teaching hospital is a semi urban tertiary hospital centrally located in a capital city. The rural and the city dwellers have equal and unfettered access to the ophthalmologist/glaucoma specialist who runs the clinic twice a week. This is at no additional cost following the consultation fee paid at the General out-patient department prior

to referral to the comprehensive ophthalmologist who sorts out the patients and refers appropriately. The implication of this is that all the patients that were needed to be seen for the purpose of this study were seen without any bias.

## Methods

All consecutive patients with ocular injury who received treatment at the eye clinic of Ekiti state university teaching hospital, Ado Ekiti, from January 2012 to December 2014 were selected for the study. Approval for the study was obtained from the institution ethics and review board. All the patients had thorough ocular examinations; Visual acuity assessment with Snellen's chart, slit lamp biomicroscope assessment of the anterior segment, intraocular pressure measured with Goldman applanation tonometer, optic disc stereoscopic evaluation with +78D lens, gonioscopy (with 4 mirror gonioscopes), perimetry (except in patients with open globe injury in which it was technically difficult to carry out these procedures). Patients who are on antiglaucoma drugs predating the ocular injury, or who had trabeculectomy before the injury were excluded from the study.

The patients with ocular injury and subsequently developed glaucoma were selected extracting from the medical records the demographic data, visual acuity at presentation, clinical form of glaucoma and various therapies for management.

The data were analyzed using SPSS version 18 (Illinois, Chicago, USA) and presented as tables, and figures, in frequencies, percentage and measure of association at  $p < 0.05$ .

## Results

A total of 5568 patients were seen during the duration of this study at the ophthalmology clinic, 365 of them had ocular trauma out of which 31(8.5%) was traumatic glaucoma. The age range was 10 to 79 years (median 45 years  $\pm$  3 years). There was a male preponderance in the age range of 20 to 29 years. Male to female ratio was 2:1. Table 1 showed that 12 (38.7%) of the subjects with traumatic glaucoma were in the 20 to 29 years age group. Majority of the traumatic eye injury were closed globe (Table 2).

Twenty one (67.7%) of traumatic glaucoma had Low Vision (moderate and severe visual impairment) at presentation, while 4(12.9%) were blind out of which one (1) was No light perception (NLP) Table 3. In Figure 1, peripheral anterior synerchae (29%), adherent leucoma (16.1%) and Hyphema (16.1%) were the common clinical manifestations (anatomic changes) of traumatic glaucoma. Traumatic glaucoma being a secondary glaucoma had the clinical type of open angle glaucoma occurring 54.8% which is higher than the closed angle type (45.2%) as shown in Figure 2.

Table 4 showed that 22(71%) of the patient with traumatic glaucoma had medical treatment only while 9(29%) had surgery offered to them as treatment.

Age Range in Years	Male (%)	Female (%)	Frequency (%)
10-19	1(3.2)	1(3.2)	2 (6.5)
20-29	8 (25.8)	4 (12.9)	12(38.7)
30-39	4 (12.9)	1 (3.2)	5(16.1)
40-49	3(9.7)	2(6.5)	5 (16.1)

50-59	3 (9.7)	1(3.2)	4 (12.9)
60-69	1(3.2)	1(3.2)	2 (6.5)
70-79	1(3.2)	0(0.0)	1(3.2)
Total	21(67.7)	10(32.3)	31(100)

**Table 1:** Age and gender distribution of patient with traumatic glaucoma.

Types of trauma	Number of Trauma	Number of traumatic glaucoma	Percentage of traumatic glaucoma (%)
Open globe injury	58	6	10.3
Closed globe injury	307	25	8.4
Total	365	31	8.5

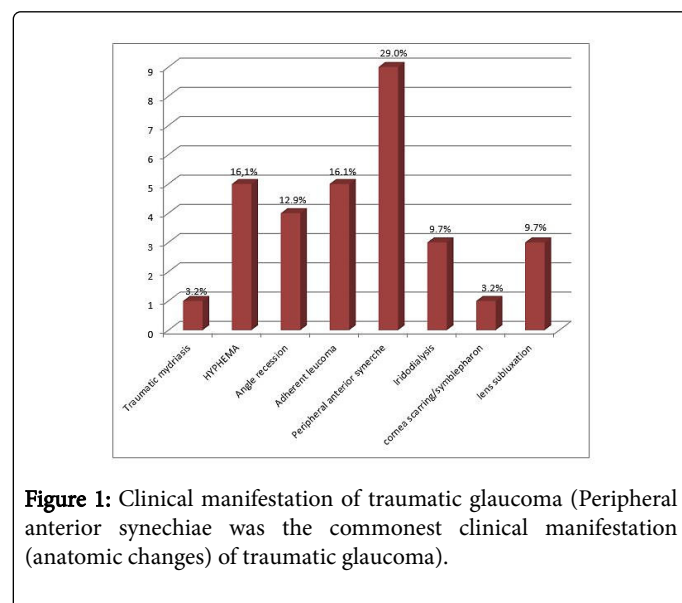
Majority of the injury were closed globe injury 84.1%. The frequency of traumatic glaucoma is 8.5%

**Table 2:** Types of Trauma.

Visual acuity at presentation	Category of vision	Frequency N (%)
6/4-6/18	Normal vision	6(19.4)
6/24-6/36	Moderate visual impairment	9(29.0)
6/60-3/60	Severe visual impairment	12(38.7)
>3/60-NPL	Blindness	4(12.9)
Total		31(100)

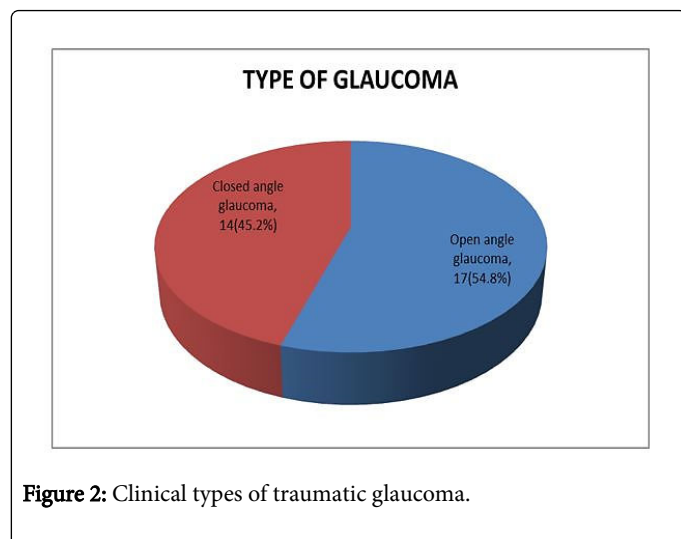
21 (67.7%) of the patients presented with low vision.

**Table 3:** Visual acuity at presentation.



Clinical type of traumatic glaucoma	Medical	Surgical
Open angle glaucoma	11	6
Closed angle glaucoma	11	3
Total	22(71%)	9(29%)

**Table 4:** Treatment offered for traumatic glaucoma.



**Figure 2:** Clinical types of traumatic glaucoma.

## Discussion

Traumatic glaucomas represent a very heterogeneous group of entities due to a variety of pathomechanisms which increase the intraocular pressure in the early or late phase after traumatic injury (blunt or penetrating injury, acid or alkali burn) [9]. Ocular trauma is a major cause of preventable monocular blindness and visual impairment in the world [10]. The visual impairment caused by ocular trauma may arise from traumatic glaucoma. In this study, the frequency of traumatic glaucoma was 8.5% which is slightly higher than value reported by Stanic et al. [3]. This showed that contribution of traumatic glaucoma to the global burden of glaucoma blindness particularly in sub-Saharan Africa is increasing.

The male gender is usually associated with high physical, outdoor activities and so may be prone to injuries and various ocular injuries particularly. This may explain the male preponderance seen in this study in the age range of 20 to 29 years. Majority of the ocular injuries resulting in traumatic glaucoma in our study were basically closed globe injuries. This is similar to findings in study conducted by Sujatha et al. Proper health education in prevention of ocular injury should focus on this age group of masculine gender during routine “Health talks” in schools public places and eye clinics.

Twenty one (67.7%) of traumatic glaucoma had low vision at presentation, while 4(12.9%) were blind out of which one was no light perception (NLP).

In this study, peripheral anterior synechiae, adherent leucoma and hyphema were the common clinical manifestations (anatomic changes) of traumatic glaucoma. This is similar to what was reported by other authors [2,3,9].

Clinical findings of secondary glaucoma associated with ocular trauma may remain complex; however a good history taking and thorough ocular examination will afford the clinician an opportunity to institute early treatment for traumatic glaucoma. In our study, secondary angle closure due to peripheral anterior synechiae is a common pathomechanism leading to glaucoma in patients with penetrating eye injury while on the other hand; it is secondary open angle due to hyphema in patients with closed globe injury. Traumatic glaucoma occurs more frequently as secondary open angle clinical type and in closed globe injury which is similar to what was reported in Croatia [3], Germany [9] and India [11].

The onset of early treatment intervention for traumatic glaucoma is aimed at lowering the intraocular pressure which when elevated post trauma may contribute to the development of visual impairment [12,13]. In this study, majority of the subjects, 71% were offered medical antiglaucoma anti-inflammatory treatment while less than one third had surgical intervention.

In a study by Bai et al. [2], it was concluded that for traumatic secondary glaucoma, antiglaucoma medication should be used at the early stage, and surgery should be carried out when medical treatment does not reduce the elevated IOP, or in difficult cases to avoid severe complications.

## Conclusion

The prevalence of traumatic glaucoma is 8.5%, this glaucoma may result in severe visual impairment if treatment is not instituted early. Traumatic glaucoma presents one of the most difficult complications of eye injuries. Secondary open angle glaucoma was the most common clinical type of traumatic glaucoma seen in our study. Both medical and surgical treatment can be offered to these patients in order to prevent visual complications.

## References

- Osman EA (2015) Glaucoma after open globe injury. Saudi J Ophthalmol 29: 222-224.
- Bai HQ, Yao L, Wang DB, Jin R, Wang YX (2009) Causes and treatments of traumatic secondary glaucoma. Eur J Ophthalmol 19: 201-206.
- Stanic R, Stanic R (2001) Traumatic glaucoma. Coll Antropol 25: 101-104.
- Ulagantheran V, Ahmad Fauzi MS, Reddy SC (2010) Hyphema due to blunt injury: A review of 118 patients. Int J Ophthalmol 3: 272-276.
- Jan S, Khan S, Mohammad (2003) Hyphema due to blunt trauma. J Coll Physicians Surg Pak 13: 398-401.
- Ashaye AO (2008) Traumatic hyphema: A report of 472 cases. BMC Ophthalmol 8: 24.
- Shields MB (1998) Glaucomas associated with ocular trauma. Textbook of glaucoma (4th edn) Baltimore: Lippincott Williams & Williams 339-344.
- Wolff SM, Zimmerman LE (1962) Chronic secondary glaucoma: Association with retrodisplacement of iris root and deepening of the anterior chamber angle secondary to contusion. Am J Ophthalmol 84: 547-563.
- Schlote T, Rohrbach M (2005) Traumatic glaucoma: A survey. Klin Monbl Augenheilkd 222: 772-782.
- McCarty CA, Fu CL, Taylor HR (1999) Epidemiology of ocular trauma in Australia. Ophthalmology 106: 1847-1852.
- Sujatha MA, Nazlin A, Prakash S, Nousheen S (2015) Prevalence of visual impairment after blunt ocular trauma in a tertiary hospital. Int J Sci Stud 3: 36-39.

12. Sihota R, Sood NN, Agarwal HC (1995) Traumatic glaucoma. *Acta Ophthalmol Scand* 73: 252-254.
13. Girkin CA, McGwin G Jr, Long C, Morris R, Kuhn F (2005) Glaucoma after ocular contusion: A cohort study of the United States Eye Injury Registry. *J Glaucoma* 14: 470-473.