

Surgical Treatment in High Grade Gliomas Trends

María Teresa Solomón Cardona^{1*}, Ernesto Ardisana Santana² and Eylen Cabrera Guillot³

¹Servicio de Neurocirugía, Centro Internacional de Restauración Neurológica (CIREN), La Habana, Cuba

²Servicio de Neurocirugía, Hospital Clínico Quirúrgico "Hermanos Ameijeiras", La Habana, Cuba

³Servicio de Neurología, Instituto de Neurología y Neurocirugía, La Habana, Cuba

Abstract

Objective: To assess the controversies about the surgical treatment of high malignancy degree lobar gliomas in adults.

Acquisition of evidences: They used the published research in PubMed and Scielo search engines in the last 5 years (2013-2018). Those documents containing contradictory information were taken into account.

Results: Multimodal treatment is the alternative that has shown the best results in the survival of patients with high malignancy grade gliomas. In most patients, surgery is the most important procedure in the treatment. There are three controversies regarding the surgical behavior of high malignancy degree gliomas: craniotomy versus a single trephine; assessment of the degree of tumor resection, and surgery versus observational medical treatment. A maximum tumor resection should be indicated, with no neurological defects addition. The use of new technologies is recommended to achieve wide and safe resections. The biopsy is indicated in well selected patients and tumors.

Conclusions: Multimodal treatment is the general guideline for patients with high malignancy grade gliomas. However, in the molecular era, personalized treatment is necessary.

Keywords: High grade gliomas; Oncological neurosurgery; Multimodal treatment

Introduction

Cancer is a great challenge for medical sciences. The fight against this disease is a priority for the World Health Organization (WHO) since 2005 [1,2]. The annual international incidence for primary tumors of the central nervous system (CNS) and spinal cord varies according to the sources and the series. As an average, it is between 4.2 and 12.8 cases per 100 000 inhabitants [3]. Only in the USA, 119 674 malignant brain or spinal cord primary tumors were diagnosed in the period from 2010 to 2014, which represented an annual incidence between 7.1 and 7.4 per 100 000 inhabitants. In the year 2017, it was published that of 23800 new cases of malignant brain tumors and others of the CNS diagnosed, 16700 died of this cause. The mortality rate of the malignant primary brain tumors is close to the incidence rate, circumstance that highlights the great aggressiveness of those tumors. They represent 2% of cancer deaths [1-5].

In Cuba, more than three decades ago, malignant tumors constitute the second cause of death only preceded by cardiovascular diseases [6]. Specifically, brain cancer in recent years has had an incidence ranging between 300 and 600 cases per year, with a total of 548 in 2012 and 616 in 2016, for an adjusted rate between 3.1 and 5.8 per 100 000 inhabitants, for women and men, respectively. Mortality rates remain close to the incidence rate [7].

Histologically, the primary tumors that come from glial cells are called gliomas and account for about one third of the tumors of the CNS and spinal cord [5]. Anaplastic astrocytoma (AA), which is classified as grade III, and glioblastoma multiforme (GBM), which is classified as grade IV, are those with the highest degree of malignancy, that's why they are called "high-grade gliomas" (HGG) [3]. They constitute 60% of gliomas and 25% of all primary tumors of the CNS [3].

Despite advances in neurosurgery, radiotherapy and chemotherapy, progress in the therapeutic results of patients with GAG is insufficient [1]. It is estimated that in more than 95% of the cases, after the first line treatment, a recurrence will occur in the area adjacent to the tumor resection [8].

Currently, the first line treatment used for HGGs is surgery, as treatment cornerstone, followed by radiotherapy (RT) and chemotherapy [8]. In Cuba, the treatment protocol in force at the National Institute of Oncology and Radiobiology (INOR) proposes a maximum dose of 60 Gy of RT with Cobalt 60, in a period of six weeks, as adjuvant treatment to surgery, for adult patients [9]. Then, immunotherapy is indicated with the monoclonal antibody nimotuzumab, which manages to extend overall survival and progression-free survival, with a high degree of safety for the patient [10]. However, median survival (SVm) history for these HGG patients who receive all therapeutic modalities is low: For cases with GBM of 9 to 12 months, with a survival rate (SV) estimated at five years, it is 5% [11-14].

Taking into account the most frequent locations of this type of tumors in adults, neurosurgeons agree to perform only a biopsy in patients with parathalamic gliomas, unless they debuted with a severe case of intracranial hypertension, when a decompressive craniotomy is imposed. In the case of brainstem gliomas, many times only magnetic resonance imaging and, exceptionally, biopsies are used for diagnosis. As for the gliomas of the lobes, there are a series of prognostic factors related to the patient, the tumor and response to treatment. Among them, the degree of tumor resection is considered the predictive factor of greater relevance in survival, although there are controversies in relation to this statement. The aim of our research was to assess the controversies that exist in relation to surgical treatment in adults with gliomas with a high degree of malignancy.

***Corresponding authors:** María Teresa Solomón Cardona, Servicio de Neurocirugía, Centro Internacional de Restauración Neurológica (CIREN), La Habana, Cuba, Tel: +53 5 254 69 45; E-mail: maisol@neuro.ciren.cu

Received February 07, 2019; **Accepted** April 12, 2019; **Published** April 19, 2019

Citation: Cardona MTS, Santana EA, Guillot EC (2019) Surgical Treatment in High Grade Gliomas Trends. Int J Neurorehabilitation 6: 345. doi: [10.4172/2376-0281.1000345](https://doi.org/10.4172/2376-0281.1000345)

Copyright: © 2019 Cardona MTS, et al. This is an open-access article distributed under the terms of the Creative Commons Attribution License, which permits unrestricted use, distribution, and reproduction in any medium, provided the original author and source are credited.

Search Strategy and Selection Criteria

The search of journal articles and books in the databases was carried out: PubMed, Scielo and EBSCO. The key words used were: high grade glioma, glioblastoma multiforme and anaplastic astrocytoma. The logical operators AND and OR were used. They were combined with the term “surgery”.

The search was limited to adults, articles with the full text, published mainly in the last five years (2013 to 2018), in Spanish or English languages. Data publications that included adult patients operated on for high-grade gliomas and who debated post-surgical outcomes were reviewed. The selected data could have the result of the surgery either as a primary objective or as a secondary objective. We reviewed the Cochrane meta-analyses, which included surgical results, and the reports of technologies in the transoperative use for gliomas

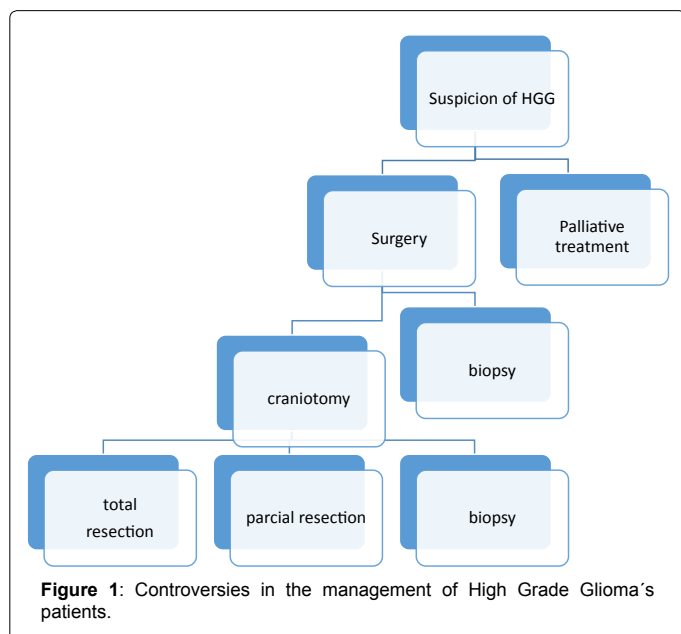
Discussion

We know that the gold standard procedure in the multimodal approach of the treatment of HGG, is neurosurgery. We found three controversies about this topic (Figure 1). First of all: what's the procedure to select for the patients: craniotomy or biopsy?

Craniotomy or only trepano/biopsy

The decision to make a surgery is complex. Is important to consider some elements, for example: age, neurological and physical patient status, tumor relation to the eloquent areas of the brain and the possibility of tumor resection (localization and size). It's important to consider the feasibility (resources), too [15]. In addition, other factors encouraging good postoperative results have been pointed out, such as the low score on the ASA scale (scale of the Association of American Anesthesiologists to measure the anesthetic risk) and the size of the tumor (less than 3 cm) [15-18].

The first controversy is about to carry on a craniotomy or only a hole for a biopsy. The first controversy revolves around the realization of a craniotomy or a hole and biopsy in front of an extensive supratentorial lesion, either hemispheric or of the basal gray nuclei. Next, the different



results proposed by the authors are presented, with the benefits and limitations of each of the techniques.

In favor of craniotomies: In favor of craniotomies there are some randomized CT and metaanalysis. Also, there are some studies where the first goal is not to demonstrate that, but there are large data that support this idea (Table 1).

The surgery of the intraxial tumors has, among its objectives, cytoreduction, establish the histopathological diagnosis, improve the quality of life with the elimination or reduction of the symptoms, and favor the action of the adjuvant treatments. The therapeutic advantages that are offered to patients, who present imaging signs of mass-effect lesions when performing surgical debulking, are undoubted. In general, there is consensus that reducing tumor burden helps and that surgical resection of newly diagnosed HGGs, is the essential first step in treatment [10,19,20]. However, most trials covering the impact of surgical resection on biopsy are retrospective and of small populations.

A single randomized controlled clinical trial (RCT) was identified, published by Vourinen et al. in 2003, [21] referred and commented on a 2014 review, [22] where surgical resection against biopsy is reaffirmed, but with a small sample of those older than 65 years (biopsy N=13, resection N=10).

A Cochrane's review was developed in 2011 [23,24]. This review focused on the discussion of the benefit of the degree of tumor resection versus the performance of only a hole. It was concluded that most of the investigations carried out reports benefits in the surgical resection. In the other hand, these authors defined that this statement has to be interpreted with caution, since most of the studies were not designed to respond to this controversy, they were weak, of limited scope and with methodological problems.

Another meta-analysis was performed by Tsitlakidis et al. [25] Almenawer et al. in 2015 also obtained similar results [26].

We report two randomized prospective trials published. These CT

Author (year)	Number of cases	Results
Random CT (Primary object)		
Vourinen (2003)	23	171 vs. 85 days
Meta analysis		
Tsitlakidis (2010)	5 CT (1111 cases)	Resection > biopsy
Cochrane (2011)	21 CT (+1000 cases)	Resection > biopsy
Randomized CT (Not primary object)		
BTSG, 1978 (BCNU)	225	Resection > biopsy
Stupp, 2005 (TMZ)	573	Resection+RT+TMZ p< 0.05 Biopsy+RT+TMZ p=0.088
Solomon, 2015 (nimo)	70	Total Resection + RT + nimotuzumab: 16.8m Biopsy + RT + nimotuzumab: 14.2m
Not randomized CT		
RTOG (2005)		49 vs. 18 months
Laws (2003)	413	45 vs. 21 months
Chaichana (2014)	103	417 vs. 138 days
Solomon (2002)	94	SV 24m: 20.7 vs. 8.3 %

Table 1: Investigations focused on the survival of HGG, which defend wide tumor resections.

do not have as primary objective the evaluation of the benefit of the degree of tumor resection:

- Trial to evaluate the efficacy of chemotherapy with BCNU (commercial name of Carmustine) adjuvant to surgery: 303 patients (90% GBM) [27]. In a subsequent analysis, it was revealed that the patients who received a biopsy (N=12) had a significantly shorter survival time than those who received a resection (N=213) (p=0.01) [28,29].
- Study to evaluate the efficacy of chemotherapy with temozolamide+RT adjuvant to surgery: 573 patients (93% GBM) [11]. In a later analysis, it was found that the effect of temozolamide+RT was significantly greater for the group of patients underwent resection (p<0.0001), than for the ones who performed the biopsy (p=0.084) [11,30,31].
- Study to evaluate the efficacy of nimotuzumab therapy+RT: 70 patients with HHG [14]. Total Resection+RT+nimotuzumab: 16.8m and only biopsy+RT+nimotuzumab: 14.2 m.

Retrospective and prospective large-scale studies are significant, although they have not been randomized, such as the study of the Oncological Radiotherapy Group (RTOG), Curran et al. [32] also referred by other authors [33]. We must also highlight the prospective study of Laws and others where an SVM of 21.0 vs. 45.3 weeks (only biopsy vs. surgically resected, respectively (p<0.0001)) [34]. Chaichana et al. also came to similar results [35]. In a multicenter study conducted in Cuba by Solomon MT (Universidad Médica de la Habana, Cuba, unpublished observations, 2002), in three Neurosurgery Services of Havana, the usefulness of the prolongation of the time of SV of extensive tumor surgical resection for HGGs, was an SV rate at 24 months: 20.7% vs. 8.3% who underwent only biopsy.

In favor of biopsy: In the other hand, the surgical decision is more complex in the case of patients with early lesions detection. This means that they come with minimal symptoms and few elements to the physical examination. In the neuroimaging, we observed lesions in important areas of the brain that can be damaged after major resective surgeries. Another important element is the role that could play (and in fact does), the molecular characteristics of each glioma. Specifically, when determining the methylation of the promoter of the enzyme methyl guanine methyl transferase (MGMT), the role of tumor resection can be put into the background [36]. This means, for example, that only one biopsy is performed, and determining the levels of MGMT, it is possible, in some patients, to achieve greater benefits with chemotherapy than with surgical resection.

In a first study published by Kreth et al., it was found that the SVM of the selected patients who received resection (N=126) and who received a biopsy (N=99) did not have statistically significant differences (37 vs. 33 weeks, respectively, p=0.09) [37]. Then, in 2013, as part of the German Working Group for Gliomas, Kreth et al. published a multicenter study where 345 patients were recruited and the promoter methylation of the MGMT enzyme was evaluated. The biopsy was performed on 21% of the patients; and the rest, total or partial resection. This investigation showed an SVM=26.2 months (patients with only biopsy, who received the complete treatment of RT+temozolamide and methylation of the MGMT) and SVM=14.4 months (patients who received similar adjuvant treatment to a total tumor respective surgery, but who did not have methylated the promoter of the MGMT enzyme) [36].

The development of neuroimaging techniques have allowed that in diffuse brainstem lesions, it is exceptional to carry out a biopsy to

confirm the diagnosis. Biopsies are only recommended when there are doubts in the image, in the case of unusual presentations, or where it is necessary for some protocols. The use of stereotaxic methods is also suggested for the safety of the patient [10,15,22,23,28,34].

We consider that: Maximal surgical resection, if feasible, without major additive neurological deficit, continues to be the standard.

Degree of tumor resection

The second point to discuss is: What is the concept and the benefit of the extend of removal of the tumor? In the last 10 years, papers are showing non clear criteria ranging from 70% to 100% per cent.

The impact of the surgery on the survival of patients with gliomas is still under debate. It is the only prognostic factor that can be influenced, by neurosurgeons, when facing this aggressive disease in the operating room. The infiltrative and diffuse natures of the tumor are frequent elements that threaten a total tumor resection [38,39]. In the most recent and extensive databases, it is estimated that a total tumor resection can be performed to 40% of the patients [40,41]. The development of microsurgical techniques and the implementation of preoperative and intraoperative technologies facilitate the surgeon's surgical intervention. The techniques can be imaging - for surgical planning (preoperative), as well as for intraoperative guidance - and functional [42-48] (Table 2).

Currently, researchers intend to determine how much tumor should be resected and what maximum residual tumor volume should be to achieve benefits in terms of SV and progression-free survival (PFS). The limits that have been proposed to obtain better results in terms of survival after surgery for high-grade gliomas are: 70% [49] 78%, [50] 98% [51] and up to 100% [52]. It is also proposed that the residual tumor volume should not exceed 5 cm³ [49].

The study that shows the best evidence is that performed on patients with HGG by means of fluorescence with 5-ALA. [31,32]. Other randomized studies that demonstrated the benefit of the extension of tumor resection, although it was not its primary objective are:

- In a subsequent analysis of Westphal' study (chemotherapy with carmustine wafers, 2003), it was revealed that the SVM was higher in the patients who received a tumor resection greater than 90% with the intraoperative placement of the biodegradable support of carmustine (14.5 vs. 12.4 months, p=0.02). Different was the result obtained with patients who underwent partial tumor resection (11.7 vs. 10.6 months, p=0.98) [53].
- CT to evaluate the utility of the surgery's gliomas guided by

Relation with the surgery	Technology Tools
Pre operatories	<ul style="list-style-type: none"> • Tridimensional Images (CT and MRI) • Perfusion MRI • Functional Images (PET and SPECT) • Spectroscopy • Vascular Brain Studies. • Tractography
Intra operatories	<ul style="list-style-type: none"> • Microsurgery • Intraoperative Ultrasound 2D and 3D • Fluorescent guided surgery (5-ALA) • Intraoperative MRI • Awake surgery • Intraoperative cerebral mapping, cortical brain stimulation.

Table 2: Tools available to minimize trans-surgical brain damage in the surgery of intra-axial tumors.

MRI. This study concluded that the total resection, confirmed by postoperative images, was greater in the group that used intraoperative MRI in relation to patients who received conventional surgery: 96% vs. 68%, $p=0.0023$ [45].

Other large-scale prospective and retrospective studies provide concrete evidence on the benefit of the extension of the resection, even if they are not randomized. The Lacroix's study show a SVm of 13.0 months vs. 8.8 months for patients with tumor resections above and below 98%, respectively. They also found that patients with better performance status and younger ones benefit more [51].

Another work is the one developed by Sanai et al. [50] and the most recent study by Chaichana et al. who considered that a tumor resection above 70% and a residual tumor smaller than 5 cm³ are associated with higher SV and PFS [49].

In general, the results in the reviewed literature agree that the surgical reduction of a brain tumor with mass effect in the preoperative images offers advantages, both in the relief of the symptoms and in the response to the adjuvant treatments that are applied and, therefore, in the extension of the SV. In randomized trials, which secondarily evaluated the benefit of surgical tumor resection in patient survival, this benefit ranged from 2-3 months. For open, prospective or retrospective studies, the benefit has ranged between 4-5 months, which suggests that the benefit is limited in most patients.

The analyzed randomized clinical trials have biases related fundamentally to the small sample sizes that are achieved by readjusting the data to perform the analysis separately, which affects the statistical comparison. In addition, post hoc subgroups are not randomized as in the original study design, so known and unknown prognostic variables are no longer in equilibrium in the comparison groups [23,54].

Another problem with these clinical trials is that the determination of the grade of tumor resection (GRT) value, is too simple. As shown by Kubben et al. [55] the postoperative evaluation of residual HGG volume is highly subjective and prone to observer bias, as well as to disagreement among several observers. Fluorescence-guided surgery with 5-ALA is considered the best evidence in the study of patients with HGG [31]. The increase in PFS at six months has been demonstrated for more radical resections confirmed with the fluorescence, in relation to those operated under conventional lighting.

In the case of partial tumor resection (below 70%), it is always expected that its benefit will be lower than the one obtained with more extensive resections. This was the case in Solomon's work [10].

It is described that the beneficial effect of surgery can be obscured by iatrogenic neurological deficits that overshadow the evolution and worsen the quality of life, regardless of the degree of resection. If you add that many patients are diagnosed with large tumors that infiltrate more than one lobe, more extensive resections become a challenge. For this reason we recommend a biopsy when an extensive resection, with a minimum or no amount of radiographic residual tumor, is not safe. Likewise, it is recommended in patients who do not have a well-flowered picture of intracranial hypertension, and when it is preferable to decompress the brain in the patient.

Starting from the hypothesis that total microscopic resection of HGG cells is not possible without significant morbidity, the clinical impact of resection rests fundamentally on whether the residual tumor (microscopic or macroscopic) will respond to the further therapy. Randomized CT was able to reinforce this central principle, since the benefit of macroscopic total resection was more evident in patients

who responded to treatment with temozolamide or with BCNU [53,56-59]. In the national study mentioned [10], the most benefited with the nimotuzumab treatment were the patients who underwent the most respective surgery possible.

In any case it will be an advantage to have access to tumor biomarkers such as the determination of MGMT protein methylation promoter levels, the determination of alterations such as the 1p/19q codeletion, and the epidermal growth factor receptor expression, just quoting the most used ones. These biomarkers not only have diagnostic and prognostic importance, but are selective targets for the adjuvant treatment of HGG surgery [58].

To define a total tumor resection, the following aspects should be taken into account:

- The performance of the imaging study between 24 hours and 5 postoperative days.
- If the available study is the computerized tomography of the skull, it should be with the use of contrast media. Total resection will be considered if there is no contrast uptake in lesions that previously did so.
- If the available study is cranial MRI, total resection will be considered if there is no contrast uptake in T1 techniques, or if the residual tumor volume is less than 0.175 cm³.

Therefore, the maximum possible surgical resection should be performed, without over-adding large neurological deficits.

Surgery Or Only Palliative Treatment

In a meeting of the working group of the Neurooncology Section of the Cuban Society of Neurology and Neurosurgery (record of meeting, Cuban Society of Neurology and Neurosurgery, June 2017), a third controversy arose: to perform surgery or only palliative treatment? In order to make this decision, it is necessary to rely on the results expected after immediate surgical treatment. Patients should be evaluated to understand which ones are more or less likely to worsen their neurological and clinical status, or even die after surgery [59].

On this subject several articles were reviewed. The first is a multicenter study conducted in Norway, which evaluated the surgical results of all brain tumors in the last 50 years, in the three centers where neurosurgical patients were treated. It was the HGG that contributed the highest percentage of deaths in the first month after surgery [60]. This result is comparable to those shown in the most extensive databases in the United States. The reasons why these results are obtained are discussed in the Journal of Neurosurgery [61]. Among others, the need for training of a considerable number of residents is mentioned. It also allows not denying surgery for patients arriving even with poor neurological status, and they are also candidates for intervention by those beginners. Surgery by non-expert personnel could lead to high tissue manipulation, an element that affects the immediate postoperative neurological evolution. Another article refers to the results in a General Hospital, where a high number of patients with tumor lesions arrive, and gliomas are the most frequent cause. It was shown, statistically, that patients older than 60 years and operated with a low score on the Karnofsky Scale are more likely to die in the first month [62]. It is recommended to propose palliative treatment to patients older than 60 years, who arrives with a low score in the Karnofsky Scale (below 60 points) and that, with the previous treatment with cerebral dehydrators and steroids in the appropriate doses, are not improving the edema that surrounds this type of lesions. It is preferable that they stay at home,

due to the high probability of dying in the first month of surgery. It would only be justified to undertake the surgical act if the neurosurgical service considers it with a teaching interest, and prior approval of the family, due to the high risk that this entails. [63,64].

Conclusions

- Only biopsy for brain tumors suspected to be GB, must be in selected patients and tumors where resection could add complications.
- The goal of GTR must be considered for all patients, for whom the expected mortality and morbidity could be low.
- The best technologies must be implemented to get wider and safer tumor resections.
- In the era of the knowledge of molecular characteristic of brain tumor cell, the oncological treatment must be personalized using biomarkers.

Acknowledgements

- To the colleagues who participate in the discussions of the Neurooncology Section of the Cuban Society of Neurology and Neurosurgery with their valuable contributions.
- To the Doctor of Sciences Ole Solheim, for the great intellectual production and the wide and open discussions on most of the a.m. topics.

Conflict of Interests

The authors declare no conflict of interest.

References

1. Cavalli F (2012) El gran desafío. La Habana: Editorial de Ciencias Médicas.
2. Alonso AOJ, Oramas MA, González GAE (2017) Cancer control in the municipality of Manicaragua. *Medicentro Electrónica* 21: 234-236.
3. Ostrom QT, Gittleman H, Liao P, Vecchione-Koval T, Wolinsky Y, et al. (2017) CBTRUS Statistical Report: Primary brain and other central nervous system tumors diagnosed in the United States in 2010-2014. *Neuro Oncol* 19: 1-88.
4. Howlader N, Noone AM, Krapcho M, Miller D, Bishop K, et al. (2016) SEER Cancer Statistics Review, 1975-2014. Bethesda: National Cancer Institute.
5. Siegel R, Naishadham D, Jemal A (2013) Cancer statistics: 2013. *CA Cancer J Clin* 63: 11-30.
6. Cuba. Ministerio de Salud Pública. Anuario Estadístico de Salud 2017. La Habana: MINSAP; 2018.
7. Cuba (2012) Ministerio de Salud Pública. Programa integral para el control del cáncer en Cuba. Anuario de incidencia de cáncer en Cuba 2008. La Habana: ECIMED.
8. Solheim O, Gulati S, Jakola AS (2014) Glioblastoma resection: In search of a threshold between worthwhile and futile. *Neuro Oncol* 16: 610-611.
9. Alert SJ, Jiménez MJ (2004) Tendencias del tratamiento radiante en los tumores del Sistema Nervioso Central. *Rev Cubana Med* 43: 2-3.
10. Solomon Cardona MT (2015) Eficacia y seguridad en el tratamiento combinado de cirugía, radioterapia y nimotuzumab en pacientes con gliomas de alto grado de malignidad. Repositorio de Infomed. La Habana.
11. Stupp R, Hegi ME, Mason WP, van den Bent MJ, Weller M, Fisher B, et al. (2005) Radiotherapy plus concomitant and adjuvant temozolomide for glioblastoma. *N Engl J Med* 352: 987-996.
12. Nabors LB, Portnow J, Ammirati M, Baehring J, Brem H, et al. (2017) NCCN guidelines insights: Central nervous system cancers, Version 1.2017. *J Natl Compr Canc Netw* 15: 1331-1345.
13. Johnson DR, Omuro AMP, Ravelo A, Sommer N, Guerin A, et al. (2017) Overall survival in patients with glioblastoma before and after bevacizumab approval. *Curr Med Res Opin* 10: 1-8.
14. Solomon MT, Selva JC, Figueredo J, Vaquer J, Toledo C, et al. (2013) Radiotherapy plus nimotuzumab or placebo in the treatment of high grade glioma patients: Results from a randomized, double blind trial. *BMC Cancer* 13: 299.
15. Krivosheya D, Prabhu SS, Weinberg JS, Sawaya R (2016) Technical principles in glioma surgery and preoperative considerations. *J Neuro Oncol* 130: 243-252.
16. Reponen E, Tuominen H, Korja M (2014) Evidence for the use of preoperative risk assessment scores in elective cranial Neurosurgery: A systematic review of the literature. *Anesth Analg* 119: 420-32.
17. Hervey-Jumper SL (2014) Reoperation for recurrent high-grade glioma: A current perspective of the literature. *Neurosurgery* 75: 491-499.
18. Eseonu CI, Rincon-Torroella J, ReFaey K, Lee YM, Nangiana J, et al. (2017) Awake craniotomy vs craniotomy under general Anesthesia for peritumoral gliomas: Evaluating perioperative complications and extent of resection. *Neurosurgery* 81: 481-489.
19. Chaichana KL, Zadnik P, Weingart JD, Olivi A, Gallia GL, et al. (2013) Multiple resections for patients with glioblastoma: Prolonging survival. *J Neurosurg* 118: 812-820.
20. Brown TJ, Brennan MC, Li M, Church EW, Brandmeir NJ, et al. (2016) Association of the extent of resection with survival in glioblastoma: A systematic review and meta-analysis. *JAMA Oncol* 2: 1460-1469.
21. Vuorinen V, Hinkka S, Farkkila M, Jaaskelainen J (2003) Debulking or biopsy of malignant glioma in elderly people: A randomized study. *Acta Neurochir (Wien)* 145: 5-10.
22. Weller M, van den Bent M, Hopkins K, Tonn JC, Stupp R. EANO, et al. (2014) guideline for the diagnosis and treatment of anaplastic gliomas and glioblastoma: Review. *Lancet Oncol* 15: 395-403.
23. Metcalfe SE, Grant R (2011) Biopsy versus resection for malignant glioma. *Cochrane Database Syst Rev* 3: CD002034.
24. Chaichana KL, Cabrera-Aldana EE, Jusue-Torres I, Wijesekera O, Olivi A (2014) When gross total resection of a glioblastoma is possible, how much resection should be achieved? *World Neurosurg* 82: 257-265.
25. Tsitlakidis A, Foroglou N, Venetis CA, Patsalas I, Hatzisotiriou A, et al. (2010) Biopsy versus resection in the management of malignant gliomas: A systematic review and meta-analysis. *J Neurosurg* 112: 1020-1032.
26. Almenawer SA, Badhiwala JH, Alhazzani W, Greenspoon J, Farrokhyar F, et al. (2015) Biopsy versus partial versus gross total resection in older patients with high-grade glioma: A systematic review and meta-analysis. *Neuro Oncol* 17: 868-881.
27. Walker MD, Alexander E, Hunt WE, MacCarty CS, Mahaley MS, et al. (1978) Evaluation of BCNU and/or radiotherapy in the treatment of anaplastic gliomas: A cooperative clinical trial. *J Neurosurg* 49: 333-343.
28. Gehan EA, Walker MD (1977) Prognostic factors for patients with brain tumors. *Natl Cancer Inst Monogr* 46: 189-195.
29. Wangaryattawanich P, Hatami M, Wang J, Thomas G, Flanders A, et al. (2015) Multicenter imaging outcomes study of The Cancer Genome Atlas Glioblastoma patient cohort: Imaging predictors of overall and progression-free survival. *Neuro Oncol* 17: 1525-1537.
30. Stummer W, van den Bent MJ, Westphal M (2011) Cytoreductive surgery of glioblastoma as the key to successful adjuvant therapies: New arguments in an old discussion. *Acta Neurochir (Wien)* 153: 1211-1218.
31. Stummer W, Tonn JC, Goetz C, Ullrich W, Stepp H, et al. (2014) 5-Aminolevulinic acid-derived tumor fluorescence: The diagnostic accuracy of visible fluorescence qualities as corroborated by spectrometry and histology and postoperative imaging. *Neurosurgery* 74: 310-320.
32. Curran WJ, Scott CB, Horton J, Nelson JS, Weinstein AS, et al. (1993) Recursive partitioning analysis of prognostic factors in three Radiation Therapy Oncology Group (RTOG) malignant gliomas trials. *J Natl Cancer Inst* 85: 704-710.
33. Gilbert MR, Wang M, Aldape KD, Stupp R, Hegi ME, et al. (2013) Dose-dense temozolomide for newly diagnosed glioblastoma: A randomized phase III clinical trial. *J Clin Oncol* 31: 4085-4091.
34. Laws ER, Parney IF, Huang W, Anderson F, Morris AM, et al. (2003) Survival following surgery and prognostic factors for recently diagnosed malignant glioma: Data from the glioma outcomes project. *J Neurosurgery* 99: 467-473.

35. Chaichana KL, Jusue-Torres I, Navarro-Ramirez R, Raza SM, Pascual-Gallego M, et al. (2014) Establishing percent resection and residual volume thresholds affecting survival and recurrence for patients with newly diagnosed intracranial glioblastoma. *Neuro Oncol* 16: 113-122.
36. Kreth FW, Thon N, Simon M, Westphal M, Schackert G, et al. (2013) Gross total but not incomplete resection of glioblastoma prolongs survival in the era of radiochemotherapy. *Ann Oncol* 24: 3117-3123.
37. Kreth FW, Berlis A, Spiroupolus V, Faist M, Scheremet R, et al. (1999) The role of tumor resection in the treatment of glioblastoma multiform in adults. *Cancer* 86: 2117-2123.
38. Chan DTM, Yi-Pin SH, Poon WS (2018) 5-Aminolevulinic acid fluorescence guided resection of malignant glioma: Hong Kong experience. *Asian J Surg* 41: 467-472.
39. Zhao S, Wu J, Wang C, Liu H, Dong X, et al. (2013) Intraoperative fluorescence-guided resection of high-grade malignant gliomas using 5-aminolevulinic acid-induced porphyrins: A systematic review and meta-analysis of prospective studies. *PLoS One* 8: e63682.
40. Seddighi A, Akbari ME, Seddighi AS, Pirayesh E, Soleymani MM, et al. (2015) Radioguided surgery using gamma detection probe technology for resection of cerebral glioma. *Hell J Nucl Med* 18: 68-75.
41. Eseonu CI, ReFaey K, Garcia O, John A, Quinones-Hinojosa A, et al. (2017) Awake craniotomy anesthesia: A comparison of the monitored anesthesia care and asleep-awake-asleep techniques. *World Neurosurg* 104: 679-686.
42. Eseonu CI, Rincon-Torroella J, ReFaey K, Lee YM, Nangiana J, et al. (2017) Awake craniotomy vs craniotomy under general anesthesia for periorlandic gliomas: Evaluating perioperative complications and extent of resection. *Neurosurgery* 81: 481-489.
43. Johnson LA, Wander JD, Sarma D, Su DK, Fetz EE, et al. (2013) Direct electrical stimulation of somatosensory cortex in humans using electrocorticography electrodes: A qualitative and quantitative report. *J Neural Eng* 10: 036021.
44. Obermueller T, Schaeffner M, Shiban E, Droese D, Negwer C, et al. (2015) Intraoperative neuromonitoring for function-guided resection differs for supratentorial motor eloquent gliomas and metastases. *BMC Neurol* 15: 211.
45. Senft C, Bink A, Franz K, Vatter H, Gasser T, et al. (2011) Intraoperative MRI guidance and extent of resection in glioma surgery: A randomised, controlled trial. *Lancet Oncol* 12: 997-1003.
46. Sweeney JF, Smith H, Taplin A, Perloff E, Adamo MA (2018) Efficacy of intraoperative ultrasonography in neurosurgical tumor resection. *J Neurosurg Pediatr* 16: 1-7.
47. Senders JT, Muskens IS, Schnoor R, Karhade AV, Cote DJ, et al. (2017) Agents for fluorescence-guided glioma surgery: A systematic review of preclinical and clinical results. *Acta Neurochir* 159: 151-167.
48. Barone D, Lawrie TA, Hart MG (2014) Image guided surgery for the resection of brain tumours. *Cochrane Database Syst Rev* 28: CD009685.
49. Chaichana KL, Jusue-Torres I, Navarro-Ramirez R, Raza SM, Pascual-Gallego M, et al. (2014) Establishing percent resection and residual volume thresholds affecting survival and recurrence for patients with newly diagnosed intracranial glioblastoma. *Neuro Oncol* 16: 113-122.
50. Sanai N, Polley MY, McDermott MW, Parsa AT, Berger MS (2011) An extent of resection threshold for newly diagnosed glioblastomas. *J Neurosurg* 115: 3-8.
51. Lacroix M, Abi-Said D, Fourney DR, Gokaslan ZL, Shi W, et al. (2001) A multivariate analysis of 416 patients with glioblastomamultiforme: Prognosis, extent of resection, and survival. *J Neurosurg* 95: 190-198.
52. Stummer W, Reulen HJ, Meinel T, Pichlmeier U, Schumacher W, et al. (2008) Extent of resection and survival in glioblastomamultiforme: Identification of and adjustment for bias. *Neurosurgery* 62: 564-76.
53. Westphal M, Hilt DC, Bortey E, Delavault P, Olivares R, et al. (2003) A phase 3 trial of local chemotherapy with biodegradable carmustine (BCNU) wafers (Gliadel wafers) in patients with primary malignant glioma. *Neuro Oncol* 5: 79-88.
54. Omuro A (2013) Glioblastoma and other malignant gliomas: A clinical review. *JAMA* 310: 1842-1850.
55. Kubben PL, Postma AA, Kessels AG, van Overbeeke JJ, van Santbrink H (2010) Intraobserver and interobserver agreement in volumetric assessment of glioblastomamultiforme resection. *Neurosurgery* 67: 1329-1334.
56. Balogun JA, Rutka JT (2018) Surgery of Intracranial Gliomas in Children. *Prog Neurol Surg* 30: 204-217.
57. Stummer W, van den Bent MJ, Westphal M (2011) Cytoreductive surgery of glioblastoma as the key to successful adjuvant therapies: New arguments in an old discussion. *Acta Neurochir (Wien)* 153: 1211-1218.
58. Westphal M, Heese O, Steinbach JP, Schnell O, Schackert G (2015) A randomized, open label phase III trial with nimotuzumab, an anti-epidermal growth factor receptor monoclonal antibody in the treatment of newly diagnosed adult glioblastoma. *Eur J Cancer* 51: 522-532.
59. Moiyadi AV, Shetty PM (2012) Perioperative outcomes following surgery for brain tumors: Objective assessment and risk factor evaluation. *J Neurosci Rural Pract* 3: 28-35.
60. Solheim O, Jakola AS, Gulati S, Johannesen TB (2012) Incidence and causes of perioperative mortality after primary surgery for intracranial tumors: A national, population- based study. *J Neurosurg* 116: 825-834.
61. Ikeda D, Chiocca A (2012) Perioperative mortality. *J Neurosurgery* 116: 821-824.
62. Solomon MT, Roig E, Pila M, Dominguez W, Crombet T (2014) Mortality from malignant brain tumors within the first 30 days after surgery. *Rev Cubana Cir* 53: 244-255.
63. Binello E, Green Sh, Germano IM (2012) Radiosurgery for high-grade glioma. *Surg Neurol Int* 3: 118.
64. Bokstein F, Blumenthal DT, Corn BW, Gez E, Matcseyevsky D, et al. (2016) Stereotactic radiosurgery (SRS) in high-grade glioma: Judicious selection of small target volumes improves results. *J Neurooncol* 126: 551-557.