

# Surgical Management of C5 Palsy Resulting from Posterior Spinal Decompression for the Treatment of Cervical Spondylotic Myelopathy

Khaled Saoud\*, Amr El-Shehaby and Ayman El-Shazly

Department of Neurosurgery, Faculty of Medicine, Ain Shams University, Cairo, Egypt

## Abstract

**Objective:** To assess the feasibility of anterior cervical procedures in the treatment of C5 palsy occurring after posterior cervical decompression procedures done for the treatment of cervical spondylotic myelopathy.

**Introduction:** In this study we hypothesized that anterior cervical decompression would benefit these patients through widening the cervical foramen, directly by rongeurs and drills and indirectly by placing an intervertebral spacer (cervical cage). The aim of the study is to assess whether a more proactive approach would benefit these patients.

**Materials and methods:** Between January 2005 and September 2011, 200 posterior cervical procedures have been done by the authors, for the treatment of cervical spondylotic myelopathy (CSM). The procedures done were laminectomy with or without instrumentation. Forty cases developed C5 palsy postoperatively (20%). 20 cases (50%) presented immediate postoperatively and the rest presented during the first week postoperatively. All the cases started a course of conservative treatment of steroids, analgesics and physiotherapy. Thirty patients (75%) improved on conservative treatment. Ten patients did not improve after more than one year of conservative management. Two cases had a single level anterior cervical discectomy and cage fusion (ACDF), 3 cases had single level ACDF with plate fixation and 3 cases had 2 levels ACDF with plate fixation. Two cases had 3 levels ACDF with interbody fusion and plate fixation. The operative choice was made in order to increase the lordotic curve and the foraminal diameter.

**Results:** Immediately postoperatively all patients had improved radicular pain. Assessment of the motor power was made immediately postoperative and 3 months afterwards with continuous physiotherapy. There was no change in the C5 palsy in all cases on the immediate postoperative examination, whereas all cases showed improvement of at least 2 grades in the 3 months postoperative visits. All patients at the final follow up had an MMT (Manual Muscle Test) grade of at least 3. Six patients reached an MMT grade of 4 or more. One case had recurrent myelopathy 9 months after 3 levels ACDF and fixation. His MRI showed adjacent segment degeneration at a higher level and had led to myelopathy. He improved on conservative treatment. Two cases died during follow up period: one at 10 months postoperatively from complications of massive myocardial infarction and the other one 15 months postoperatively from bronchogenic carcinoma diagnosed 7 months after surgery.

**Conclusion:** Postoperative C5 palsy following posterior decompression for cervical spondylotic myelopathy is not an uncommon occurrence and the majority of cases will respond to conservative treatment. Anterior decompression procedures may offer a safe and effective solution for those few patients who do not respond to a prolonged period of conservative management.

**Keywords:** C5 palsy; Anterior cervical procedures; Cervical Spondylotic Myelopathy (CSM); Cervical cage; Cervical plating

## Objective

To assess the feasibility of anterior cervical procedures in the treatment of C5 palsy occurring after posterior cervical decompression procedures done for the treatment of cervical spondylotic myelopathy.

## Introduction

Posterior decompression procedures are commonly performed in the treatment of multiple level cervical compressive spondylotic myelopathy. These include laminectomy alone, laminoplasty alone and laminectomy/laminoplasty with posterior instrumentation. C5 palsy following cervical laminectomy for cervical spondylosis was first reported by Scoville [1] and Stoops and King [2]. It has also been reported after other posterior-based techniques. The incidence varies from 0-50% depending on the technique used, how the condition is defined and which patient group is being analysed [3,4-8,9,10]. Takemitsu et al. [11] reported a higher incidence among patients undergoing instrumentation than those treated by laminoplasty alone.

Several etiologies have been proposed to explain this phenomenon including direct root injury, posterior spinal cord drift, spinal cord ischemia, reperfusion injury and segmental cord affection [4,7-9]. Additional instrumentation is suspected of increasing the incidence of

C5 palsy through iatrogenic foraminal stenosis [12,5,6,10] and added tension in the spinal cord and roots caused by correcting the spinal alignment [6,10]. Also in some instances it may be multifocal [9].

No specific treatments have been suggested for postoperative C5 palsy. Mainly conservative management has been advocated for these cases [7,13] with varying degrees of recovery and latency to recovery.

In this study we hypothesized that anterior cervical decompression would benefit these patients through widening the cervical foramen, directly by rongeurs and drills and indirectly by placing an intervertebral spacer (cervical cage). The aim of the study is to assess whether a more proactive approach would benefit these patients.

**\*Corresponding author:** Khaled Saoud, Assistant Professor, Department of Neurosurgery, Faculty of Medicine, Ain Shams University, Consultant Neurosurgeon, Arab Contractors Hospital, Cairo, Egypt, E-mail: [ksaoud@yahoo.com](mailto:ksaoud@yahoo.com)

**Received** November 27, 2012; **Accepted** January 16, 2013; **Published** January 18, 2013

**Citation:** Saoud K, El-Shehaby A, El-Shazly A (2013) Surgical Management of C5 Palsy Resulting from Posterior Spinal Decompression for the Treatment of Cervical Spondylotic Myelopathy. J Spine 2: 132. doi:10.4172/2165-7939.1000132

**Copyright:** © 2013 Saoud K, et al. This is an open-access article distributed under the terms of the Creative Commons Attribution License, which permits unrestricted use, distribution, and reproduction in any medium, provided the original author and source are credited.

## Materials and Methods

### Clinical data

Between January 2005 and September 2011, 200 posterior cervical procedures have been done by the authors, for the treatment of cervical spondylotic myelopathy (CSM). The procedures done were laminectomy with or without instrumentation. Forty cases developed C5 palsy postoperatively (20%). 20 cases (10%) presented immediate postoperatively and the rest presented during the first week postoperatively. An MRI was done once C5 palsy was detected to exclude intraspinal pathology such as hematoma or cord injury.

C5 palsy, in general, was defined as postoperative occurrence of paralysis of the deltoid muscle with no deterioration of myelopathy. In patients who had preoperative deltoid paralysis, C5 palsy was considered when manual muscle test (MMT) of the deltoid showed worsening of 1 or more grades, postoperatively.

All the cases started a course of conservative treatment of steroids, analgesics and physiotherapy. Thirty patients (75%) improved on conservative treatment. Ten patients did not improve after more than one year of conservative management. The average age among the ten patients included in this study was 63 years (55-72 years). There were 8 males and 2 females.

For the sake of avoiding confusion certain definitions will be assigned to the occurrence of C5 palsy according to its relation to the corrective surgery. Post posterior decompression C5 palsy (PPDCP) refers to C5 palsy occurring after posterior decompression surgery. While, post anterior decompression C5 palsy (PADCP) refers to the status of the C5 palsy after corrective anterior decompression.

These 10 cases presented by radicular pain of C5 distribution and variable degrees of motor weakness. We did not usually tend to operate on cases of mild weakness. The degree of PPDCP and PADCP was graded in our study using the manual muscle test (graded from 0 to 5, with 0 as no movement and power and 5 with normal strength). The PPDCP in five of the studied cases was grade 0 (2 immediately and 3 over one week period), 3 were grade 1 and 2 were grade 2.

Two cases had a single level anterior cervical discectomy and cage

fusion (ACDF), 3 cases had single level ACDF with plate fixation and 3 cases had 2 levels ACDF with plate fixation. Two cases had 3 levels ACDF with interbody fusion and plate fixation. The operative choice was made in order to increase the lordotic curve and the foraminal diameter. The primary operative goal was to perform foraminotomy at C4-5 level; however, since we performed a fusion technique in C4-5 level, we operated on any degenerated levels adjacent to this level in order to reduce the incidence of future need of reoperation.

## Results

### Clinical results

Immediately postoperatively all patients had improved radicular pain. Assessment of the motor power was made immediately postoperative and 3 months afterwards with continuous physiotherapy. There was no change in the C5 palsy in all cases on the immediate postoperative examination, whereas all cases showed improvement of at least 2 grades in the 3 months postoperative visits. All patients at the final follow up had an MMT grade of at least 3. Six patients reached an MMT grade of 4 or more. Motor power improvement is shown in table 1.

One case had recurrent myelopathy 9 months after 3 levels ACDF and fixation. His MRI showed adjacent segment degeneration at a higher level led to myelopathy (Figures 1 and 2). He improved on conservative treatment. Two cases died during follow up period one at 10 months postoperatively from complications of massive myocardial infarction and the other one 15 months postoperatively from bronchogenic carcinoma diagnosed 7 months after surgery.

### Radiological results

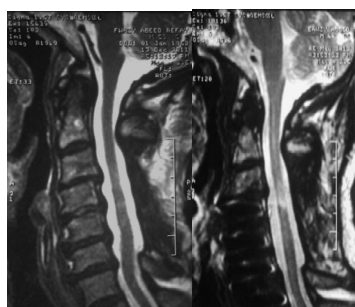
All cases had plain radiographs to assess fusion in 3 months postoperatively. Eight cases out of 10 (80%) had solid fusion at three months postoperatively. One case had solid fusion in the 6 months postoperatively. The last patient had pseudoarthrosis, but refused a redo surgery as he was clinically intact.

## Discussion

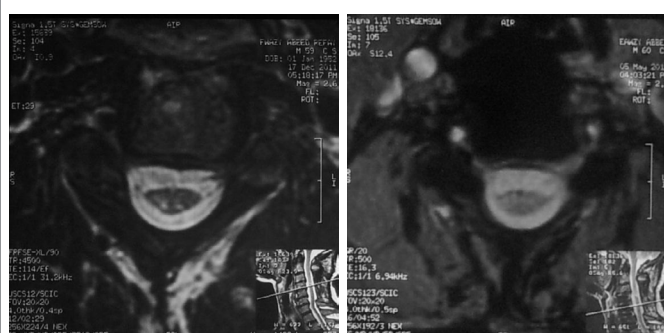
The incidence of postoperative C5 palsy following posterior

Patient	Age	Sex	Presentation	Operative technique	Preoperative motor power	Postoperative motor power after 3 months
1	60	M	Immediate postoperative Grade 1 motor weakness bilaterally and radicular pain following cervical laminectomy	2 levels ACDF and plate	1	4
2	64	F	Immediate postoperative Rt sided radicular C5 pain and motor weakness following cervical laminectomy	3 levels ACDF with plate	0	5
3	72	F	5 days postoperative cervical laminectomy, Rt Grade 2, and Lt Grade 3 motor weakness following cervical laminectomy	1 level ACDF without plate	2	4
4	70	M	Immediate postoperative bilateral, Lt Grade 0 and Rt Grade 1 motor weakness of C5 distribution following cervical laminectomy	2 levels ACDF with plate	0	4
5	68	M	Started 4 days postoperative, progressed over one week to Grade 0 bilateral C5 weakness and radicular pain following cervical laminectomy	3 levels ACDF with plate	0	3
6	55	M	4 days postoperative Grade 0 C5 weakness with radicular pain bilaterally following cervical laminectomy	2 levels ACDF with plate	0	3
7	57	M	One week postoperative Grade 0 weakness on the left and Grade 1 on the right following cervical laminectomy	1 level ACDF with plate	0	3
8	63	M	Immediate postoperative Grade 1 motor weakness following cervical laminectomy	1 level ACDF with plate	1	4
9	69	M	Presented 48 hours postoperative with Lt Grade 1 and Rt Grade 2 C5 weakness and radicular pain following cervical laminectomy	1 level ACDF with plate	1	3
10	55	M	5 days postoperative Grade 2 C5 palsy and radicular pain following cervical laminectomy	1 level ACDF without plate	2	5

**Table 1:** Demographic data for patients with C5 palsy.



**Figure 1:** Pre operative T2 midsagittal MRI of the case that developed myelopathy 2 months after surgery. Signal changes in the cord at C1-2 levels are seen.



**Figure 2:** Postoperative T2 midsagittal MRI of the case that developed myelopathy 2 months after surgery. Signal changes in the cord at C1-2 levels are seen.

cervical decompression for CSM has been reported to average 4.6% (range 0%-30%) [7-9,11,13,14]. The incidence of C5 palsy in this study is comparable at 20%. Generally, the recommendation for initial management of these cases is conservative management with a recovery rate ranging from 71% to 96% according the MMT grade [9]. Similarly, 75% of the patients in this study improved on conservative management alone.

Based on the assumption that the pathology in these cases is nerve root traction due to posterior cord shift following decompression surgery, several studies have suggested that prophylactic foraminotomy at the time of posterior decompression surgery would benefit these patients [15-17]. In addition, many cases have preexisting foraminal stenosis so foraminotomy would also be beneficial from this aspect.

To the best of our knowledge this study is first to report the surgical management of cases that had already developed C5 palsy following posterior decompression surgery, and had not improved on conservative treatment. We believe that the major pathology in these cases is at the root level, also as evidenced by the decreased incidence of C5 palsy reported when additional foraminotomy was performed with the posterior decompression [15]. Thus in addition to being able to decompress the root from the anterior approach, the insertion of an interbody cage would widen the foramen further and relieve any additional compression. Moreover, this theoretically would reduce the incidence of kyphosis following cervical laminectomy which ranges from 6% to 47% [18-21].

Neurological improvement was observed in all the patients postoperatively in spite of a latent period of at least one year from the time of the occurrence of the C5 palsy. Although the possibility that the

neurological improvement may have been part of the natural course of the disease cannot be excluded, the occurrence of this improvement in all patients and in such a short period after surgery would make it more likely to be the result of the surgery.

## Conclusion

PPDCP is not an uncommon occurrence and the majority of cases will respond to conservative treatment. Anterior decompression procedures may offer a safe and effective solution for those few patients who do not respond to a prolonged period of conservative management.

## References

- Scoville WB (1961) Cervical spondylosis treated by bilateral facetectomy and laminectomy. *J Neurosurg* 18: 423-428.
- Stoops WL, King RB (1962) Neural complications of cervical spondylosis: their response to laminectomy and foraminotomy. *J Neurosurg* 19: 986-999.
- Abumi K, Shono Y, Taneichi H, Ito M, Kaneda K (1999) Correction of cervical kyphosis using pedicle screw fixation systems. *Spine (Phila Pa 1976)* 24: 2389-2396.
- Chiba K, Toyama Y, Matsumoto M, Maruiwa H, Watanabe M, et al. (2002) Segmental motor paralysis after expansive open-door laminoplasty. *Spine (Phila Pa 1976)* 27: 2108-2115.
- Heller JG, Silcox DH 3rd, Sutterlin CE 3rd (1995) Complications of posterior cervical plating. *Spine (Phila Pa 1976)* 20: 2442-2448.
- Hojo Y, Ito M, Abumi K, Kotani Y, Sudo H, et al. (2011) A late neurological complication following posterior correction surgery of severe cervical kyphosis. *Eur Spine J* 20: 890-898.
- Imagama S, Matsuyama Y, Yukawa Y, Kawakami N, Kamiya M, et al. (2010) C5 palsy after cervical laminoplasty: a multicentre study. *J Bone Joint Surg Br* 92: 393-400.
- Kaneyama S, Sumi M, Kanatani T, Kasahara K, Kanemura A, et al. (2010) Prospective study and multivariate analysis of the incidence of C5 palsy after cervical laminoplasty. *Spine (Phila Pa 1976)* 35: E1553-1558.
- Sakaura H, Hosono N, Mukai Y, Ishii T, Yoshikawa H (2003) C5 palsy after decompression surgery for cervical myelopathy: review of the literature. *Spine (Phila Pa 1976)* 28: 2447-2451.
- Tanaka N, Nakanishi K, Fujiwara Y, Kamei N, Ochi M (2006) Postoperative Segmental C5 Palsy after Cervical Laminoplasty May Occur without Intraoperative Nerve Injury: A Prospective Study with Transcranial Electric Motor-Evoked Potentials. *Spine (Phila Pa 1976)* 31: 3013-3017.
- Takemitsu M, Cheung KM, Wong YW, Cheung WY, Luk KD (2008) C5 nerve root palsy after cervical laminoplasty and posterior fusion with instrumentation. *J Spinal Disord Tech* 21: 267-272.
- Abumi K, Shono Y, Ito M, Taneichi H, Kotani Y, et al. (2000) Complications of pedicle screw fixation in reconstructive surgery of the cervical spine. *Spine (Phila Pa 1976)* 25: 962-969.
- Nassr A, Eck JC, Ponnappan RK, Zanoun RR, Donaldson WF 3rd, et al. (2012) The incidence of C5 palsy after multilevel cervical decompression procedures: a review of 750 consecutive cases. *Spine (Phila Pa 1976)* 37: 174-178.
- Chen Y, Chen D, Wang X, Guo Y, He Z (2007) C5 palsy after laminectomy and posterior cervical fixation for ossification of posterior longitudinal ligament. *J Spinal Disord Tech* 20: 533-535.
- Katsumi K, Yamazaki A, Watanabe K, Ohashi M, Shoji H (2012) Can prophylactic bilateral C4/C5 foraminotomy prevent postoperative C5 palsy after open-door laminoplasty?: a prospective study. *Spine (Phila Pa 1976)* 37: 748-754.
- Komagata M, Nishiyama M, Endo K, Ikegami H, Tanaka S, et al. (2004) Prophylaxis of C5 palsy after cervical expansive laminoplasty by bilateral partial foraminotomy. *Spine J* 4: 650-655.
- Sasai K, Saito T, Akagi S, Kato I, Ohnari H, et al. (2003) Preventing C5 palsy after laminoplasty. *Spine (Phila Pa 1976)* 28: 1972-1977.
- Butler JC, Whitecloud TS 3rd (1992) Postlaminectomy kyphosis. Causes and surgical management. *Orthop Clin North Am* 23: 505-511.

- 
19. Kaptain GJ, Simmons NE, Replogle RE, Pobereskin L (2000) Incidence and outcome of kyphotic deformity following laminectomy for cervical spondylotic myelopathy. J Neurosurg 93: 199-204.
20. Kato Y, Iwasaki M, Fuji T, Yonenobu K, Ochi T (1998) Long-term follow-up results of laminectomy for cervical myelopathy caused by ossification of the posterior longitudinal ligament. J Neurosurg 89: 217-223.
21. Matsunaga S, Sakou T, Nakanishi K (1999) Analysis of the cervical spine alignment following laminoplasty and laminectomy. Spinal Cord 37: 20-24.