

Successful Hyperbaric Oxygen Therapy with Thyrotropin-Releasing Hormone Therapy for Delayed Neuropsychiatric Sequelae after Acute Carbon Monoxide Poisoning: A Case Study

Wataru Omori^{1,2}, Kenichi Oga¹, Kei Itagaki¹ and Minoru Takebayashi^{1,2*}

¹Department of Psychiatry, National Hospital Organization (NHO) Kure Medical Center and Chugoku Cancer Center, Japan

²Division of Psychiatry and Neuroscience, Institute for Clinical Research, National Hospital, Organization (NHO) Kure Medical Center and Chugoku Cancer Center, Japan

Abstract

Delayed neuropsychiatric sequelae (DNS) after acute carbon monoxide (CO) poisoning is a complication of CO intoxication. Hyperbaric oxygen (HBO) therapy is one of the only established treatments for CO poisoning, but as there is no specific treatment for DNS, the prognosis of DNS patients is generally poor. A 40-year-old male patient, following attempted suicide by CO poisoning, was referred to our department after having received HBO therapy at another hospital, but treatment had been subsequently discontinued due to patient agitation. The patient was diagnosed with DNS after acute CO poisoning, and we reinitiated HBO therapy. However, due to manifestation of symptoms of severe dementia, treatment was discontinued. After initiating thyrotropin-releasing hormone (TRH) therapy, psychiatric symptoms, such as difficulty in following instructions, improved, enabling the resumption of HBO therapy. Daily activities returned to premorbid levels following treatment. Thus, TRH therapy could be effective for patients with DNS due to acute CO poisoning who experience difficulty with HBO therapy.

Keywords: Hyperbaric oxygen therapy; Delayed neuropsychiatric sequelae; Thyrotropin-releasing hormone therapy

Introduction

Hyperbaric oxygen (HBO) therapy is often recommended for patients with acute carbon monoxide (CO) poisoning, especially in the case of severe poisoning or loss of consciousness [1]. Delayed neuropsychiatric sequelae (DNS) after acute CO poisoning is a complication of CO intoxication, in which neurological and psychiatric symptoms suddenly appear after a symptom-free interval of several days or a few weeks, including disorientation, memory disturbance, emotional instability, focal symptoms, personality changes, and urinary and faecal incontinence [2,3]. While HBO therapy decreases the incidence of DNS after CO poisoning [1,2], the prognosis of patients of DNS is generally poor, as there is no specific treatment for DNS. The current report describes a patient with DNS after acute CO poisoning. Because of difficulty following instructions due to agitation and decreased cognitive functioning, HBO therapy was discontinued. However, treatment with thyrotropin-releasing hormone (TRH) partially ameliorated the psychiatric symptoms, thereby allowing the resumption of HBO therapy, which in turn led to marked improvements in symptoms.

Case Report

A 40-year-old man experienced stress about his company's finances and complained of decreased appetite, insomnia, and depressive mood since August XXXX. On August 23, he attempted suicide by CO poisoning, burning charcoal briquettes in his car. He was found unconscious and was transported to a university hospital, where he was admitted for treatment. Brain magnetic resonance imaging (MRI) performed on admission revealed bilateral low-density areas in the globus pallidus. Carboxyhemoglobin (COHb) was 23.5%. Hyperbaric oxygen therapy was initiated 4 days following CO exposure. The patient displayed agitation; treatment could only be performed twice. Although cognitive functioning temporarily improved, the patient was transferred to a psychiatric hospital on September 7 because of persistent suicidal ideation. A mini-mental state examination (MMSE) was performed on the same day, and the patient's score was 19, of 30 points, indicating mild cognitive impairment. Diminished cognitive functions, such as memory disturbance and impaired calculation skills,

were also observed. Twenty-one days after CO exposure (Figure 1), the patient was referred to our department for inpatient resumption of HBO therapy because the patient's basic waves had slowed, as demonstrated by electroencephalography (EEG). The patient, who was accompanied by his wife, was ambulatory when he arrived at our hospital. The patient did not make eye contact, remained expressionless, spontaneously spoke few words, and mainly tended to remain immobile. His speech was often vague and incoherent. His COHb was 1.2%. EEG showed basic waves of approximately 4Hz with generalized slowing. The patient's MMSE score was 16 points, indicating moderate cognitive impairment. Based on the clinical course and findings from brain MRI (Figure 2), the patient was diagnosed with DNS after acute CO poisoning, and HBO therapy was initiated on the second day of admission.

The patient presented with decreased appetite and was observed urinating near the window of his room. Dressing apraxia and urinary and fecal incontinence were also observed. The patient demonstrated difficulty following instructions while in the HBO chamber, such as failing to lie down quietly and removing his oxygen mask on his own. The HBO chamber operator determined that patient safety was a serious issue discontinued HBO therapy after the fourth treatment session.

Forty-one days after CO exposure, the patient's MMSE score was zero, indicating severe cognitive impairment, and, due to prosopagnosia, the patient was unable to recognize his wife. The patient was unable to initiate speech, did not respond to questions, and unable to follow directions. Symptoms of apraxia, agnosia, decreased spontaneity, and

***Corresponding author:** Minoru Takebayashi, Department of Psychiatry, National Hospital Organization (NHO) Kure Medical Center and Chugoku Cancer Center, Japan, Tel: +81823223111; Fax: +81823210478; E-mail: mtakebayashi@kure-nh.go.jp

Received December 26, 2016; **Accepted** January 12, 2017; **Published** January 18, 2017

Citation: Omori W, Oga K, Itagaki K, Takebayashi M (2017) Successful Hyperbaric Oxygen Therapy with Thyrotropin-Releasing Hormone Therapy for Delayed Neuropsychiatric Sequelae after Acute Carbon Monoxide Poisoning: A Case Study. J Clin Case Rep 7: 912. doi: [10.4172/2165-7920.1000912](https://doi.org/10.4172/2165-7920.1000912)

Copyright: © 2017 Omori W, et al. This is an open-access article distributed under the terms of the Creative Commons Attribution License, which permits unrestricted use, distribution, and reproduction in any medium, provided the original author and source are credited.

ataxia were apparent, and the patient's condition was similar to that of akinetic mutism. Thyrotropin-releasing hormone (TRH) is clinically used as a treatment for disturbed consciousness [4]. Hence, TRH therapy (Protirelin [2 mg/day] intravenously administered once per day) was recommended. Potential adverse events were explained to the patient's family members as TRH was to be used as an off-label treatment. After obtaining the family's consent, treatment was initiated 42 days after CO exposure. Slight improvements in spontaneity and responsiveness were observed the same day. Although the patient required assistance, he was gradually able to consume all of his meals. The patient's prosopagnosia began to improve 57 days after CO exposure, and the patient began to perform actions unaided, such as using the toilet, and could have simple conversations. Sixty-five days after CO exposure, the patient participated in conversations with family members, with improved ability to express emotions, such as via smiling and crying. The patient was also able to follow commands.

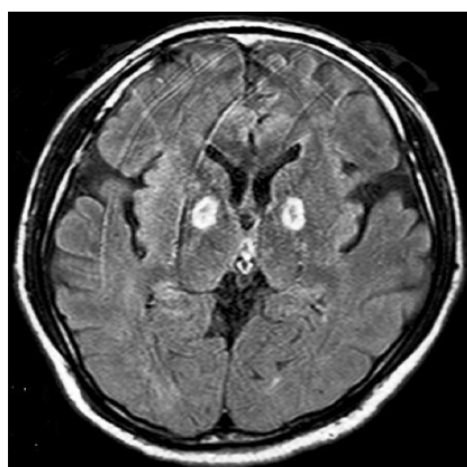
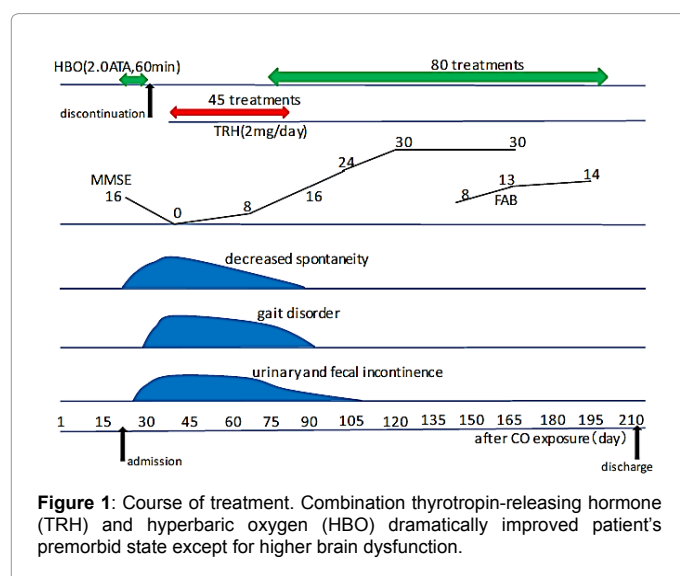
Following discussion with the HBO chamber operator and approval, HBO therapy was resumed 74 days after CO exposure. TRH

and HBO therapies were concomitantly performed in with the view of further improved efficacy. Eighty-two days after CO exposure, marked improvement in ataxia was apparent, and the patient could walk short distances without assistance. Eighty-five days after CO exposure, treatment was temporarily discontinued because of insomnia and night time wandering, possibly due to TRH therapy-induced hyperarousal. Symptoms were ameliorated after the initiation of hypnosis therapy. Peripheral thyroid hormone (T3 and T4) levels in the patient were within normal limits before and after TRH treatment.

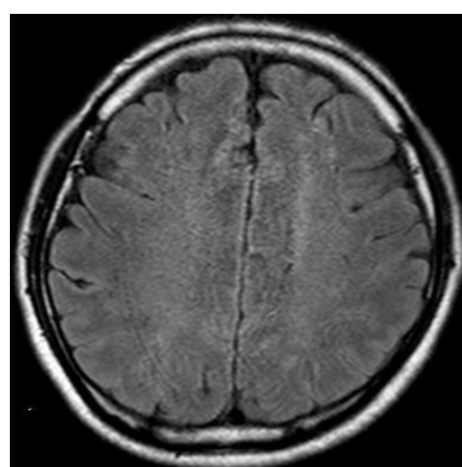
One-hundred and twenty-four days after CO exposure, the patient obtained the maximal MMSE score, 30 out of 30 points, indicating normal cognition, and normal EEG findings, with basic waves of approximately 10 Hz. One-hundred and forty-five days after CO exposure, brain MRI showed a bilateral reduction of the hyperintense regions of the globus pallidus and mild cerebral atrophy. Moreover, MRI showed subsequent exacerbation of white matter lesions especially in the frontal lobe (Figure 3). Since the patient's MMSE score was already at maximum, the frontal assessment battery (FAB) was used to assess frontal lobe function. It was determined that higher-brain dysfunction persisted after an evaluation of frontal lobe function using the FAB. The patient's FAB score was 8 points, out of 18 points, indicating decreased in frontal lobe function. Therefore, HBO therapy was continued. The patient's FAB scores 198 days after CO exposure, 13 to 14 points, suggested mild amelioration of dysfunction. HBO therapy was concluded after 80 treatment sessions, since it was determined that no further therapeutic benefit was observed, and the patient was discharged. The patient and his family members were informed that although there were currently no problems in performing daily activities, there was a possibility that higher-brain dysfunction could persist due to functional abnormalities in the frontal lobe. At the request of the patient and his family, the patient was referred to a behavioral and cognitive neurology department of another hospital for specialized treatment.

Discussion

TRH is used clinically for the treatment of spinocerebellar degeneration and disturbance of consciousness [4]. There are no reports in the clinical literature on the use of TRH on DNS after acute CO poisoning. On the day of TRH treatment, a positive behavioral



A



B

Figure 2: Transverse brain magnetic resonance imaging (MRI) findings 21 days after CO exposure. MRI performed on admission. Hyperintense signal approximately 1 cm in diameter observed bilaterally in globus pallidus (A). A minor amount of hyperintense signal observed in deep white matter (A) (B).

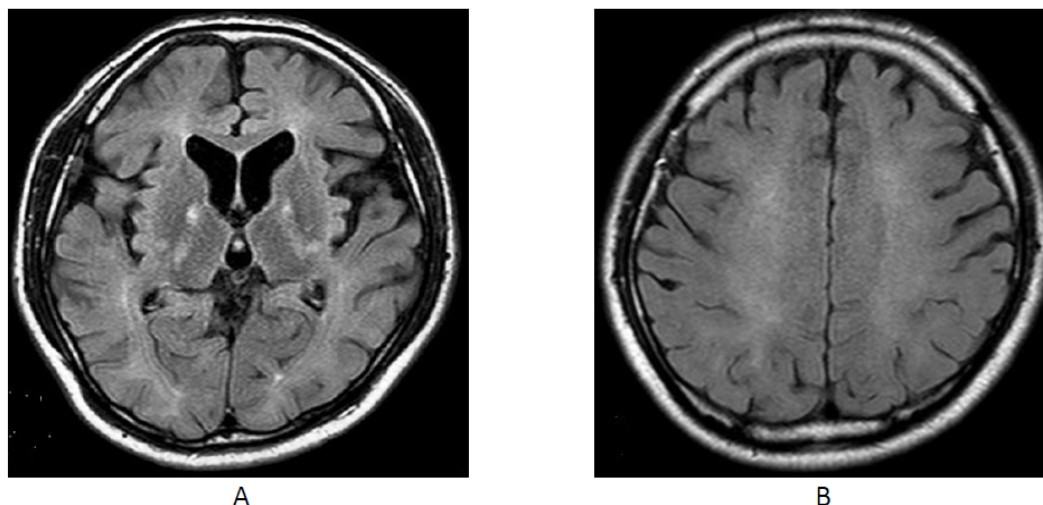


Figure 3: Transverse brain MRI findings 145 days after CO exposure. Hyperintense region in bilateral globus pallidus greatly reduced and mild cerebral atrophy was revealed (A). Moreover, it showed subsequent exacerbation in the white matter lesion especially in the frontal lobe (A) (B).

effect was observed despite the fact that TRH was administered 42 days after CO exposure. In particular, return of spontaneity, general responsiveness, and motor function was observed first, followed by an improvement of cognitive function, enabling the reinitiation of HBO therapy. Preclinical animal studies suggest that TRH stimulates motor activity [5,6]. TRH has also shown to promote wakefulness and to induce arousal from hibernation. A possible mechanism of TRH's effect on arousal could be via the hypocretin/orexin system [7] and the excitatory effect of orexin could contribute to TRH's arousal-enhancing effect [8].

In the present case, TRH therapy led to the rapid improvement of spontaneity, motor function, and arousal. The primary therapeutic effect of HBO therapy is the amelioration of frontal lobe cognitive dysfunction (Figure 1). Thus, a potential synergistic therapeutic effect could have occurred with the combination of TRH with HBO therapy. Peripheral thyroid hormone levels in the patient were within normal limits before and after TRH treatment. Therefore, the effect of TRH on DNS could be centrally rather than peripherally mediated. Potential adverse effects of TRH, such as insomnia, however, could limit widespread use of TRH for DNS following CO poisoning. There are currently no criteria concerning the frequency of HBO therapy that should be administered to DNS patients, as the procedure differs depending on the facility and patient. In the current case, the patient obtained the maximum MMSE score with the 60th HBO therapy session. In addition, there are currently no guidelines concerning the use of objective measures of brain structure and function, such as imaging and EEG, to determine the number HBO treatments that should be administered. Brain MRI performed in the present patient suggested functional abnormalities in the frontal lobe, which led to FAB evaluation of frontal lobe function. The current case designated the presence of a plateau, or no further improvement in the FAB score, as the target for the discontinuation of HBO therapy. Frequent brain imaging in standard clinical practice is highly challenging. Instead, simple brain function testing, such as using FAB corresponding to the specific site, maybe used to demonstrate recovery. Hence, the FAB could potentially be used as a criterion for either continuation or discontinuation of HBO therapy since therapeutic effects of HBO can be easily assessed using this outcome measure. Further studies of DNS patients are needed to validate such a measure as an indicator of continued HBO therapy.

Conclusion

The results of the present case demonstrated the efficacy of TRH therapy in a patient with DNS after acute CO poisoning in whom HBO therapy was difficult to perform due to psychiatric symptoms. It is possible that TRH could be used to reduce psychiatric symptoms in order to initiate or continue HBO therapy. Moreover, the current case study demonstrated that imaging and frontal lobe functional test findings could be used to indicate continuation of HBO therapy.

References

1. Weaver LK, Hopkins RO, Chan KJ, Churchill S, Elliott CG, et al. (2002) Hyperbaric oxygen for acute carbon monoxide poisoning. *N Engl J Med* 347: 1057-1067.
2. Thom SR, Taber RL, Mendiguren II, Clark JM, Hardy KR, et al. (1995) Delayed neuropsychologic sequelae after carbon monoxide poisoning: prevention by treatment with hyperbaric oxygen. *Ann Emerg Med* 25: 474-80.
3. Min SK (1986) A brain syndrome associated with delayed neuropsychiatric sequelae following acute carbon monoxide intoxication. *Acta Psychiatr Scand* 73: 80-86.
4. Meena CL, Thakur A, Nandekar PP, Sharma SS, Sangamwar AT, et al. (2016) Synthesis and biology of ring-modified L-histidine containing thyrotropin-releasing hormone (TRH) analogues. *Eur J Med Chem* 111: 72-83.
5. Masuo Y, Matsumoto Y, Morita S, Noguchi J (1997) A novel method for counting spontaneous motor activity in the rat brain. *Res Brain Res Protoc* 1: 321-326.
6. Faden AI, Fox GB, Fan L, Araldi GL, Qiao L, et al. (1999) Novel TRH analog improves motor and cognitive recovery after traumatic brain injury in rodents. *Am J Physiol* 277: R1196-204.
7. Hara J, Gerashchenko D, Wisor JP, Sakurai T, Xie X, et al. (2009) Thyrotropin-releasing hormone increases behavioral arousal through modulation of hypocretin/orexin neurons. *J Neurosci* 29: 3705-3714.
8. González JA, Horjales-Araujo E, Fugger L, Broberger C, Burdakov D (2009) Stimulation of orexin/hypocretin neurones by thyrotropin-releasing hormone. *J Physiol* 587: 1179-1186.