

Stenting of the Left Main Coronary Stenosis

Dipesh Pradhan*

Department of Internal Medicine (Cardiology), Norman Bethune College of Medicine, Jilin University, Changchun, China

Abstract

Acute myocardial infarction induced by left main coronary artery (LMCA) stenosis is the infrequent but fatal disease. LMCA stenosis occurs in 4-10% whereas lethal total occlusion of LMCA occurs in 0.04-0.42% of angiograms. We report the case of 52 years diabetic obese male with central chest pain for one week; electrocardiogram (ECG) shows ST elevation in leads aVR, V1-V4, and coronary angiography displays stenosis of LMCA (>80% occlusion). The high risk primary angioplasty with drug eluting stent was performed in the unprotected LMCA without any complications.

Keywords: Stenting; Left main coronary stenosis; Primary angioplasty; Electrocardiogram; Coronary angiography

Introduction

In most of the individuals, the common stem of left coronary artery is short. Left coronary artery has significant role in myocardial contractility as it supplies the left ventricular anterior wall, one third of the right ventricular free wall, the left and the right ventricular apex, a large part of the ventricular septum, and one half of the posterior wall [1]. Any critical stenosis or total occlusion of left main coronary artery results in rapid fatality and might causes grave complications like acute myocardial infarction, ventricular fibrillation, heart failure, cardiogenic shock or death [2-4]. The total occlusion of LMCA is very rare around 0.04-0.42% whereas stenosis of LMCA is frequent with 4-10% of total angiograms [4]. Here we discuss the stenosis of LMCA which undergoes successful primary angioplasty with drug eluting stent without any complications.

Case Report

A 52 years diabetic obese male (BMI 31 kg/m²) came to the emergency department with a complaint of intermittent central chest pain with increase in frequency and duration for last one week. He has been smoking for last 20 years with 1 pack per day (20 pack years). He occasionally consumed alcohol. His father died due to acute myocardial infarction at the age of 50 years. He is taking metformin 500 mg two times day for last 10 years. He is not taking any medication for ischemic heart disease. On examination, the patient looked anxious, with pulse 110/min regular and blood pressure of 140/86 mm Hg. The jugular venous pressure and carotid pulse were normal. The auscultation of heart and lung detected no abnormalities. Standard 12 leads electrocardiogram showed ST elevation in aVR (>0.05 mv) and V1-V4 (>0.2 mv), pathological Q wave in leads V1-V4 and ST depression in inferior leads (II, III and aVF) as shown in (Figure 1). The cardiac enzymes were elevated with Myoglobin (157.0 ng/ml), Troponin I (14.10 ng/ml) and CK-MB (37.70 ng/ml). Chest X-ray revealed no abnormalities. The blood creatinine was 0.8 mg/dl. The echocardiography revealed normal ejection fraction (EF 55%) without any regional wall motion abnormalities. Oxygen, aspirin (150 mg), sublingual nitroglycerine (5 mg), clopidogrel (150 mg), morphine (15 mg PO), Enalapril (5 mg) and metoprolol (50 mg) were given to the patient. The quantitative coronary angiography (QCA) was performed which revealed stenosis of left main coronary artery (>80%) as shown in figure 2. An abciximab (0.25 mg/kg IV bolus followed by 0.125 mg/kg intravenous continuous infusion for 18 hour concluding 1 hour post primary angioplasty) and intravenous heparin (5000 IU) were given.

The left main coronary artery was intubated with a 6 Frech Judkins left guide catheter with side hole and the lesion of left main coronary artery was crossed with a 0.014 inch sport coronary guidewire. The lesion of LMCA was dilated with 2.5 × 20 mm Raptor balloon at 6 atmospheric pressure. A 3.5 × 8 mm cypher stent was inserted into the left main stem at 14 atmospheric pressure with good results. After the procedure, the dye was injected which showed patency of left main stem with no residual stenosis or complications as shown in figure 3. The ST elevation on the ECG had reverted back to normal with normal cardiac enzymes with Troponin (2 ng/ml) and CK MB (3.3 ng/ml). The patient came for follow up after 6 weeks. The angiography was done which showed patency of LMCA with no complications. The patient was advised to continue clopidogrel (75 mg) for 1 year along with lifelong aspirin (75 mg), enalapril (5 mg), metoprolol (50 mg twice daily) and statin (40 mg daily).

Discussion

ST elevation myocardial infarction due to LMCA occlusion causes large regions in the jeopardy mainly the left ventricle. The patient may presents with massive myocardial infarction, ventricular arrhythmia or pump failure. The mortality is very high if LMCA occlusion is associated with cardiogenic shock [2,3]. According to the classification of coronary artery predominance, there are three types of arterial distribution: type I has RCA dominant (48%), type II has combined RCA and LCA dominant (34%) and type III has LCA dominant (18%). The survival after LMCA is dependent upon the rate of occlusion and development of right to left collateral flow as seen in type I or type II arterial distribution [5,6]. The ECG is easy and rapid way of detecting AMI. It shows ST elevation in lead aVR, V1-V4; ST elevation in aVR>V1, and widespread horizontal ST depression in inferior leads, V4-V6. These ECG findings reflect an acute MI due to LMCA occlusion or triple vessels disease [7-9].

The treatment options for acute LMCA occlusion include either

*Corresponding author: Dipesh Pradhan, Department of Internal Medicine (Cardiology), Norman Bethune College of Medicine, Jilin University, Changchun 130021, Jilin, PR China, Tel: + 8613596462752; Fax: +8685633300; E-mail: drdipesh.pradhan@gmail.com

Received March 18, 2013; Accepted April 27, 2013; Published May 06, 2013

Citation: Pradhan D (2013) Stenting of the Left Main Coronary Stenosis. J Cardiovasc Dis Diagn 1: 107. doi:10.4172/2329-9517.1000107

Copyright: © 2013 Pradhan D. This is an open-access article distributed under the terms of the Creative Commons Attribution License, which permits unrestricted use, distribution, and reproduction in any medium, provided the original author and source are credited.

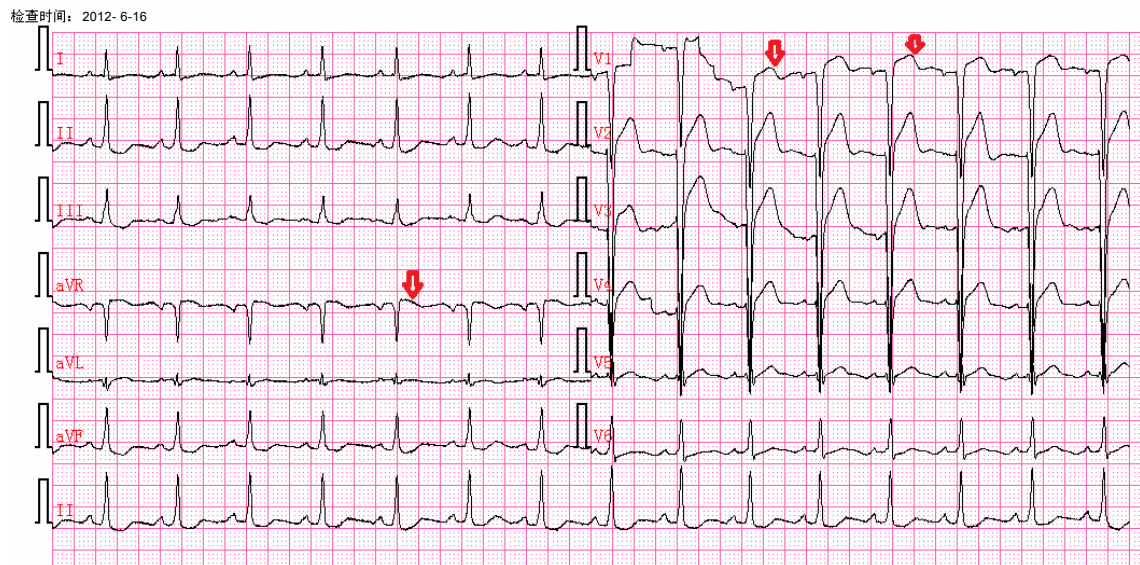


Figure 1: ECG showing 0.05 mm ST elevation in a VR and 2 mm ST elevation in V1-V4 (arrow), Q wave in V1-V4; ST depression in II, III and aVF.

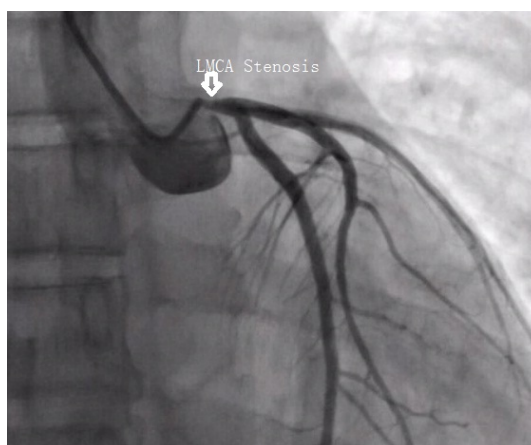


Figure 2: Coronary angiography showing stenosis of left main coronary artery (>80%).

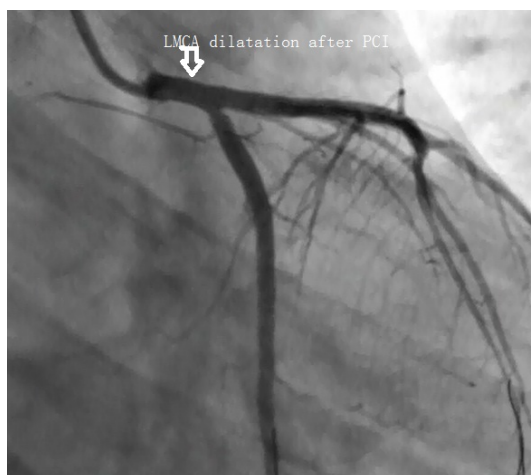

Figure 3: Coronary angiography following primary angioplasty with drug eluting stent shows normal flow in the left main coronary artery (arrow).

emergency percutaneous coronary intervention (PCI) or CABG. Now PCI for left main is generally accepted in worldwide [10-12]. Spiecker et al. and Fabbicchi et al. supported the use of emergency stent placement as the quickest and the most effective way to achieve reperfusion in the critically ill patients. But they concluded that the surgical revascularization was the definitive therapy for LMCA occlusion especially for diabetic patients because PCI with stent was associated with risk of subacute stent thrombosis and late in stent restenosis [6,12]. The CABG provides revascularization for all areas involved but the time delay, major surgical procedure, post surgical pain and discomfort, wound infection; long hospital stay and logistics make this option less suitable [4]. The use of glycoprotein IIb/IIIa inhibitors, drug eluting stent and dual antiplatelet agents have been found to cause marked reduction of sub acute stent thrombosis and restenosis. Bush and coworkers support the use of PCI with drug eluting stent as the definitive revascularization strategy for many patients with acute LMCA occlusion like our cases above [13].

In the summary; acute LMCA occlusion is a rare and serious condition. The specific ECG findings like horizontal ST depression in lead V4-V6 along with ST elevation in aVR and V1 is associated with left main or severe triple vessels disease. PCI with drug eluting stent is now globally accepted procedure for left main disease like our case above.

References

1. Baroldi G, Scomazzoni G (1967) Coronary circulation in the normal and the pathologic heart. Washington (DC)7 Armed forces institute of pathology
2. Iwasaki K, Kusachi S, Hina K, Nishiyama O, Kondo J, et al. (1993) Acute left main coronary artery obstruction with myocardial infarction--reperfusion strategies, and the clinical and angiographic outcome. *Jpn Circ J* 57: 891-897.
3. Quigley RL, Milano CA, Smith LR, White WD, Rankin JS, et al. (1993) Prognosis and management of anterolateral myocardial infarction in patients with severe left main disease and cardiogenic shock. The left main shock syndrome. *Circulation* 88: 1165-70.
4. Lijoi A, Della Rovere F, Passerone GC, Dottori V, Scarano F, et al. (1993) Emergency surgical treatment for total left main coronary artery occlusion. A report of 2 cases. *Tex Heart Inst J* 20: 55-58.
5. Reig J, Jornet A, Petit M (1993) Patterns of the coronary artery irrigation in the left ventricle. *Surg Radiol Anat* 15: 309-314.
6. Spiecker M, Erbel R, Rupprecht HJ, Meyer J (1994) Emergency angioplasty of totally occluded left main coronary artery in acute myocardial infarction and unstable angina pectoris--institutional experience and literature review. *Eur Heart J* 15: 602-607.
7. Rostoff P, Piwowarska W (2006) ST segment elevation in lead aVR and coronary artery lesions in patients with acute coronary syndrome. *Kardiol Pol* 64: 8-14.
8. Yan AT, Yan RT, Kennelly BM, Anderson FA Jr, Budaj A, et al. (2007) Relationship of ST elevation in lead aVR with angiographic findings and outcome in non-ST elevation acute coronary syndromes. *Am Heart J* 154: 71-78.
9. Kurisu S, Inoue I, Kawagoe T, Ishihara M, Shimatani Y, et al. (2004) Electrocardiographic features in patients with acute myocardial infarction associated with left main coronary artery occlusion. *Heart* 90: 1059-1060.
10. Koray Aykut, Coskun Ozdemir, Yusuf Altinkaynak (2012) Uncal treatment of chronic total occlusion of the left main coronary artery: a case report. *Turkish Journal of thoracic and cardiovascular surgery* 20: 352-354
11. Itoh T, Fukami K, Oriso S, Umemura J, Nakajima J, et al. (1997) Survival following cardiogenic shock caused by acute left main coronary artery total occlusion. A case report and review of the literature. *Angiology* 48: 163-171.
12. Fabbicchi F, Trabattoni D, Galli S, Bartorelli AL (1999) Emergency stenting of totally occluded left main coronary artery in acute myocardial infarction. *J Invasive Cardiol* 11: 309-312.
13. Bush HS, Strong DE, Novaro GM (2005) Successful use of sirolimus-eluting stents for treatment of ST-elevation acute myocardial infarction caused by left main coronary artery occlusion. *Tex Heart Inst J* 32: 421-423.