

# Spontaneous Rupture of Liver Haemangioma: A Case Report & Review of Literature

Shariful Islam\* and Vijay Naraynsingh

M.B.B.S., Post Graduate Resident, D.M., General Surgery, St. Augustine Campus, UWI, Trinidad & Tobago

## Abstract

Hepatic haemangioma is a most common benign tumour of the liver. Detected incidentally, often asymptomatic and undergoes enlargement in <10% of cases. Spontaneous rupture of a giant hepatic haemangioma (diameter >4 cm) with hemo-peritoneum occurs very rarely. Limited numbers of cases are reported in the world literature with an operative mortality of >35%. We report here a case of spontaneously ruptured hepatic hemangioma managed conservatively.

**Keywords:** Hepatic hemangioma; Spontaneous rupture

## Case Report

A 31yrs old female patient presented with three day history of sudden right upper quadrant pain which progressively worsened over the last 24 hours. She is a known asthmatic controlled by Nasacort inhaler and also a known case of polycystic ovary diseases using oral contraceptive pills over the last 9 years.

On physical examination revealed a young female in mild painful distress. Her mucous membrane was pink and moist. She was warm to touch with a temperature of 38.4°C and her vitals were within normal limit. Abdominal examination revealed moderate tenderness in right upper quadrant with mild guarding but no rebound tenderness. An USS of abdomen revealed a normal gall bladder with no peri-cholecystic fluids or gall stones with a normal CBD. However, a 7.77 x 9.42 cm cystic mass was noted in right lobe of liver and there was no free fluid (Figure 1). A CXR revealed right basal consolidation. Her WBC was elevated 26.2 and she was also anaemic with an Hb of 11 mg/dl. Her renal function as well as electrolytes were within normal limit, however her liver enzymes were elevated AST-600, ALT-1900, ALP-238, GGT-166 with normal serum bilirubin and amylase level.

After 24 hours her pain became severe and she became tachycardic with a pulse of 130 bpm with persistently elevated temperature (38.0°C). Her blood pressure and Spo<sub>2</sub> was normal. There was decreased air entry at right lung base. Abdominal examination revealed marked tenderness with guarding but no rebound tenderness and there was sluggish bowel sound. Patient Hb had dropped from 10 gm/dl to 8 gm/dl. An Urgent CT scan of abdomen and pelvis with intravenous contrast revealed that the cyst (haemangioma) has ruptured with free fluid (blood) in Morrison pouch and in right Para-colic gutter (Figure 2). Subsequently patient developed moderate respiratory distress and was reviewed by medicine specialist. A Spiral CT of the chest-revealed mild right pleural effusion with fluid in oblique fissure but no evidence of pulmonary embolism. An MRI of abdomen was also performed which reconfirm the ruptured hepatic haemangioma. Patient was admitted in HDU and was managed successfully and discharged home on day-12. Patient had a high ESR of 39 and her liver function test became normal. Her serum alpha fetoprotein, CEA, Ca 19-9, anti-nuclear DNA levels were within normal limit.

## Discussion

Hemangioma is the most common benign tumour affecting the liver [1,2]. Hepatic haemangioma are mesenchymal in origin and usually are solitary. Haemangioma are composed of masses of blood

vessels that are atypical or irregular in arrangement and size. Exact aetiology remains unknown [3-5].

Several pharmacologic agents have been postulated to promote tumour growth. Steroid therapy [6], oestrogen therapy, and pregnancy [7,8] can increase the size of an already existing hemangioma. Our patient was on inhalational steroid therapy for her asthmatic condition and was also on oral contraceptive pills for her polycystic ovarian disease.

Incidence rate 2% in USA & the prevalence rate at necropsy is 7.4%, usually see in multipara women, more female predominance and occur most frequently at age 30-50 years [1,2]. Our patient is 31years old and she has no children.

Hepatic haemangioma can occur as part of well-defined clinical syndromes. In Klippel-Trenaunay-Weber syndrome. In Kasabach-

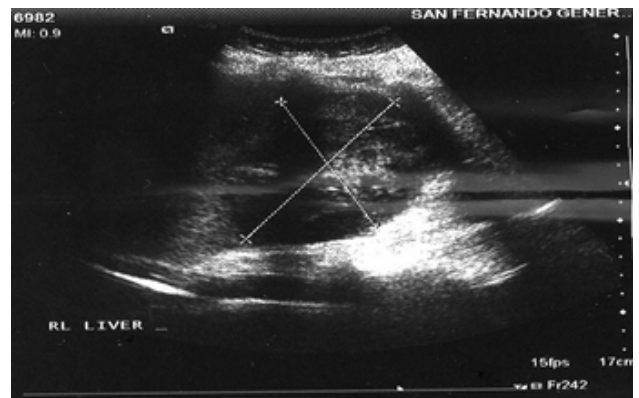


Figure 1: USS of abdomen: 7.7 x 9.4 cm cystic mass in Right lobe of liver.

\*Corresponding author: Shariful Islam, M.B.B.S., Post Graduate Resident, D.M., General Surgery, St. Augustine Campus, UWI, Trinidad & Tobago, Tel: 868-797-4951; Fax: 868-797-4951; E-mail: [shar\\_islam7@hotmail.com](mailto:shar_islam7@hotmail.com)

Received June 14, 2014 ; Accepted June 24, 2014; Published July 04, 2014

Citation: Islam S, Naraynsingh V. Spontaneous Rupture of Liver Haemangioma—A Case Report & Review of Literature. Journal of Surgery [Jurnalul de chirurgie] 2014; 10(2): 199-201 DOI: [10.7438/1584-9341-10-2-20](https://doi.org/10.7438/1584-9341-10-2-20)

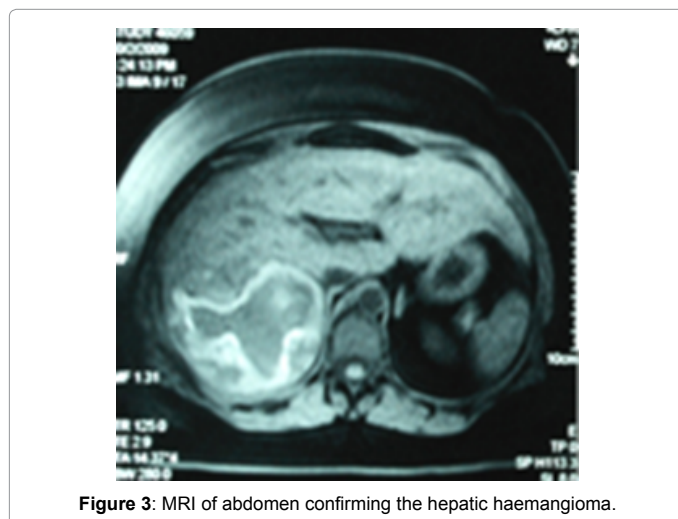
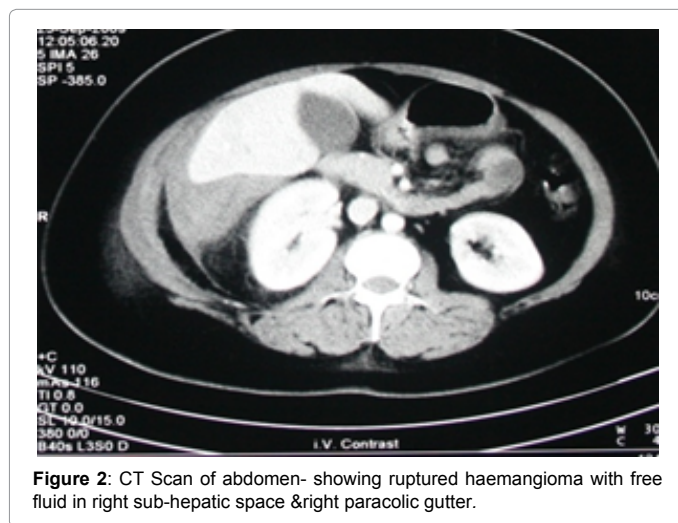
Copyright: © 2014 Islam S, et al. This is an open-access article distributed under the terms of the Creative Commons Attribution License, which permits unrestricted use, distribution, and reproduction in any medium, provided the original author and source are credited.

Merritt syndrome, Osler-Rendu-Weber disease, Von Hippel -Lindau disease, multiple hepatic haemangioma [9] have been reported in patients with systemic lupus erythematosus. Suzuki T, Tsuchiya N, Ito K. Multiple cavernous haemangioma of the liver in patients with systemic lupus erythematosus.

Haemangioma are more common in the right lobe of the liver, usually small and asymptomatic can be larger and multiple usually presents as Right upper quadrant pain or fullness, may presents as an enlarged liver or the presence of an arterial bruit over the right upper quadrant. Rarely, haemangioma may present as a large abdominal mass or other atypical presentations like 1) cardiac failure from massive arterio-venous shunting [10], 2) jaundice from compression of the bile ducts, 3) gastrointestinal bleeding from hemobilia [11] and 4) fever of unknown origin (12).

An illness that resembles a systematic inflammatory process has been described with findings of fever, weight loss, anaemia, thrombocytosis, increased fibrinogen level, and elevated erythrocyte sedimentation rate. Our patient presents with RUQ pain & fever, with elevated WBC, ESR, low Hb and she was not icteric and auscultation revealed no arterial bruit.

Large tumours very rarely rupture spontaneously. Patients may present with signs of circulatory shock and hemo-peritoneum [12,13]. Our patient initially present as an un ruptured hepatic haemangioma as confirmed by initial USS (Figure 1) and spontaneously ruptured on day -1 of admission without any history of trauma and confirmed radiologically by CT scan & MRI (Figures 2 and 3).



Routine laboratory tests - are usually normal. There could be thrombocytopenia or hypo-fibrinogenemia. Normal alpha-fetoprotein, CA 19-9, and carcinogenic embryonic antigen (CEA) levels bolster clinical suspicion of a benign hepatic mass lesion. Serum alpha fetoprotein, CA-19-9, CEA levels were normal in our patient.

Modalities used to diagnose it are Ultrasonography (US) 46% sensitivity [3], Dynamic contrast-enhanced computed tomography (CT) 66% sensitivity [14,15], Nuclear medicine studies using technetium (Tc) 99m-labeled RBCs [16,17], Magnetic resonance imaging (MRI) 96% sensitivity [17,18], Hepatic arteriography, and Digital subtraction angiography (DSA). Liver biopsy can help provide an unequivocal histologic diagnosis. Ultra-sonogram as well as CT and MRI were used in our case for diagnosis.

Most hepatic haemangioma are small and asymptomatic at the time of diagnosis, and they are likely to remain that way. Hence long term follow up radiograph probably not necessary providing that no change in haemangioma size has occurred. Finally, patients with large haemangioma (i. e. >10 cm) may deserve long-term follow-up radiologic studies, perhaps annually, because of their probable increased risk of complications [1, 6,8,19].

The management of a large (i. e. >10 cm) hepatic haemangioma is controversial. However, a literature search identified only 32 published cases of spontaneous rupture in adults without a history of trauma [1,6,8,12,15,19-30]. However, actual radiological documented before and after ruptured are not well documented. In our case we have radiological evidence before and after rupture of the haemangioma.

Treatment option includes surgical resection [8,17,27,31-33] surgical enucleation, arterial embolization [7,8,15,18,27,34,35], radiofrequency ablation, hepatic irradiation, and orthotopic liver transplantation. However surgical resection and enucleation are the treatments of choice. It has been reported that patient with hemo-peritoneum who underwent surgical intervention the mortality rate was 36.4% [1]. In rare instances, once patient remained hemodynamically stable can be managed conservatively like ours. Patient are usually followed up with serial ultrasound. Our patient was followed up with serial USS and after two years of follow up there was no increase in size and she remained asymptomatic throughout her follow up.

## Conclusion

Although hepatic haemangioma is common, however spontaneous ruptures are very rare and associated with a very high mortality rate. High index of suspicion should be kept for prompt diagnosis of this rupture. Early intervention should be taken to prevent a fatal outcome.

## Conflict of interest

The authors have no conflict of interest to report.

## Acknowledgement

Patient's consent is obtained for publication of this case report.

## References

- Jangjoo A, Mehrabi Bahar M, Aliakbarian M (2010) Ruptured giant hepatic hemangioma: report of a case. *Acta Med Iran* 48: 419-422.
- Hobbs KE (1990) Hepatic hemangiomas. *World J Surg* 14: 468-471.
- Chen ZY, Qi QH, Dong ZL (2002) Etiology and management of hemorrhage in spontaneous liver rupture: a report of 70 cases. *World J Gastroenterol* 8: 1063-1066.
- Drigo P, Battistella PA, Mammi I (1995) Familial cerebral, hepatic, and retinal cavernous angiomas. *Childs Nerv Syst* ;11: 65
- Lamy B, Jourdan C, Leclerc R, Convert J, Deschamps J et al. (1990) Blood coagulation disorders in intra-cerebral hematoma caused by rupture of intracranial angioma. Incidences on haemorrhagic recurrence 31: 409-411.
- Santos Rodrigues AL, Silva Santana AC, Carvalho Araújo K, Crociati Meguins

- L, Felgueiras Rolo D, et al. (2010) Spontaneous rupture of giant hepatic hemangioma: a rare source of hemoperitoneum. Case report. *G Chir* 31: 83-85.
7. Graham E, Cohen AW, Soulen M, Faye R (1993) Symptomatic liver hemangioma with intra-tumor hemorrhage treated by angiography and embolization during pregnancy. *Obstet Gynecol* 81: 813-816.
  8. Jain V, Ramachandran V, Garg R, Pal S, Gamanagatti SR, et al. (2010) Spontaneous rupture of a giant hepatic hemangioma - sequential management with transcatheter arterial embolization and resection. *Saudi J Gastroenterol* 16: 116-119.
  9. Leal N, López Santamaría M, Gámez M, Murcia J, López Gutiérrez JC, et al. (2004) [The multifocal hepatic hemangioendothelioma. Is always a benign tumor?]. *Cir Pediatr* 17: 8-11.
  10. Shimada M, Matsumata T, Ikeda Y, Urata K, Hayashi H, et al. (1994) Multiple hepatic hemangiomas with significant arterioportal venous shunting. *Cancer* 73: 304-307.
  11. Colli A, Fraquelli M, Massironi S, Colucci A, Paggi S, et al. (2007) Elective surgery for benign liver tumours. *Cochrane Database Syst Rev*: CD005164.
  12. Griffa B, Basilico V, Bellotti R, Griffa A, Senatore S, et al. (2005) [Spontaneous rupture of giant subcapsular hemangioma of the liver with hemoperitoneum and hemorrhagic shock: a case report]. *Chir Ital* 57: 389-392.
  13. Corigliano N, Mercantini P, Amodio PM, Balducci G, Caterino S, et al. (2003) Hemoperitoneum from a spontaneous rupture of a giant hemangioma of the liver: report of a case. *Surg Today* 33: 459-463.
  14. Lee HF, Lu CL, Chang FY (2010) Electronic clinical challenges and images in GI. Multiple hepatic tumors with hemoperitoneum. *Gastroenterology* 138: e3-4.
  15. Ikeda K, Maehara M, Ohmura N, Kurokawa H, Koda K, et al. (2006) Spontaneous rupture of a necrotic hepatic angiosarcoma: findings on dual-phase computed tomography and angiography. *Radiat Med* 24: 369-372.
  16. Dwamena BA, Belcher KK, Dasika N, Frey KA (1997) Focal hyperemia on RBC blood-flow imaging. A scintigraphic marker of arterioportal venous shunting in hepatic cavernous hemangiomas? *Clin Nucl Med* 22: 542-545.
  17. Samuel M, Spitz L (1995) Infantile hepatic hemangioendothelioma: the role of surgery. *J Pediatr Surg* 30: 1425-1429.
  18. JesiÄ R, RadojkoviÄ S, TomiÄ D, KrstiÄ M, JankoviÄ G, et al. (1998) [Personal experience in embolization of liver hemangiomas]. *Srp Arh Celok Lek* 126: 349-354.
  19. Scribano E, Loria G, Ascenti G, Vallone A, Gaeta M (1996) Spontaneous hemoperitoneum from a giant multicystic hemangioma of the liver: a case report. *Abdom Imaging* 21: 418-419.
  20. Jr MA, Papaiordanou F, Gonçalves JM, Chaib E (2010) Spontaneous rupture of hepatic hemangiomas: A review of the literature. *World J Hepatol* 2: 428-433.
  21. Kim GH, Kim YS, Kim HO, Kim KH, Hung YK, et al. (2009) [A case of primary hepatic epithelioid hemangioendothelioma with spontaneous rupture]. *Korean J Hepatol* 15: 510-516.
  22. Shimoji K, Shiraishi R, Kuwatsuru A, Maehara T, Matsumoto T, et al. (2004) Spontaneous subacute intratumoral hemorrhage of hepatic cavernous hemangioma. *Abdom Imaging* 29: 443-445.
  23. Corigliano N, Mercantini P, Amodio PM, Balducci G, Caterino S, et al. (2003) Hemoperitoneum from a spontaneous rupture of a giant hemangioma of the liver: report of a case. *Surg Today* 33: 459-463.
  24. Kleespies A, Settmacher U, Neuhaus P (2002) [Spontaneous rupture of hepatic focal nodular hyperplasia--a rare cause of acute intraabdominal bleeding]. *Zentralbl Chir* 127: 326-328.
  25. Cozzi PJ, Morris DL (1996) Two cases of spontaneous liver rupture and literature review. *HPB Surg* 9: 257-260.
  26. Mazziotti A, Jovine E, Grazi GL, Pierangeli F, Gozzetti G (1995) Spontaneous subcapsular rupture of hepatic haemangioma. *Eur J Surg* 161: 687-689.
  27. Soyer P, Levesque M (1995) Haemoperitoneum due to spontaneous rupture of hepatic haemangiomas: treatment by super selective arterial embolization and partial hepatectomy. *Australas Radiol* 39: 90-92.
  28. Golfieri R, Minguzzi MT, Lalli A, Soro A, Totaro C, et al. (1994) [The spontaneous rupture of a hepatic cavernous hemangioma. A case report and review of the literature]. *Radiol Med* 88: 315-319.
  29. Torramadé J, Cienfuegos JA, Pardo F, Hernández JL, Benito C, et al. (1991) [Spontaneous rupture of a hepatic adenoma associated with hepatic peliosis]. *Rev Esp Enferm Dig* 80: 275-277.
  30. Lau WY, Dewar GA, Li AK (1989) Spontaneous rupture of hepatic epithelioid haemangio-endothelioma. *Aust N Z J Surg* 59: 972-974.
  31. Gourgiotis S, Moustafellos P, Zavos A, Dimopoulos N, Vericouki C, et al. (2006) Surgical treatment of hepatic haemangiomas: a 15-year experience. *ANZ J Surg* 76: 792-795.
  32. Iwatsuki S, Todo S, Starzl TE (1990) Excisional therapy for benign hepatic lesions. *Surg Gynecol Obstet* 171: 240-246.
  33. Andersson R, Bengmark S (1988) Surgical treatment of cavernous hemangioma of the liver. *Acta Chir Scand* 154: 577-579.
  34. Vassiou K, Rountas H, Liakou P, Arvanitis D, Fezoulidis I, et al. (2007) Embolization of a giant hepatic hemangioma prior to urgent liver resection. Case report and review of the literature. *Cardiovasc Intervent Radiol* 30: 800-802.
  35. Yamamoto T, Kawarada Y, Yano T, Noguchi T, Mizumoto R (1991) Spontaneous rupture of hemangioma of the liver: treatment with transcatheter hepatic arterial embolization. *Am J Gastroenterol* 86: 1645-1649.