

Spontaneous Osteonecrosis of the Medial Femoral Condyle: Case Report

Ovidiu Alexa^{1*}, Dan Cionca², Samir Albetar² and Bogdan Veliceasa¹

¹Department of orthopedics and traumatology, "Gr. T. Popa" University of Medicine and Pharmacy Iași, Romania

²Department of orthopedics and traumatology, "St. Spiridon" Emergency Hospital Iași, Romania

Abstract

Spontaneous osteonecrosis of the knee presents with acute onset of severe pain in elderly patients, usually females, without a history of trauma. Originally described as idiopathic osteonecrosis, the exact etiology is still debated. Evidence suggests that an acute fracture occurs as a result of chronic stress or minor trauma to a weakened subchondral bone plate. We report one case of spontaneous osteonecrosis of medial femoral condyle in a 71-year-old female with no evidence of trauma involving a 4 cm weight bearing surface. According to Koshino this case can be classified as stage II. Various types of treatment have been reported, including conservative treatment with physical exercise and non-steroidal anti-inflammatory drugs, arthroscopy alone, arthroscopy and drilling, valgus high tibial osteotomy, and total knee arthroplasty. Total knee arthroplasty was considered the appropriate management strategy in this case.

Keywords: Medial femoral condyle; Osteonecrosis; Bone infarction

Introduction

Spontaneous osteonecrosis of the knee (SONK), first described in 1968, has been thought to be a distinct type of osteonecrosis. The lesion occurs most commonly in women 60 years of age and older [1-3]. SONK is characterized by acute onset of knee pain and can be differentiated from secondary osteonecrosis, which occurs secondary to such factors as corticosteroid therapy, systemic disorders, alcoholism, and Caisson disease [4].

Although the exact etiology of SONK remains unknown, two theories have been proposed: vascular insufficiency and trauma [1,2,5,6]. In a recent study, the primary pathology of SONK was demonstrated to be a subchondral insufficiency fracture and, in some cases, focal osteonecrosis confined the area between the fracture line and the articular surface [7].

The lesions can be classified into four stages according to Koshino's radiographic classification: stage I, no abnormalities on radiographs, stage II, a radiolucent oval area in the subchondral region or flattening of the medial femoral condyle (MFC), stage III, expansion of the radiolucent area with a sclerotic halo, and stage IV, secondary degenerative changes including osteophytes and osteosclerosis on both the tibial and femoral sides [8].

Various types of treatment have been reported including conservative treatment with physical exercise and non-steroidal anti-inflammatory drugs (NSAIDs), arthroscopy alone, arthroscopy and drilling, valgus high tibial osteotomy, and total knee arthroplasty [9,10].

Case Report

We report a case of spontaneous osteonecrosis of the knee investigated radiologically (X-ray and MRI) and arthroscopically.

A 71-year-old woman complaining of severe knee pain in the absence of a history of significant trauma and not responding to NSAIDs and physiotherapy was referred to our clinic in September 2013. Palpation of the medial femoral condyle elicited pain and a mild knee effusion was present. There was no varus or valgus malalignment.

Plain x-rays showed an osteolytic lesion in the weight bearing area of the medial femoral condyle with no sclerotic delimitations or articular degenerative changes (Figure 1).

Magnetic resonance imaging (MRI) showed a high intensity

subchondral area in the weight bearing surface of medial femoral condyle surrounded by low signal intensity in the femoral condyle with undulating hypointense lines demarcating bone infarction (Figure 2).

Based on the diagnosis of stage 3 spontaneous osteonecrosis of the medial femoral condyle, arthroscopy was performed under spinal anesthesia in October 2013.

A partially detached fragment of articular cartilage with a 4 cm lesion on the weight-bearing area of the medial condyle which was excised and the other unstable small fragments and coexisting degenerative lesion of medial meniscus posterior horn were debrided (Figure 3). No other intraarticular injuries were identified.

Discussion

It is well known that the clinical course of this disease varies from remission with conservative treatment to severe dysfunction requiring surgical treatment [11].

The early form of SONK in middle aged patients usually resolves without surgical intervention. Yates et al. [12] have reported MRI prognostic criteria that indicate a benign course in the absence of a focal depression of the epiphyseal lining and the absence of deep, low signal intensity lines on the condyles. However, in the advanced stage of this condition some patients need surgical treatment. Locouvet et al. [13] concluded that initial MRI imaging characteristics indicative of an early irreversible osteonecrosis included a subchondral area of low signal intensity on T2-weighted images with a thickness of more than 4 mm or a length of more than 14 mm, focal epiphyseal contour depressions, and lines of low signal intensity located deep in the affected condyle.

***Corresponding author:** Ovidiu Alexa, MD, PhD, Department of Orthopedics and Traumatology, "St. Spiridon", Emergency Hospital Iași, Independenței Street No 1, 700111, Iași, Romania, Tel: +40 (0) 722 45 80 78; E-mail: ccorinaradu@yahoo.com

Received September 25, 2014; **Accepted** October 30, 2014; **Published** November 05, 2014

Citation: Alexa O, Cionca D, Albetar S, Veliceasa B. Spontaneous Osteonecrosis of the Medial Femoral Condyle: Case Report. Journal of Surgery [Jurnalul de chirurgie] 2015; 10(4): 291-293 DOI:[10.7438/1584-9341-10-4-10](https://doi.org/10.7438/1584-9341-10-4-10)

Copyright: © 2015 Alexa O, et al. This is an open-access article distributed under the terms of the Creative Commons Attribution License, which permits unrestricted use, distribution, and reproduction in any medium, provided the original author and source are credited.

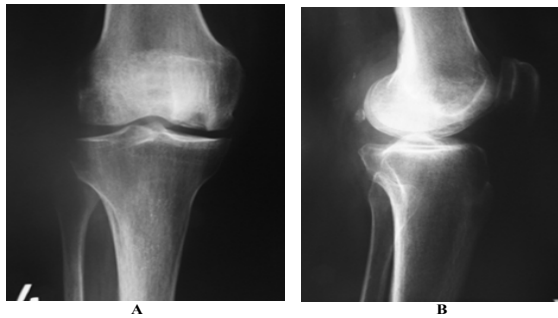


Figure 1: Knee X-ray (A: Antero-Posterior View, B: Lateral View): Osteolytic Lesion of Medial Femoral Condyle.

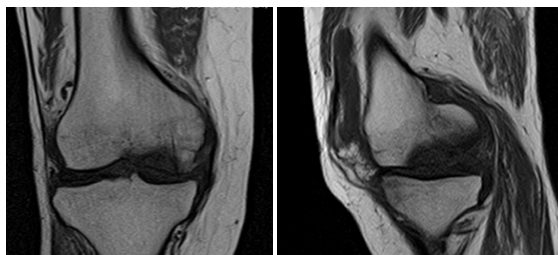


Figure 2: Knee MRI: Bone Infarction in the Medial Femoral Condyle.

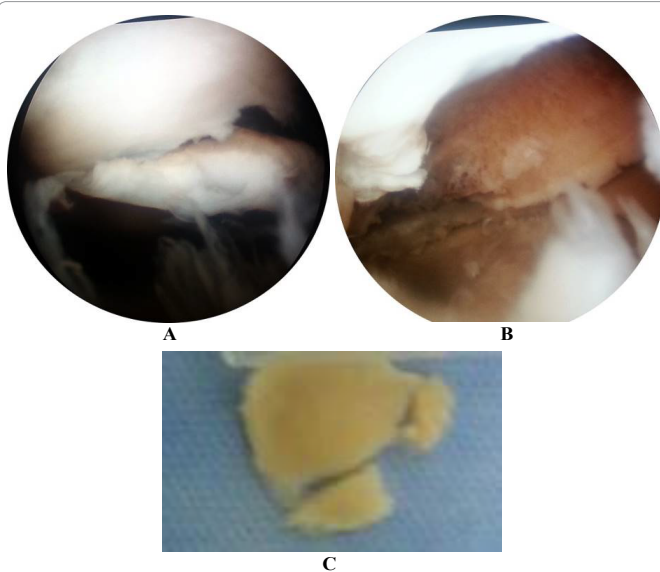


Figure 3: A&B: Operative Arthroscopic Images; C: Detached Articular Cartilage Fragment.

In stage II or higher stages when these radiographic findings are visible on X-rays, the clinical course and prognosis were reported to depend on the radiographic size of the lesion. Some authors reported that when a more than 50% of the occupied ratio of the lesion, and more than 5 cm square of the lesion area, the patient had a poor clinical and radiographic prognosis with rapid development of osteoarthritis and surgical treatment was recommended [14,15].

In the early stage of the disease, the non-operative treatment is indicated, and many patients, if diagnosed early, have a benign course with satisfactory pain relief and good knee function [15]. Conservative treatment is also supported by evidence that lack of immobilization and continued weight bearing could eventually result in further displacement, subchondral collapse and subsequent extension of necrosis.

Soucasos et al. [9], suggested that patients in stages 1 and 2 be treated by conservative management and in stages 3 and 4 be treated by surgery according to the size of the lesion. Lotke et al. [11], suggested that surgical treatment should be considered when femoral condyle rate is over 50%. Aglietti et al. [2], suggested that prognosis is poor when femoral condyle rate is over 40% and the lesion is over 5 cm².

Koshino et al. [8] employed arthroscopy to evaluate knees with spontaneous osteonecrosis. They concluded that in the early stages of osteonecrosis, fissures and flattening of the articular cartilage, with or without formation of a cartilage flap, were useful findings in choosing intra-articular surgical procedures. Similarly, in the late stages the presence of loose bodies and regeneration of fibro-cartilaginous tissue over the necrotic lesion also helped in the selection of surgical intervention [16].

Core decompression by extra-articular drilling into the femoral condyle has been recommended as an effective treatment in the initial stages [17,18]. Akgun et al. [19] evaluated the microfracture technique and concluded that it is safe, simple, and cost-effective, and may be an alternative procedure for treatment of SONK, especially in young patients, before possible subsequent replacement surgery.

The best results are achieved with osteotomy combined with arthrotomy, or by knee replacement arthroplasty. If the stage of SONK is 3 or higher, the treatment of choice is arthroplasty [17]. Arthroplasties of the knee can be either total or unicompartmental. Reports have shown variable results of each method [14,20,21]. Marmor [22], obtained good clinical results in 30 cases of 34 patients who had unicompartmental knee arthroplasty. However, two patients got revision arthroplasty due to depression around where they had surgery and two patients got revision arthroplasty due to newly forming lesions in the lateral condyle of the femur. Radke et al. [21] reviewed 39 cases. Of these, 23 underwent unicompartmental knee arthroplasty and 16 total knee arthroplasty. With an average follow-up of more than 5 years, they reported better clinical outcomes in the patients who underwent total knee arthroplasty. In patients who underwent unicompartmental knee arthroplasty, four had a revision arthroplasty. However, they reported that the main causes of poor results of unicompartmental knee arthroplasty are inadequate operative technique and patient selection. Recently, good clinical results and high long-term survival rates of unicompartmental knee arthroplasty have been reported due to improvement of surgical technique, component design, and strict selection criteria [20,23].

Our case can be classified as Koshino stage II with no sclerosis halo but with a big defect-4 cm, 71-year-old patient, so we thought total knee arthroplasty to be the appropriate management method.

Conclusion

Osteonecrosis of the knee is a debilitating disease that is poorly understood. Typically, initial treatment involves nonsurgical measures, such as limited weightbearing, for small and medium lesions. Surgical options are used with large lesions. We need more prospective, randomized studies, which may be difficult to conduct due to the small number of patients. We need to maintain a high index of suspicion for these disorders because early diagnosis and treatment may allow for an improved clinical outcome. Continued study of patients with SONK is needed in an effort to identify specific risk factors that predispose certain patients to their development.

Conflict of interests

Authors have no conflict of interests to disclose.

References

- Ahlback S, Bauer GC, Bohne WH (1968) Spontaneous osteonecrosis of the knee. *Arthritis Rheum* 11: 705-733.

2. Aglietti P, Insall JN, Buzzi R, Deschamps G (1983) Idiopathic osteonecrosis of the knee. Aetiology, prognosis and treatment. *J Bone Joint Surg Br* 65: 588-597.
3. Pape D, Seil R, Fritsch E, Rupp S, Kohn D (2002) Prevalence of spontaneous osteonecrosis of the medial femoral condyle in elderly patients. *Knee Surg Sports Traumatol Arthrosc* 10: 233-240.
4. Patel DV, Breazeale NM, Behr CT, Warren RF, Wickiewicz TL, et al. (1998) Osteonecrosis of the knee: current clinical concepts. *Knee Surg Sports Traumatol Arthrosc* 6: 2-11.
5. Ahuja SC, Bullough PG (1978) Osteonecrosis of the knee. A clinicopathological study in twenty-eight patients. *J Bone Jt Surg [Am]* 60A: 191-197.
6. Lotke PA, Ecker ML, Alavi A (1977) Painful knees in older patients: radionuclide diagnosis of possible osteonecrosis with spontaneous resolution. *J Bone Jt Surg [Am]* 59A: 617-621.
7. Yamamoto T, Bullough PG (2008) Spontaneous osteonecrosis of the knee: the result of subchondral insufficiency fracture. *J Bone Jt Surg [Am]* 82A: 858-866.
8. Koshino T, Okamoto R, Takamura K, Tsuchiya K (1979) Arthroscopy in spontaneous osteonecrosis of the knee. *Orthop Clin North Am* 10: 609-618.
9. Soucacos PN, Xenakis TH, Beris AE, Soucacos PK, Georgoulis A (1997) Idiopathic osteonecrosis of the medial femoral condyle. Classification and treatment. *Clin Orthop Relat Res* 1997: 82-89.
10. Soucacos PN, Johnson EO, Soultanis K, Vekris MD, Theodorou SJ, et al. (2004) Diagnosis and management of the osteonecrotic triad of the knee. *Orthop Clin North Am* 35: 371-381.
11. Lotke PA, Ecker ML, Alavi A (1977) Painful knees in older patients. Radionuclide diagnosis of possible osteonecrosis with spontaneous resolution. *J Bone Joint Surg Am.* 59: 617-621.
12. Yates PJ, Calder JD, Stranks GJ, Conn KS, Peppercorn D, et al. (2007) Early MRI diagnosis and non-surgical management of spontaneous osteonecrosis of the knee. *Knee* 14: 112-116.
13. Rozing PM, Insall J, Bohne WH (1980) Spontaneous osteonecrosis of the knee. *J Bone Joint Surg [Am]* 62: 2-7.
14. Lotke PA, Abend JA, Ecker ML (1982) The treatment of osteonecrosis of the medial femoral condyle. *Clin Orthop* 171: 109-116.
15. Breer S, Oheim R, Krause M, Marshall RP, Amling M, et al (2013) Spontaneous osteonecrosis of the knee (SONK). *Knee Surg Sports Traumatol Arthrosc* 21: 340-345.
16. Takata N, Furumatsu T, Abe N, Naruse K, Ozaki T (2011) Comparison between loose fragment chondrocytes and condyle fibrochondrocytes in cellular proliferation and redifferentiation. *J Orthop Sci* 16: 589-597.
17. Forst J, Forst R, Heller KD, Adam G (1998) Spontaneous osteonecrosis of the femoral condyle: causal treatment by early core decompression. *Arch Orthop Trauma Surg* 117: 18-22.
18. Mont MA, Baumgarten KM, Rifai A, Bluemke DA, Jones LC, et al. (2000) Atraumatic osteonecrosis of the knee. *J Bone Joint Surg Am* 82: 1279-1290.
19. Akgun I, Kesmezacar H, Ogut T, Kebudi A, Kanberoglu K (2005) Arthroscopic microfracture treatment for osteonecrosis of the knee. *Arthroscopy* 21: 834-843.
20. Myers TG, Cui Q, Kuskowski M, Mihalko WM, Saleh KJ (2006) Outcomes of total and unicompartmental knee arthroplasty for secondary and spontaneous osteonecrosis of the knee. *J Bone Joint Surg Am* 88: 76-82.
21. Radke S, Wollmerstedt N, Bischoff A, Eulert J (2005) Knee arthroplasty for spontaneous osteonecrosis of the knee: unicompartmental vs bicompartmental knee arthroplasty. *Knee Surg Sports Traumatol Arthrosc* 13: 158-162.
22. Marmor L (1993) Unicompartmental arthroplasty for osteonecrosis of the knee joint. *Clin Orthop Relat Res* 1993: 247-253.
23. Parratte S, Argenson JN, Dumas J, Aubaniac JM (2007) Unicompartmental knee arthroplasty for avascular osteonecrosis. *Clin Orthop Relat Res* 464: 37-442.