

# Splenic Hydatid Cyst: Open Or Laparoscopic Approach?

Eugen Târcoveanu<sup>1\*</sup>, Costel Bradea<sup>1</sup>, Alin Vasilescu<sup>1</sup>, Ștefan Georgescu<sup>1</sup>, Mădălina Palaghia<sup>1</sup>, Felicia Crumpei<sup>2</sup>, Nicolae Danilă<sup>1</sup> and Cristian Lupașcu<sup>1</sup>

<sup>1</sup>Department of Surgery, "Gr.T. Popa" University of Medicine and Pharmacy Iasi, "St. Spiridon" Hospital Iasi, Romania

<sup>2</sup>Department of Radiology, First Surgical Unit, "St. Spiridon" Hospital Iasi, Romania

## Abstract

Splenic hydatid cyst is a rare disease. The aim of this study is to specify epidemiologic features, diagnostic tools, and therapeutic modalities of this disease.

**Materials and methods:** This is a retrospective study of 28 patients operated on by open and laparoscopic approach for a splenic hydatid cyst between January 1990 and December 2017 in First Surgical Clinic of "St. Spiridon" University Hospital of Iasi. The demographic data, localization, diagnosis, treatment methods, and the length of postoperative hospital stay of patients with splenic hydatid cysts were evaluated.

**Results:** Our study group included 16 women and 12 men with a mean age of 47.82 years. 17 patients had solitary splenic involvement and 11 patients had multiple organ involvement. Abdominal pain was the most common symptom. Splenomegaly was detected on physical examination in 12 patients. Ultrasound examination and CT scan revealed a cystic mass in the spleen in all cases. All patients were operated on by laparoscopic approach-6 cases (one conversion) and by open approach-22 cases: 26 total splenectomies and 2 conservative procedures for the spleen being performed. It is sometimes difficult to perform laparoscopic approach because of close adhesions with adjacent organs. No postoperative death was recorded, and the overall morbidity was 23.3%.

**Conclusions:** Splenic hydatid cysts are rare, being more common in endemic areas; in our region the incidence of splenic hydatid cysts is low. The splenic hydatid cyst may become a challenging surgical problem. The management must be individualized. Laparoscopic approach is feasible in selective cases.

## Keywords

Splenic hydatid cyst; Splenectomy; Laparoscopy

## Introduction

The spleen is the third most frequent localization (2.5-5.8%) of taenia echinococcus after liver (50-70%) and lungs (10-30%) [1]. Splenic involvement may be solitary, or may also accompany other organ involvement, commonly the liver [2]. Echinococcal cyst of the spleen is usually a result of an infection mainly with the parasite Echinococcus granulosus. Most hydatid cysts are acquired in childhood. It is estimated that hydatid cysts increase their diameter by about two to three centimetres each year [3].

## Materials and Methods

We performed a retrospective study of operated splenic hydatid cysts, in First Surgical Unit, "St. Spiridon" Hospital Iasi, from 1990 until 2018. Clinical, laboratory, intraoperative and imagistic data were included in a MS Excel Office database. Statistical analysis was performed with the IBM SPSS Statistics ver. 20 for Windows. The statistical significance, the "p value" was considered  $p < 0.05$  (test t-Student and test Chi-Square). For establishing the mean we used Standard Error Mean. The aim of this study is to specify epidemiologic features, diagnostic tools, and therapeutic modalities of this disease.

## Results

In the period 1990-2018 at the First Surgical Clinic of "St. Spiridon" University Hospital of Iasi 28 patients with splenic splenic hydatid cysts were operated by open or laparoscopic approach.

Our retrospective study group included 16 women and 12 men with a mean age of  $47.82 \pm 2.47$  years (ranges 19-70 years). Most patients were from rural areas (82.1%), the occupational hazards being frequently involved in etiopathogenesis of the disease (35.7%).

Also, their age was lower ( $45.92 \pm 3.61$  years vs.  $49.25 \pm 3.42$  years, test t-Student,  $p < 0.05$ ).

There were 17 isolated primitive cysts and 2 secondary ones, the initial localization being in the liver and the concomitant hydatid disease (9): liver (4), peritoneal (2), and liver-lung-peritoneal (1), liver-peritoneal (2).

The most common and early symptom was left quadrant pain of varying intensity, radiating or not to other areas (96.4%). The late manifestation was the presence of a tumor palpable in the left quadrant, below the costal margin, of elastic or hard consistency, immobile or with various degrees of mobility (42.8%). Quite frequently it was associated with a nonspecific dyspeptic syndrome probably of mechanical origin. In one instance with pulmonary dissemination the patient presented thoracic pains and dyspnea. In all our cases, we did not find any statistical significance link between the symptoms and primitive or secondary cyst, or a concomitant hydatid disease.

Complications were recorded in six cases: five suppurations and one rupture into the peritoneum. Eight patients complained of pruritus, and one patient required treatment for anaphylactic shock. The positive

**\*Corresponding author:** Eugen Tarcoveanu, Professor of Surgery, Department of Surgery, "Gr.T. Popa" University of Medicine and Pharmacy Iasi, "St. Spiridon" Hospital, Independentei street No 1, Iasi, Romania, Tel/Fax: +40 (0) 232 21 82 72; E-mail: [etarcov@yahoo.com](mailto:etarcov@yahoo.com)

**Received** March 01, 2018; **Accepted** March 13, 2018; **Published** March 20, 2018

**Citation:** Târcoveanu E, Bradea C, Vasilescu A, Georgescu S, Palaghia M, et al. Splenic Hydatid Cyst: Open Or Laparoscopic Approach?. Journal of Surgery [Jurnalul de chirurgie]. 2018; 14(1): 39-44 DOI: [10.7438/1584-9341-14-1-6](https://doi.org/10.7438/1584-9341-14-1-6)

**Copyright:** © 2018 Târcoveanu E, et al. This is an open-access article distributed under the terms of the Creative Commons Attribution License, which permits unrestricted use, distribution, and reproduction in any medium, provided the original author and source are credited.

diagnosis was made by clinical and laboratory tests, associated, in some cases, with a history of hydatid disease.

Eosinophilia ranged between, 3 and 12% in 20 patients. ELISA reaction was positive in 19 of 28 patients. Six patients presented associated manifestations of hypersplenism (anemia, thrombocytopenia).

Plain abdominal radiography and thoracic x-ray showed opacity in the left quadrant, and only rarely calcifications (1.78%) (Figure 1), which elevated the left hemidiaphragm in six patients and pushed the air bag of the stomach, to the right in eight patients (Figure 1).

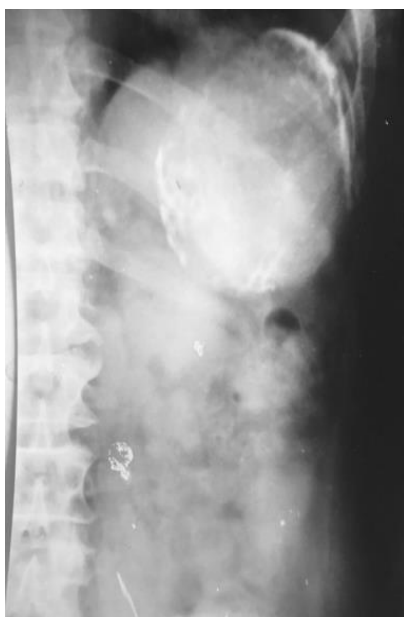Abdominal ultrasound, used in all patients led to the diagnosis (Figure 2) in most cases, those with multiple cysts included. Ultrasound is the most useful investigation as it gives exact information, on the site, size and stage of the cyst. By this method the diagnosis was preoperative in 26 of the 28 patients; in one case it being mistaken with a cyst of the right lobe of the liver and in another one with a pseudocyst of the tail of the pancreas (Figure 2).

After Garby classification the cases were: type I-4 cases, type II-membrane detachment-2 cases; type III-13 cases; type IV 4 cases; type V-calcified cyst-5 cases.

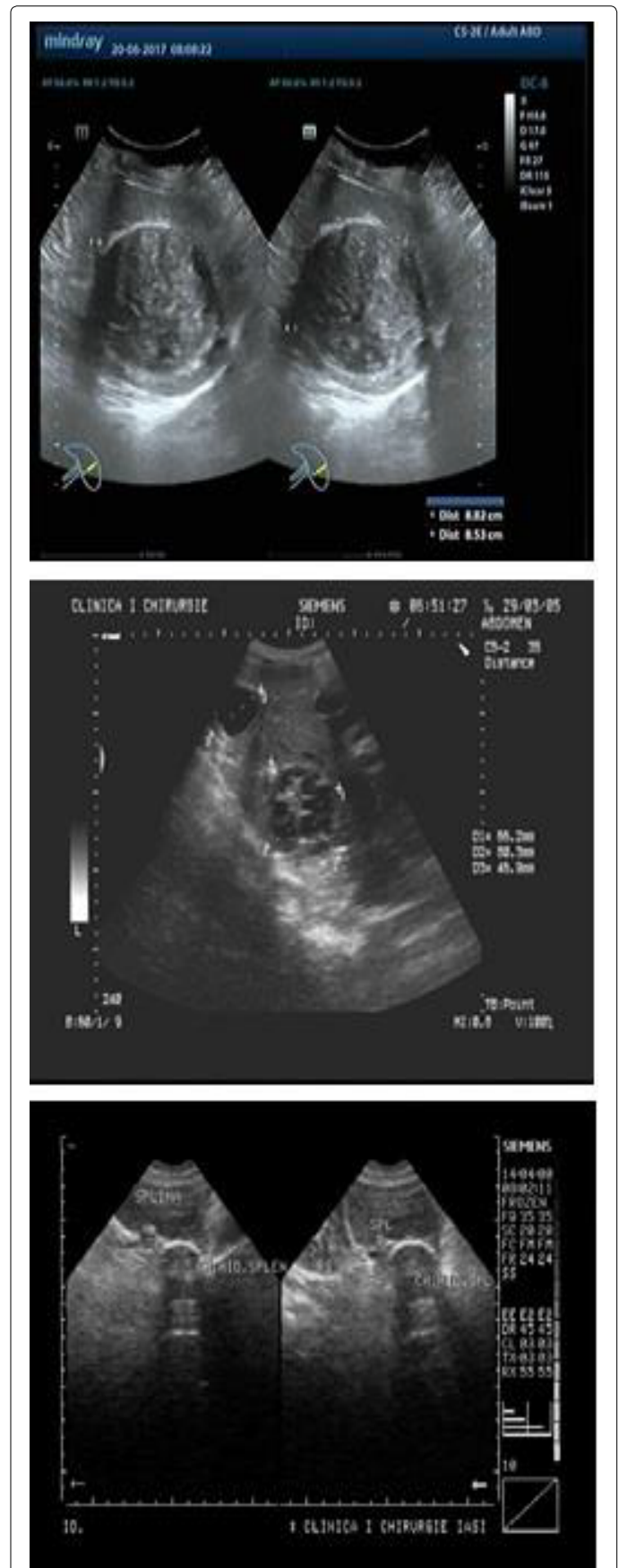
CT scan, was required in 18 cases, and gave us very precise data for the diagnosis (Figure 3) and the choice of a surgical approach. IRM done in three cases was very precise (Figure 3).

All patients were operated under general anesthesia with IOT. The approach was left subcostal in 9 cases, median in 9 cases, left paramedian in 2 cases and Chevron (roof top) modification incision in one patient with an associated liver hydatid cyst. In 23 cases (82.14%), attachments to the diaphragm of neighboring organs, sometimes very tight, were found intraoperatively. Laparoscopic approach was performed in 6 cases, with one conversion. Polar localizations of the cyst were preferred in the laparoscopic approach (5 cases, test Chi Square,  $p < 0.05$ ). Laparoscopic approach with concomitant thoracic approach was utilized in one case with pulmonary, hepatic and splenic cysts.

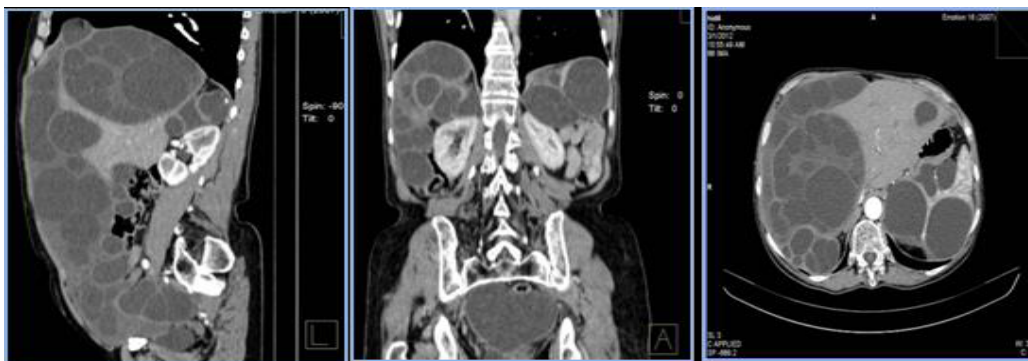The site of the cyst was unipolar in 12 cases (Figure 4), central in 10 cases and occupied the entire spleen in 3 patients (Figure 5); 2 patients presented two splenic cysts (Figure 6) and 1 patient 3 cysts. Central cysts



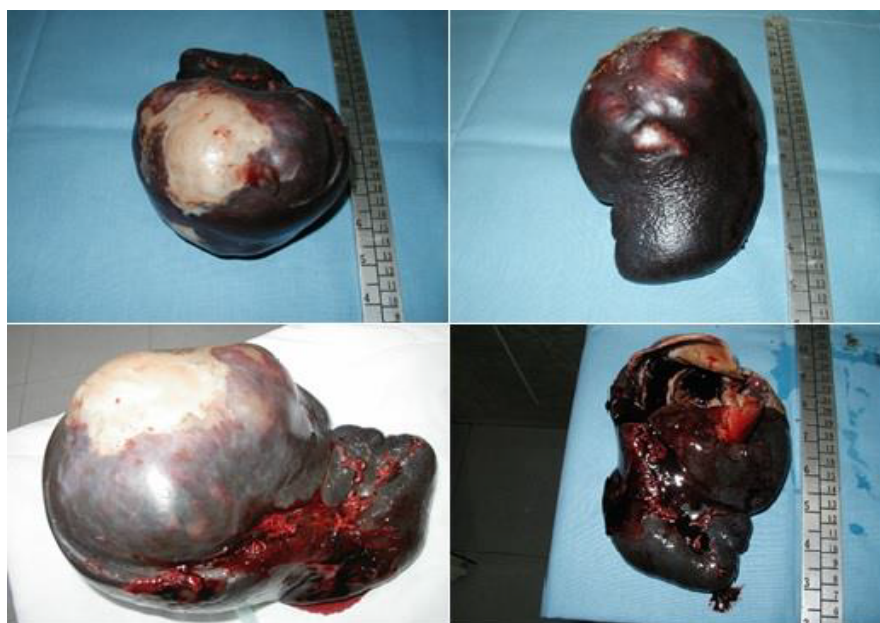**Figure 1:** Plain abdominal radiography: opacity in the left superior quadrant of the abdomen with calcifications.



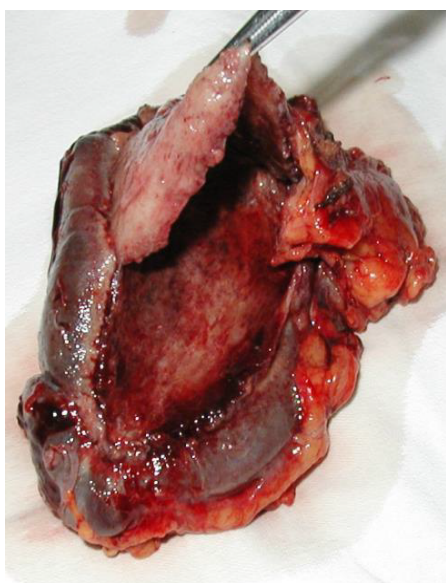
**Figure 2:** Abdominal ultrasound: splenic, hepatic and peritoneal hydatid cyst.



**Figure 3:** Hydatid cysts multivesicular disseminated intraperitoneally, in the liver, bilobar, at the level of the spleen, of the ureter and adjacent to the right psoas muscle, prior to the origin of the common iliac artery.



**Figure 4:** Hydatid spleen cyst 15 cm polar superior.



**Figure 5:** Old splenic hydatid cyst with a thick wall that destroys the entire splenic parenchyma.

were complicated in half of the cases, statistically significant to other locations (test Chi Square,  $p < 0.05$ ). The diameter of the cysts ranged between 9 and 30 cm, the fluid being clear, cloudy or purulent (2 cases). The mean diameter of univesicular cyst (Figure 7) was statistically significant lower comparative with multivesicular cysts ( $10.57 \pm 1.98$  cm vs.  $17.81 \pm 1.18$  cm, test t-Student,  $p < 0.05$ ) (Figures 4-6).

Conservative methods were employed in two patients but with mediocre results in two of them: recurrence after 5 and 12 years. Splenectomy was successful in 26 patients: ideal in 16 patients and after the inactivation and reduction of the cyst in 10 cases. Elective drainage of the splenic bed was done in 22 cases. Interventions for associated hydatidosis (8 patients), multiple liver-splenic cysts (6 patients) and peritoneal cyst (2 patients) were concomitantly performed. Laparoscopic splenectomy was performed in 4 cases with one conversion. It is sometimes difficult to opt for laparoscopic approach because of close adhesions with adjacent organs.

Anaphylactic shock occurred in a patient with associated liver cyst. No death was recorded and morbidity was of 23.3%, mainly after an open approach: suppuration of residual cavity (1), phlebitis (1), and parietal suppuration (7). Multivesicular cysts have predisposed at the onset of morbidity (test Chi-Square,  $p < 0.05$ ). In the case of postsplenectomy evolution no major pulmonary complications were recorded (except for interstitial pneumonia in 1 case).





Figure 6: Double splenic hydatid cyst.

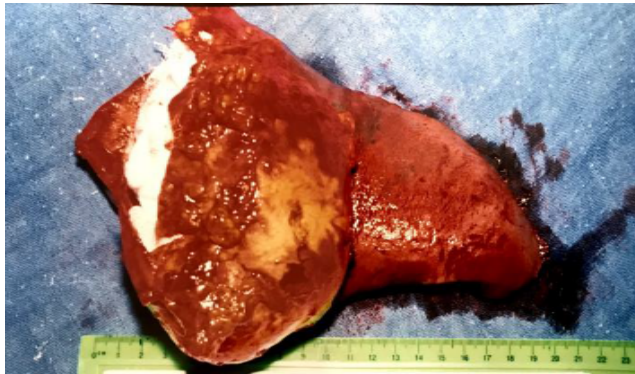


Figure 7: Univesicular splenic hydatid cysts.

The mean postoperative hospital stay was of  $13.36 \pm 1.19$  days (4-38 days). After laparoscopic approach the mean postoperative hospitalization was  $6.6 \pm 1.04$  days significantly smaller than the open approach ( $14.12 \pm 1.26$  days, t-Student,  $p < 0.05$ ). The mean hospital stay was influenced by morbidity ( $11.68 \pm 0.875$  days vs.  $16.89 \pm 3.007$  days) and the type of uni or multivesicular cyst ( $9.43 \pm 1.15$  days vs.  $14.67 \pm 1.44$  days, t-Student,  $p < 0.05$ ).

There were 2 recurrences after a postoperative interval of 5 up to 12 years: in one case following PAIR and in another one due to secondary peritoneal echinococcosis. All cases were re-operated. The treatment with albendazole did not influence the onset of relapse (test Chi-Square,  $p > 0.05$ ).

## Discussion

Primary infestation of the spleen usually takes place by the arterial route after the parasite has passed the two filters (hepatic and pulmonary). A retrograde venous route, which bypasses the lung and liver, is possible. Secondary splenic hydatid disease usually follows systemic disseminated or intraperitoneal spread following ruptured hepatic hydatid cyst (4 cases in our series).

The first report of splenic hydatid cysts were of Berthelot and Morgagni. The anatomic-clinical and therapeutic studies published by Brocq, Quenu and Dieufloy. Sabatini has made a review of 288 cases from literature in 1935. In Romania, Z. Papay reported 4 cases in 1961, I. Danitico 9 cases in 1962 [2], Gh. Popovici 5 cases in 1976 [3], V. Strat 23 cases in 1988 [4] and C. Vasilescu 35 cases in 2016 [5]. Most authors report an incidence of 1.4 to 3.9%, statistically it being the third most common localization after the liver and lungs [6-9].

Between 1961-2017 in the First Surgical Clinic of Iasi 1392 patients with hydatid disease were treated surgically: 1019 liver cysts, 230 pulmonary cysts and 143 cysts with rare localizations (splenic-53,

peritoneal-40, muscular-12, subcutaneous-9, mediastinal-7, pleural-6, kidney-5, tubo-ovarian-4, retroperitoneal-4, pancreatic-2, thyroid-1). Regarding the global incidence of splenic hydatid cyst was 3.8%, third most common-localization, after the liver and lungs. The incidence of splenic cyst has increased in the period 1988-1996, probably due to, the advent of ultrasonography. In the last decade the incidence of hydatid disease decreased (206 liver hydatid cysts, 3 splenic hydatid cysts).

The natural course of splenic hydatid cyst is the same as for other localizations: progressive increase in size, change in fluid appearance-from univesicular, clear as spring water to multivesicular, infected (11-25% of the cases), tendency to compress the neighboring structures as it enlarges, and the likelihood of rupture into one of the adjacent organs or peritoneum.

The diagnosis is usually preceded by a long asymptomatic interval [10]. Nearly pathognomonic is the presence of a palpable tumoral mass in the left quadrant (12 cases-42.8%) accompanied or not by pain at this level [11]. Other symptoms may also occur: digestive manifestations by compression of the neighboring structures and thoracic pain or dyspnea for the upper polar cysts. Rarely, the splenic hydatid cyst may be discovered due to a complication. The complications may be very dangerous: secondary infection [12], fistulisation to adjacent organs (colon, stomach) [13,14] and rupture into the peritoneal, retroperitoneal space [15] or pleural cavity. The traumatic or spontaneous rupture of a hydatid cyst may cause a life-threatening complication of systemic anaphylactic reaction. Rarely, renal arterial compression with systemic hypertension, and splenic vein compression with segmental portal hypertension were cited [16]. In our cases 3 complications occurred (10.7%).

Eosinophilia may be identified following a haematological investigation (71.4%). Serological tests are highly sensitive and specific for Echinococcosis (67.8%).

Thoraco abdominal or chest radiograph, marginal or crumpled eggshell-like calcifications in the splenic area are suggestive of splenic hydatidosis. Ultrasonography and computed tomography are the major diagnostic tools for splenic hydatid cyst. MRI can also be used to diagnose hydatidosis. On ultrasound of abdomen, splenic hydatid cyst appear as a solitary unilocular or rarely multiple well defined anechoic spherical cystic lesions or may demonstrate an anechoic spherical cystic lesion with hyperechoic marginal calcification, as seen in this case. CT abdomen confirms the cystic lesion with or without daughter cysts within the spleen with an attenuation value near that of water that does not enhance after intravenous contrast administration. It is more sensitive than ultrasonography in depicting subtle wall calcification [17].

The ultrasound appearance allows the classification of splenic hydatid cyst into 5 stages similar with those used for liver hydatid cysts:

type I-clear fluid characteristic to uncomplicated univesicular cyst; type II-membrane detachment; type III-loculated, fluid appearance suggestive for some multivesicular cysts; type IV nonhomogeneous and appearance of pseudotumoral cysts; type V-calcified cyst.

The diagnosis is facilitated by the presence of hydatid cysts at other sites (28-29% of the cases), most, commonly liver and/or peritoneal cysts, and less commonly pulmonary ones.

The differential diagnosis of splenomegaly or left subphrenic calcifications became less complicated with the advent of ultrasonography. While types II, III and V are very suggestive for hydatidosis, types I and IV still raise diagnostic problems. A splenic cystic mass (type I) has to be differentiated from a serous cyst, a cystic malignant tumor or a false splenic cyst. The cyst with a heterogeneous appearance (type IV) has to be differentiated from a solid splenic tumor [18-20].

The treatment is surgical, by opting for an open or laparoscopic approach [21,22]. Medical treatment with Benzimidazole carbamates (mebendazole and albendazole) is recommended in recurrent cysts and/or multiple disseminated hydatidosis. Medical treatment should begin in the preoperative period and continued following surgery, to reduce recurrence rate for multiple cysts after spontaneous intraperitoneal rupture or accidental spillage during surgery and as a concomitant therapy with PAIR-puncture aspiration injection (ethanol 95% and polidocanol 1% during 10 min into the cyst cavity and after that of 2 to 5 ml of albendazole) reaspiration. PAIR is an alternative to surgery [23]. PAIR is effective in small cysts (<5 cm). The big risk of the method is the appearance of a splenic abscess and recurrence (one case in our series).

For the isolated splenic cyst a left subcostal incision or a midline supraumbilical incision are used. When a liver hydatid cyst is associated a midline incision or, preferably, a bisubcostal one are recommended. After the incision of the peritoneum, the adhesions between the cyst and the diaphragm, pancreas, stomach, the greater and lesser omentum make difficult the assessment of cyst extension. Great care must be exercised when attempting to free the cyst as it may result in diaphragm opening. For a massive cyst it is preferable and at the same time necessary to proceed first to cyst puncture, which, despite the risk of local contamination, by the resulting retraction offers a better access to the left subphrenic area and suggests the next surgical maneuver. Cyst sterilization with a scolical agent is not necessary in a radical surgery for a solid cyst; however, it is indicated in case of radical surgery for open cyst and becomes compulsory when the dome is resected.

The laparoscopic approach has been reported in literature with good results [24-27]. It is obvious surgeons should make every possible effort to preserve splenic tissue and spleen-saving technique with laparoscopic approach. The laparoscopic approach may be performed using a semilateral or lateral position of the patient. We prefer a hemilateral position at the beginning of the procedure for division of the short gastric vessels with Ligasure. Then the table can be tilted to more lateral position in which the spleen and other organs fall medially by gravity and offer access to the posterior face of the spleen and the perisplenic ligaments and hilum (the ligation of the vessels of the hilum made with vascular stapler).

Surgical techniques are divided to radical (total or partial splenectomy) and conservative procedures [28,29]. Total splenectomy without puncture of the cyst has been the conventional treatment for splenic hydatidosis. Benefits are: prevent dissemination or seeding of the surgical field, and the possibility of the anaphylactic shock, prevents recurrence and complications related to the residual cavity. Disadvantages are: overwhelming postsplenectomy sepsis especially in young people and children [30]. The total splenectomy is reserved to multiple cysts, giant cyst (over 10 cm) occupying more than 75% of

spleen, and central intraparenchymal cysts [31,32]. The choice of the surgical procedure depends on the size, the location and number of cysts. The classification of cysts spleen after Losanoff is 5 types: Type 1-cyst peripheral edge, subcapsular, type 2-cyst occupying less than half the parenchyma, spleen, Type 3-cyst which occupies more than half of parenchyma, spleen, Type 4-multiple cysts, Type 5-cyst located in the hilum of the spleen with compromised vasculature. Personally, I think that this classification has important role in the choosing the therapy and can be extended to splenic hydatid cyst, more common in young age, which would have kept some of the splenic parenchyma. For cysts of type 4 and 5, splenectomy is recommended for some of the Type 3. For type 1 and 2 it is possible to practice partial splenectomy [5]. The patients undergoing elective splenectomy should be vaccinated against *S. pneumonia*, *N. meningitides*, *H. influenzae*.

The ideal surgical method consists in the removal of the entire cyst but with the conservation of part of splenic parenchyma for preserving the immunological functions: Total pericystectomy and partial splenectomy respond to these requirements. Partial splenectomy is indicated in uncomplicated polar cysts that conserve 25% of the splenic parenchyma required to provide immune functions of the spleen [33,34]. Partial splenectomy can be performed under safe robotic approach [35]. Conservative operations include partial cystectomy after cyst inactivation and drainage by laparoscopic method. The disadvantages of the method are the risk of suppuration of residual cavity (11-27%) and of recurrence (18%) [26].

The indications for an adequate surgical technique can be summarized as follows: for an upper or lower pole cyst of moderate size and without significant local changes the dissection of splenic vessels and their branches followed by partial splenectomy, or partial cystectomy are recommended; for a cyst occupying almost the entire splenic parenchyma or multiple cysts, splenectomy is unavoidable; a massive cyst, possibly complicated with significant local and regional changes requires a conservative approach which seems to be more appropriate; in case of multiple extrasplenic hydatid cysts a radical method for the splenic cyst is in the best benefit of the patient.

## Conclusion

Splenic hydatid cysts are rare, being more common in endemic areas; in our region the incidence of splenic hydatid cysts is decreased. Ultrasonography, biological tests and CT are precise diagnostic in most cases. CT scan is the most sensitive investigation for diagnosis.

The splenic hydatid cyst may become a challenging surgical problem. The management must be individualized. Splenectomy is the safest method in the adult patients with cysts type 3, 4, 5. The laparoscopic approach is feasible in selective cases. Conservative treatment is recommended in the case of young people.

## Conflict of Interest

The authors have no conflict of interest to disclose.

## References

1. Türkoğlu E, Demirtürk N, Tünay H, Akıcı M, Öz G, et al. (2017) Evaluation of patients with cystic echinococcosis. *Türkiye Parazitol Derg* 41: 28-33.
2. Jabbari Nooghabi A, Raoufian K, Motie MR (2015) Concomitant splenic and hepatic hydatidosis: report of two cases and review of the literature. *Acta Med Iran* 53: 74-77.
3. Pukar MM, Pukar SM (2013) Giant solitary hydatid cyst of spleen-A case report. *Int J Surg Case Rep* 4: 435-437.
4. Strat V, Diaconescu MR, Cotea E, Frasin M (1988) Splenic echinococcosis. *Rev Chir Oncol Radiol O R L Oftalmol Stomatol Chir* 37: 91-96.
5. Vasilescu C (2016) Spleen. From laparoscopy to robotic surgery and back.
6. Bourgeon R, Catalano F, Pantin JP (1960) L'echinococcose splénique. *J Chir (Paris)* 80: 608-632.

7. Kocaoglu H, Kayabali I (1958) Kystes hydatiques de la rate. *Lyon Chir* 54: 466-471.
8. Kourias B (1957) L'echinococcose splénique. *J Chir (Paris)* 74: 138-157.
9. Bellakhdar A (1986) Les kystes hydatiques de la rate. A propos de 25 observations. *J Chir (Paris)* 123: 326-329.
10. Ben Ameur H, Affes N, Abdelhedi C, Kchaou A, Boujelbene S, Beyrouiti MI (2015) Hydatid cyst of the spleen: Tunisian series of 21 cases. *Indian J Surg* 77: 515-519.
11. Tarcoveanu E, Plesa A, Danila N, Lupascu C, Cotea E, et al. (2002) Splenic hydatid cyst, observations upon 38 cases of splenic echinococcosis. *Rev Med Chir Soc Med Nat Iasi* 107: 311-315.
12. Kismet K, Ozcan AH, Sabuncuoglu MZ, Gencay C, Kilicoglu B, et al. (2006) A rare case: spontaneous cutaneous fistula of infected splenic hydatid cyst. *World J Gastroenterol* 12: 2633-2635.
13. Teke Z, Yagci AB, Atalay AO, Kabay B (2008) Splenic hydatid cyst perforating into the colon manifesting as massive lower gastrointestinal bleeding: an unusual presentation of disseminated abdominal echinococcosis. *Singapore Medical Journal* 49: 113-116.
14. Ouafdel J, Bougtab A, Amraoui A, Fikri OK, Assem A, et al. (1988) Kyste hydatique de la rate rompu dans l'estomac. *Médecine du Maghreb* 26: 7-10.
15. Kaya B, Uçtüm Y, Kutaniş R (2010) Splenic hydatid cyst attacking retroperitoneum. *Türkiye Parazitol Derg* 34: 193-195.
16. Kantarçeken B, Çetinkaya A, Bülbüloğlu E, Demirpolat G (2010) Splenic hydatid cyst as a cause of sinistral portal hypertension and isolated gastric variceal bleeding. *Türk J Gastroenterol* 21: 317-320.
17. Rasheed K, Zargar SA, Telwani AA (2013) Hydatid cyst of spleen: a diagnostic challenge. *N Am J Med Sci* 5: 10-20.
18. Adas G, Karatepe O, Altioğ M, Battal M, Bender O, et al. (2009) Diagnostic problems with parasitic and non-parasitic splenic cysts. *BMC Surg* 9: 9.
19. Durgun V, Kapan S, Kapan M, Karabıçak I, Aydoğan F, et al. (2003) Primary splenic hydatidosis. *Dig Surg* 20: 38-41.
20. Sawarappa R, Kanoi A, Gupta M, Pai A, Khadri SIS (2014) Isolated splenic hydatidosis. *J Clin Diagn Res* 8: ND03-ND04.
21. Dar MA, Shah OJ, Wani NA, Kahn FA, Shah P (2002) Surgical management of splenic hydatidosis. *Surg Today* 32: 224-229.
22. Özdoğan M, Baykal A, Keşkek M (2001) Hydatid cyst of the spleen: treatment options. *Int Surg* 86: 122-126.
23. Akhan O, Akkaya S, Dağoğlu MG (2016) Percutaneous treatment of splenic cystic Echinococcosis: Results of 12 cases. *Cardiovasc Intervent Radiol* 39: 441-446.
24. Arce MA, Limaylla H, Valcarcel M, Garcia HH, Santivañez SJ (2016) Primary giant splenic echinococcal cyst treated by laparoscopy. *Am J Trop Med Hyg* 94: 161-165.
25. Busić Z, Kolovrat M, Đuzel A, Rakić M, Cavka M, et al. (2015) Laparoscopic partial pericystectomy of splenic hydatid cyst-a case report. *Lijec Vjesn* 137: 361-363.
26. Gharaibeh KI (2001) Laparoscopic excision of splenic hydatid cyst. *Postgrad Med J* 77: 195-196.
27. Diaconescu MR, Glod M, Costea I, Ciolpan C, Georgescu S (2008) Laparoscopic hand-assisted splenectomy for hydatid cyst. *Chirurgia (Bucur)* 103: 103-106.
28. Arikanoğlu Z, Taskesen F, Gumus H, Onder A, Aliosmanoglu I, et al. (2012) Selecting a surgical modality to treat a splenic hydatid cyst: total splenectomy or spleen-saving surgery? *J Gastrointest Surg* 16: 1189-1193.
29. Amatzidis K, Papaziogas B, Mirelis C, Pavlidis T, Papaziogas T (2003) Splenectomy versus spleen-preserving surgery for splenic echinococcosis. *Digestive Surgery* 20: 527-531.
30. Berrada S, Ridai M, Mokhtari M (1991) Hydatid cysts of the spleen: splenectomy or conservative surgery? *Ann Chir* 45: 434-464.
31. Malik AA, ul Bari S, Younis M, Wani KA, Rather AA (2011) Primary splenic hydatidosis. *Indian J Gastroenterol* 30: 175-177.
32. El Malki HO, Amahzoune M, Benkhraha K (2006) Le traitement conservateur du kyste hydatique de la rate. *Médecine du Maghreb* 139: 33-38.
33. Sharma A (2016) Splenectomy or partial splenectomy should be preferred treatment for large splenic hydatid cysts. *Am J Trop Med Hyg* 94: 1436.
34. Costi R, Castro Ruiz C, Zarzavadjian le Bian A (2015) Spleen hydatidosis treated by hemi-splenectomy: A low-morbidity, cost-effective management by a recently improved surgical technique. *Int J Surg* 20: 41-45.
35. Vasilescu C, Tudor S, Popa M, Tiron A, Lupescu I (2010) Robotic partial splenectomy for hydatid cyst of the spleen. *Langenbecks Arch Surg* 395: 1169-1174.