

Spigelian Hernia Containing an Incarcerated Appendix- A Case Report and Literature Review

Krzysztof Kaliszewski*, Michał Kozakiewicz, Beata Lubieniecka, Jacob Bronowicki, Piotr Szelachowski, Renata Taboła and Marta Strutyńska-Karpińska

Department and Clinic of General, Gastroenterological and Endocrine Surgery, Wrocław Medical University, Wrocław, Poland

Abstract

Background: A Spigelian Hernia (SH) is an uncommon clinical entity comprising 0.12% to 2% of all the abdominal wall hernias. Usually the symptoms of the hernia are non-specific and therefore a diagnosis based only on the clinical examination is difficult. Imaging studies are particularly useful during the diagnostic process, but sometimes do not give the proper presurgical diagnosis.

Case presentation: We present the case of a 77-year-old woman with a suspected tumor of the blind gut, where only a more accurate preoperative examination later enabled the identification of the presence of a SH. Furthermore, during the less conventional classical surgery it was revealed that the appendix, which is an event that rarely occurs, was found incarcerated within the hernia contents.

Conclusion: We present the clinical difficulty with diagnosis of SH with incarcerated appendix and the variety of the symptoms. Additionally, we present a brief literature review with a concomitant description of the clinical appearance, diagnostic approach, and treatment options concerning SH.

Keywords: Abdominal wall hernia; Spigelian hernia; Appendix

Abbreviations: SH: Spigelian Hernia; CRP: C-Reactive Protein; CT: Computed Tomography; COPD: Chronic Obstructive Pulmonary Disease; TAPP: Transabdominal Preperitoneal; TEP: Totally Extraperitoneal

Introduction

A Spigelian hernia (SH) is an uncommon hernia comprising 0.12% to 2% of all ventral wall hernias [1]. Adriann van den Spieghel, a Belgian anatomist, was the first to describe a region known as the Spigelian fascia, which is the aponeurotic layer located between the traverse abdominal muscle medially, and the semilunar line laterally [1-3]. Consequently, hernias in this region are referred to as SH. These uncommon hernias are difficult to diagnose, and the cases described in the literature generally only come from large, specialized centers [2]. Usually the symptoms are non-specific and therefore a diagnosis based only on the clinical examination is difficult. According to the literature, in 50% of the cases, confirmation of the diagnosis is only possible during surgery [1-4]. In this article we present the case of a patient with a suspected tumor of the blind gut, where only a more accurate preoperative examination later enabled the identification of the presence of a SH. Furthermore, during the less conventional classical surgery it was revealed that the appendix, which is an event that rarely occurs, was found incarcerated within the hernia contents.

Case Presentation

A 77-year-old Caucasian female was admitted to the hospital because of a 3-day history of the abdominal pain. On admission, physical examination revealed a solid mass in the right iliac region, but no signs of peritoneal irritation. The initial suspicion included periappendicular infiltration or a tumor of the blind gut. The patient was being treated for chronic arterial hypertension and hypothyroidism. Additionally, she stated she suffered from chronic back pain, constipation, and varicose veins of the lower limbs. In the past, she underwent umbilical hernia repair, a cesarean section, and cataract surgery. Her Body Mass Index (BMI) was 24.14 kg/m².

A standard blood test was performed, including morphology, clotting factor analysis, and the establishment of the levels of C-reactive

protein (CRP), total bilirubin, glucose, creatinine, urea, potassium, and sodium. All of the results were within normal limits, except white blood cell 11,39 (10 × 3/uL), normal value range: 4,5-10,0, CRP 17,5 mg/l and total bilirubin 2 mg/dl, normal value ranges: <0,3 and 0.2-1.2 respectively.

Imaging tests were also performed: x-ray of the chest and abdomen without any abnormalities except the visible loops of the intestines containing singular fluid levels. Due to the obesity of the patient an ultrasound of the abdomen was not feasible, and instead, a computed tomography (CT) scan was performed (Figures 1a-1d). The radio-imaging analysis exposed a non-perforated hernia containing strangulated loops of the intestine in the right lower abdomen above the right iliac fossa within the vicinity of the soft tissues of the abdominal integuments. The diameter of the rupture gate was estimated approximately 2.5 cm. Reactive changes were observed within the surrounding adipose tissue of the abdominal wall, whereas visible above the hernia was a mechanical ileus presented in the form of fluid-containing and dilated intestinal loops measuring up to 3.8 cm in width, as well as a small layer of free fluid along the edge of the liver and the spleen measuring up to 1.5 cm and 3.2 cm in thickness, respectively.

The patient was qualified for elective surgery. She was operated on the 7th day of hospitalization due to diagnostic delay. From the first day of admission to the final surgery there was not totally clear and incontestable diagnosis. While in general anesthesia, a paramedian lower right incision allowed for access to the fascia of the external

***Corresponding author:** Krzysztof Kaliszewski, Department and Clinic of General, Gastroenterological and Endocrine Surgery, Wrocław Medical University, Wrocław, Poland, Tel: +48 71 784 21 62; E-mail: krzysztofkalii@wp.pl

Received November 30, 2017; **Accepted** December 23, 2017; **Published** December 28, 2017

Citation: Kaliszewski K, Kozakiewicz M, Lubieniecka B, Bronowicki J, Szelachowski P, et al. (2017) Spigelian Hernia Containing an Incarcerated Appendix- A Case Report and Literature Review. J Clin Case Rep 7: 1057. doi: [10.4172/2165-7920.10001057](https://doi.org/10.4172/2165-7920.10001057)

Copyright: © 2017 Kaliszewski K, et al. This is an open-access article distributed under the terms of the Creative Commons Attribution License, which permits unrestricted use, distribution, and reproduction in any medium, provided the original author and source are credited.

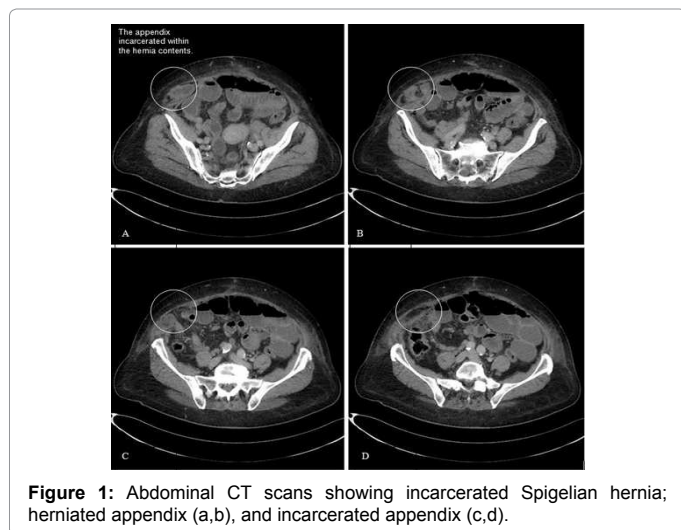


Figure 1: Abdominal CT scans showing incarcerated Spigelian hernia; herniated appendix (a,b), and incarcerated appendix (c,d).

oblique and the transverse abdominal muscles (semilunar line). A hernial sac with a diameter of about 10 cm was detected within the lower section of the surgical opening. The hernial gate was opened, widened, and slightly incised. The hernial contents included a fragment of the blind gut as well as the incarcerated appendix. An appendectomy was performed. The extracted appendix was secured for histopathological examination. The caecum was released. Subsequently, the gate of the hernia was sutured. A Redon drain was placed above the fascia. Hemostasis, a subcutaneous and a cutaneous suture, as well as dressing were applied. No complications occurred following the operation. The histopathological examination of the recovered materials was indicative only for appendicitis without any concomitant neoplastic changes. The patient was discharged in good general condition after 7 days following surgery.

Discussion

In 1742, Henri Francois Le Dran was the first to describe a rupture in the vicinity of the semilunar line [2]. In 1746, Beatricio La Chausse isolated a hernia in this region [2]. The term “Spigelian hernia” was first coined by Josef Klinkosch in 1764 [2,4-6]. Currently, this name refers to a hernia whose gate is located within the fascia of the transverse abdominal muscle that is limited laterally by the semilunar line [1,2,4-8].

Although some authors claim that this disease has a higher frequency among women, the overall results of published papers are inconclusive whether this condition is more prevalent among any of the two sexes. SH occur primarily in the 6th-7th decade of life, and most often occur on the left side. Bilateral hernias appear very rarely. The average BMI is around 29-31.50 kg/m². The most commonly accompanying comorbidities include: diabetes, peripheral vascular disease, cerebrovascular disease, COPD, coronary heart disease, diabetes, chronic kidney disease, and asthma. According to some statistical data, approximately 50% of SH patients had previously undergone abdominal surgery [1,2,5,6].

The semilunar line (Spigelian line) extends from the cartilage of the VIII-IX rib to the pubic tubercle and is an area of transition of the transverse abdominal muscle fibres into the aponeurosis, whose part located between the semilunar line and the lateral border of the rectus abdominal muscle is called the Spigelian fascia. In the widest part of the fascia, where the inferior epigastric vessels cross, there is a region called the Spigelian zone (this term was introduced by Spangen and it defines a 6-cm wide region superiorly from the interspinal line). The weakest

part of the Spigelian fascia is an area where the semilunar line intersects with the arcuate line (Douglas line). This area is weakened by the lack of the posterior sheath of the rectus abdominal muscle [4,6,7-9]. Most hernias arise within the triangle formed by the arcuate line superiorly, the semilunar line laterally and the inferior epigastric vessels inferiorly. Hernias located inferiomedially from the vascular bundle are called lower hernias, whereas upper hernias, located superiorly to the navel are rare. 0.7% of the cases have more than one gate. It is also known as the “lateral abdominal hernia” and the “lateral ventral abdominal hernia”. We can also classify the hernia as an intramural hernia - located under the aponeurosis of the external oblique muscle (98% of all cases) or a subcutaneous hernia - where the hernia sac passes through the aponeurosis [2,4,6]. In our case the gate of hernia was located inferomedially from the vascular bundle (lower hernia).

The etiology is not exactly known. From an embryological point of view the SH may derive from an inherent weakness in the fusion area of the aponeuroses of the abdominal muscles; stemming from their independent and separate development from invading and fusing myotomes within the mesenchyme. The vascular theory assumes that the hernia is formed in places where the vessels and nerves penetrate through the aponeurosis. There is no clear evidence to support the validity of any of the aforementioned theories. It is currently accepted that a multifactorial theory is the most likely. The risk factors include: obesity, collagen disorders, chronic obstructive pulmonary disease (COPD) and previous operations [1,2,4,6,10]. In the presented case, it can be assumed that the hernia was caused by previous surgeries, obesity, and chronic constipation.

SH may be idiopathic, acquired, congenital, traumatic or iatrogenic - as a direct consequence of the introduction of a laparoscopic port. It can co-occur with other abdominal hernias, which is suggestive of connective tissue disease [3,6,11-13]. Hernia sacs, most frequently are formed by the peritoneum however, the aponeurosis of the transverse abdominal muscle may also contribute to the structures constituting the hernia sac. Hernia sacs usually contain a fragment of fatty tissue or a segment of the omentum. In the cases described in the literature it is less of a common occurrence for the hernia contents to enclose tissues such as the appendix, small intestine, colon, stomach, gall bladder, blind gut, Meckel’s diverticulum or ovarium [14-17]. Due to its location, the appendix is usually a component of abdominal hernias located on the right side of the body [6,14-17] as was the case in our patient. According to the literature review there are approximately 10 cases of the appendix incarcerated in SH described to date [2,17]. All of these reported cases of SH contained incarcerated appendix were diagnosed as periappendicular mass palpated physically, as inflamed incarcerated appendix reveal in CT scan or in explorative laparotomy. As a result of the non-specific clinical picture of the condition diagnosis is difficult. The most commonly reported symptom is abdominal pain, which increases with increasing intra-abdominal pressure. Physical examination can reveal distinct bulging, however, in obese individuals the localization of this sign may be difficult. Other commonly reported symptoms include vomiting and bloating. The optimal diagnostic technique allowing for the detection of hernias is CT. During the diagnostic process an ultrasound examination may also prove useful. Moreover, magnetic resonance imaging or a diagnostic laparoscopy are helpful in difficult cases [1-4,6,9,10,18]. In our described case the preliminary diagnostic impression was suggestive of the presence of a tumor of the blind gut or a periappendicular infiltrate. A CT scan revealed the correct suspicion. Complications occurring during the diagnostic and therapeutic process (strangulations, perforations) generally have an impact on the length of hospitalization. Usually

they are connected with the necessity to perform emergency surgery involving a partial bowel resection. Obesity and comorbidities usually do not significantly influence the duration of hospitalization or the result of surgery. In the majority of cases the patients were discharged within one day [1,3,14]. Every case requires surgical treatment which involves either open or laparoscopic approach. Sometimes it is mandatory to perform the surgery immediately because of the risk of incarceration and strangulation reaching up to 24% and which is particularly threatening in the case of narrow hernia gates 0.5-2 cm. Untreated it can also lead to obstruction, necrosis and bowel perforation. The risk of recurrence is not very low, and it ranges from 5% to 14% [1,3,5-7,14,15,19].

In 1992, Carter was the first to apply laparoscopy in order to repair a SH [20]. The utilization of this technique is associated with a smaller postoperative wound, fewer infections and less postoperative pain in comparison with the classic approach. The laparoscopic technique provides a better opportunity to examine the abdominal organs and allows for a shorter duration of hospitalization. Postoperative complications are rare; however, they may include bleeding, urinary retention, arrhythmias, and intestinal obstruction. This procedure can be carried out by one of three methods: transabdominal preperitoneal (TAPP) repair, totally extraperitoneal (TEP) repair or simple suturing. Open surgery should be performed in the severe cases and if the laparoscopic method is not available. The experience of a surgeon must also be taken into consideration [1,2,4,7,8,14,15].

Conclusion

A SH is a rare type of abdominal hernia and the appendix is seldom found in the hernia contents. The initial symptoms are generally non-specific, delaying the proper diagnosis and contributing to the slower administration of the appropriate treatment. Imaging studies are particularly useful during the diagnostic stages. When rendering a decision in regard to the surgical technique that is to be employed, the experience of the surgeon must be taken into consideration the rarity of the SH and its contents, in the form of the blind gut and the appendix, led us to present this case.

References

1. Polistina FA, Garbo G, Trevisan P, Frego M (2014) Twelve years of experience treating Spigelian hernia. *J Surg* 157: 547-550.
2. Szczyński W, Stankiewicz W (2015) Hernias of the rectus muscle fascia. In: Noszczyk W, Naumowska K (eds). *Rare abdominal hernias in adults- epidemiology, etiology, diagnostics and current management*. Warsaw: Foundation of Polish Surgical Review 38-40.
3. Zuvella M, Milicevic M, Galun D, Djuric-Stefanovic A, Bulajic P, et al. (2013) Spigelian hernia repair as a day-case procedure. *Hernia* 17: 483-486.
4. Kumar A, Garg PK, Dahiya D, Chaurasia A (2013) Unusual disappearing abdominal bump: Spigelian hernia. *Maedica (Buchar)* 8: 269-271.
5. Moreno-Egea A, Campillo-Soto Á, Morales-Cuenca G (2015) Which should be the gold standard laparoscopic technique for handling Spigelian hernias? *Surg Endosc* 29: 856-862.
6. Ciesielska-Krosny A, Mazur D, Waszczuk E, Paradowski L (2011) Spigelian hernia. *Gastroenterol Pol* 18: 80-83.
7. Yi-Chun S, Hsien-Pin S (2014) Spigelian hernia showing itself as a left lower abdominal mass. *Formos J Surg* 47: 78-81.
8. Richards AT (2004) Spigelian hernias. *Oper Tech Gen Surg* 6: 228-239.
9. Messina Campanella A, Licheri S, Barbarossa M (2015) Topic: abdominal wall hernia- spigelian hernia, anatomy, incidence, repair. *Hernia* 19: S215.
10. Foster D, Nagarajan S, Panait L (2015) Richter-type Spigelian hernia: A case report and review of the literature. *Int J Surg Case Rep* 6: 160-162.
11. Gates AA, Desai NS, Sodickson AD, Khurana B, Gates JD (2015) BWH emergency radiology-surgical correlation: Traumatic Spigelian hernia with right colonic injury. *Emerg Radiol* 22: 709-711.
12. Saha S, Saurabh G, Andley M, Kumar A (2014) Traumatic spigelian hernia: A rare clinical scenario. *J Clin Diagn Res* 8: ND01-ND02.
13. Celdrán A, Señaris J, Mañas J, Frieyro O (2007) The open mesh repair of Spigelian hernia. *Am J Surg* 193: 111-113.
14. Barnes TG, McFaul C, Abdelrazeq AS (2014) Laparoscopic transabdominal preperitoneal repair of spigelian hernia-closure of the fascial defect is not necessary. *J Laparoendosc Adv Surg Tech A*. 24: 66-71.
15. Kelly ME, Courtney D, McDermott FD, Heeney A, Maguire D, et al. (2015) Laparoscopic Spigelian hernia repair: A series of 40 patients. *Surg Laparosc Endosc Percutan Tech* 25: e86-e89.
16. Cheung YF, Ng DCK, Li RSK, Leong HT (2015) Appendicitis in abdominal wall hernia: Case series and literature review. *Surg Pract* 19: 86-89.
17. Bevilacqua M, Ahmed S, Miller M, Sallee D, Angel W (2016) Case of Spigelian hernia with incarcerated appendix. *J Radiol Case Reports* 10: 23-28.
18. Bhardwaj A, Kalhan S, Bhatia P, Khetan M, John S, et al. (2015) Topic: Abdominal wall hernia - Spigelian hernia, anatomy, incidence, repair. *Hernia* 19: S344.
19. Patle NM, Tantia O, Sasmal PK, Khanna S, Sen B (2010) Laparoscopic repair of spigelian hernia: Our experience. *J Laparoendosc Adv Surg Tech A* 20: 129-133.
20. Carter JE, Mizes C (1992) Laparoscopic diagnosis and repair of Spigelian hernia: Report of case and technique. *Am J Obstet Gynecol* 167: 77-78.