

Significance of Marginal Vacuoles in Fine Needle Aspiration Cytology of Diffuse Thyroid Swelling

Bamanikar S^{1*}, Bamanikar A², Nair R¹, Chandanwale S¹, Kumar H¹ and Buch A¹

¹Department of Pathology, Dr. D. Y. Patil Medical College, Hospital and Research Centre, Pimpri, Pune 411018, Maharashtra, India

²Department of Medicine, Dr. D. Y. Patil Medical College, Hospital and Research Centre, Pimpri, Pune 411018, Maharashtra, India

*Corresponding author: Sunita Bamanikar, 5 & 6, Siddharth Estates, North avenue, Kalyani nagar, Pune 411006, Maharashtra, India, Tel: 02026688811; E-mail: sunitarvind@hotmail.com

Received date: Oct 14, 2015; Accepted date: Nov 26, 2015; Published date: Nov 28, 2015

Copyright: © 2015 Bamanikar S, et al. This is an open-access article distributed under the terms of the Creative Commons Attribution License, which permits unrestricted use, distribution, and reproduction in any medium, provided the original author and source are credited.

Abstract

Assessment of thyroid swelling by Fine needle aspiration cytology (FNAC) is an established first-line diagnostic test. Marginal vacuole (MVs) in fine needle aspiration (FNA) smears stained by Leishman's stain have been described as a characteristic feature of thyrotoxic goiter, but was also found in various nontoxic thyroid lesions. Although the exact nature of these MVs is not known, on electron microscopy they are seen as dilated endoplasmic reticulum which represents active pinocytotic vacuoles containing colloid. The aim of the study was to examine the presence of MVs in diffuse thyroid enlargement and evaluate the strength of association between MVs, thyroid function status and cytological diagnosis. We examined seventy six cases of diffuse thyroid swelling. Cytomorphological features were observed with special attention to MVs and their density was graded as scant, moderate and abundant. The strength of association was studied by applying the Chi-square test; a $P \leq 0.05$ was taken significant. Abundant MVs were not associated with hypothyroidism in this study; 73.3% of these cases were hyperthyroid. Interestingly, abundant MVs in thyroid FNACs were seen in cases of primary hyperplasia and Hashimoto's thyroiditis. The presence of abundant/moderate MVs correlated significantly with primary hyperplasia and the absence of abundant MVs was significant in colloid goiter. Scant MVs in diffuse goiters were not found to correlate with thyroid function. Thus, hormonal evaluation is essential in all diffusely enlarged goiters showing prominent MVs in order to rule out hyper functioning goiter.

Keywords: Fine needle aspiration cytology; Thyroid lesions; Marginal vacuoles

Introduction

Fine needle aspiration cytology (FNAC) is now a well-established, simple and quick and effective diagnostic tool for triaging surgical and non-surgical goiters [1-3]. In comparison with other diagnostic modality such as needle biopsies, it causes less destruction of the tissue around the needle and risk of displacement of cells is small.

Accurate diagnosis of various thyroid lesions by FNAC is based on the identification of predominant cell pattern, cell morphology and background details [4].

Morphological changes are very similar in all forms of hyperfunctioning thyroid including toxic diffuse hyperplasia (Grave's disease), toxic adenoma and primary hyperthyroidism. Diagnosis of hyperthyroidism is made on the basis of clinical symptoms and laboratory data. FNAC is generally performed to exclude a thyroid neoplasm. About one third of the patients of thyroid cancer will have associated thyroid pathology like adenomatous goiter, multinodular goiter or Hashimoto's thyroiditis [5].

Cytomorphologic features include characteristic abundant pale and finely granular cytoplasm, fading away against the back ground due to marginal vacuoles (MVs). MVs were initially described as a distinctive feature of thyrotoxic goiter in hyperthyroidism but have been reported subsequently in non-toxic (colloid) goitre, Hashimoto's thyroiditis and neoplastic thyroid lesions especially follicular neoplasm [6].

These vacuoles stain pink with the MGG method and contain granular material; as a result the periphery of the cells, they look like fire-flares (flare cells). MVs are seen as magenta coloured irregular cytoplasmic vacuoles 1-7 micron in diameter mainly seen at the rim of the cytoplasm around the edges of aggregates of follicular cells. They are deeply eosinophilic at the periphery with large unstained areas in the centre. They are not well appreciated on haematoxylin - eosin and PAP stained smears [6,7].

Ultrastructurally, marginal vacuoles (MVs) are the dilated cisternae of endoplasmic reticulum formed by their hyperactivity and vacuolar content as dilated phagolysosomes [8,9].

The study was conducted to look for the presence of MVs and the significance of their association with thyroid function and cytological diagnosis in diffuse thyroid lesions.

Patients and Methods

This study was conducted on 76 patients who presented with diffuse thyroid enlargement. Patients having solitary thyroid nodule, multinodular goiter and inadequate aspirates were excluded from the study. Study approval was obtained from the Ethics Committee of our institute.

Complete clinical details, physical examination, thyroid function test were obtained in each case. Ultrasonographic examination was carried out as and when required. FNAC was performed using the aspiration and non-aspiration technique under aseptic precautions with a 23-24 gauge needle on an outpatient basis. Air dried smears

were prepared and stained with Leishman stain and hematoxylin and eosin stain.

The Hamburger criteria were used to establish adequacy of the samples. This required identification of 6 clusters of cells in at least 2 slides which were prepared from separate aspirates [10].

The various cytomorphologic features, predominant cell pattern with special attention to the presence of MVs around the edges of aggregates of follicular cells were noted.

The MVs were graded based on the criteria given by Nilsson G et al. [11].

1. No/scanty MVs / (grade I): Distinct MVs seen in <10% of the cells
2. Moderate MVs / (grade II): MVs observed in 10-50% of the cells.
3. Abundant MVs / (grade III): MVs in >50% of the cells.

Depending on the values of the thyroid function test, the patients were categorized as euthyroid, hyperthyroid and hypothyroid

The presence and degree of grading of MVs was then correlated individually with the FNAC diagnosis and thyroid functional status of the patient.

Statistical evaluation was done using SPSS version 15.0 (LEAD Technologies, Inc., Charlotte, North Carolina, USA). The Chi-square test was applied to study the correlation between MVs with cytological diagnoses and thyroid hormonal status. A $P \leq 0.05$ and a $P \leq 0.01$ were considered significant or highly significant respectively.

Results

The study evaluated 76 cases of diffuse thyroid enlargement. There were 61 (80.3%) females and 15 (19.7%) males with a male to female ratio of 1:4.1.

The age group of the patients varied from 18-75 years with a mean age of 38.92 years. Maximum number of cases was in third and fourth decade with 20 and 18 cases respectively.

There was no statistical significant association between age/sex and the presence of MVs.

Detailed cytomorphologic features were examined with special attention to presence and grading of MVs at the periphery of follicular cells.

The aspirates of primary hyperplasia were cellular and showed blood-stained smears with little colloid and hyperplastic follicular cells in sheets and clusters. The cytology specimen of colloid goiter showed follicular epithelial cells arranged in monolayer sheets against a background of abundant thick and thin colloid with and macrophages. Smears of Hashimoto thyroiditis revealed scanty colloid with follicular cells, Hurthle-cells, small lymphocytes and few plasma cells [12]. Based on these observations the lesions were categorized as Hashimoto's thyroiditis, colloid goiter, and primary hyperplasia (Table 1).

It was observed that Hashimoto's thyroiditis accounted for nearly half the cases 51.3% followed by colloid goiter with 27.6% and 21.1% cases of primary hyperplasia.

On examining the association of MVs with cytological diagnosis, it was observed that abundant MVs (Figure 1) occurred in Primary hyperplasia 10 of 15 (66.7%) and Hashimoto's thyroiditis 5 of 15

(23.3%). This association between abundant MVs and primary hyperplasia was highly significant ($P < 0.001$).

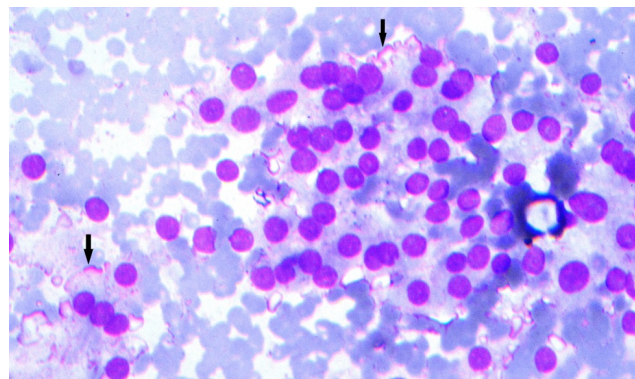


Figure 1: Follicular epithelial cells showing abundant MVs (arrows) in primary hyperplasia (Leishman stain, x100).

Moderate MVs (Figure 2) were predominant in Hashimoto's thyroiditis 15 of 21 (71.4%).

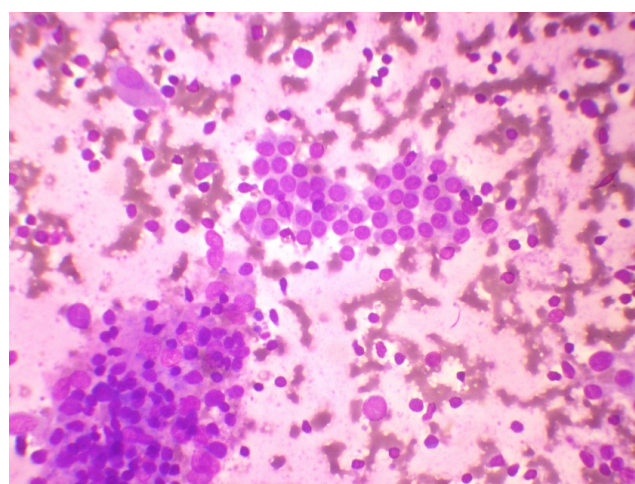


Figure 2: Moderate marginal vacuoles (arrow) in cytology smear of Hashimoto's thyroiditis (Leishman stain, x100).

Abundant MVs were absent in colloid goiter of all the colloid goiter patients, 85.7% had scant (Figure 3) to no MVs in their aspiration cytology smears. Three cases (14.3%) which showed moderate MVs were those in which abundant colloid was also present. A significant association was observed between the absence of abundant MVs and colloid goiter (Table 1).

Thyroid function tests of the cases revealed that majority were euthyroid 41 (54%) followed by 24 (31.6%) cases hyperthyroid and 11 (14.4%) were hypothyroid. Observation of the thyroid function association with MVs revealed abundant MVs in hyperthyroid 11 of 15 (73.3%) followed by euthyroid 4 of 15 (26.7%). There were no abundant MVs detected in hypothyroid cases. Thus, there was an overall significant association in all three hormonal groups with presence of MVs ($P = 0.03$) (Table 2).

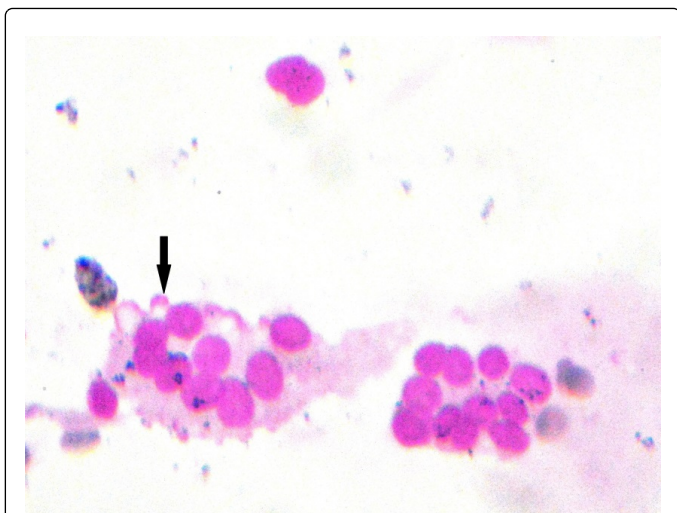


Figure 3: Scanty marginal vacuoles (arrow) in follicular epithelial cells of colloid goiter (Leishman stain, x100).

Diagnosis	Abundant MVs (%)	Moderate MVs (%)	No/Scant MVs (%)	Total
Hashimoto's thyroiditis	5 (23.3)	15 (71.4)	19 (47.5)	39 (51.3)
Colloid goiter	0	3 (14.3)	18 (45)	21 (27.6)
Primary hyperplasia	10 (66.7)	3 (14.3)	3 (7.5)	16 (21.1)
Total	15 (100)	21 (100)	40 (100)	76 (100)

Chi-square =31.4, d.f =4, P<0.001

Table 1: Association of marginal vacuoles with cytological diagnosis.

Thyroid function	Abundant MVs (%)	Moderate MVs (%)	No/scant MVs (%)	Total
Euthyroid	4 (26.7)	12 (57.1)	25 (62.5)	41 (54)
Hyperthyroid	11 (73.3)	5 (23.8)	8 (20)	24 (31.6)
Hypothyroid	0	4 (19.1)	7 (17.5)	11 (14.4)
Total	15 (100)	21 (100)	40 (100)	76

Chi-square =15.8, d.f =4, P=0.03

Table 2: Association of marginal vacuoles with thyroid function.

A large majority of the Hashimoto's thyroiditis was euthyroid, around 75% and over 25% were hypothyroid. Amongst the patients with colloid goiter more than 50% were euthyroid followed by hyperthyroid around 40% and hypothyroid close to 5%. Among primary hyperplasia, there were 93.7% hyperthyroid and 6.3% euthyroid cases (Table 3).

Discussion

Marginal vacuoles or "fire-flares" in Diff-Quick type Romanovsky stains was initially described as a distinctive feature of thyroid hyperfunction on FNA smears in the classical aspiration cytology book

by Orell et al. [12]. However, their frequency can also be high in non-toxic thyroid lesions like Hashimoto's thyroiditis and colloid goiters [6]. We observed similar findings in our study.

Thyroid function	Hashimoto's thyroiditis (%)	Colloid goiter (%)	Primary hyperplasia (%)	Total
Euthyroid	29 (74.4)	11 (52.4)	1(6.3)	41(53.9)
Hyperthyroid	0	9 (42.9)	15 (93.7)	24(31.6)
Hypothyroid	10 (25.6)	1 (4.7)	0	11(14.5)
Total	39 (100)	21 (100)	16 (100)	76(100)

Chi-square =49.6, d.f =4, P<0.001

Table 3: Correlation of thyroid function with type of thyroid disease category.

In our study, it was observed that abundant MVs were present in over 66% of primary hyperplasia. Thirteen of 16 cases (81.3%) of primary hyperplasia showed presence of abundant to moderate degree of MVs in their smears. In the earlier published studies abundant MVs were present in 40-70% cases of primary hyperplasia and over 80% of these revealed significant MVs [11,13,14]. Results of our study are comparable with these earlier studies.

Regarding the association between the presence of MVs in Hashimoto's thyroiditis, significant MVs (abundant + moderate) were detected in 20 of 39 cases (51.3%). On correlating this feature with thyroid function, it was found that around 75% were euthyroid and 25% were hypothyroid. In our study, none of the patients with Hashimoto's thyroiditis were hyperthyroid. This is in contrast to the findings of another study in which 29% cases were hyperthyroid [13]. This may be related to thyroxin replacement treatment.

It was postulated that MVs are manifestation of active pinocytosis/ vacuoles containing thyroglobulin diffusing out of the cytoplasm of follicular cells en route to blood vessels [6].

Although, biochemically there was no case of hyperthyroid amongst Hashimoto's thyroiditis, yet over 23% showed abundant MVs on cytology. In addition, around 27% of euthyroid cases showed abundant MVs on cytology. Thus, presence of abundant MVs though indicates hypersecretory toxic goiters, may be seen in euthyroid. Possible explanation for this could be due to patients on medication. Drugs used for different non-thyroid conditions as well as certain anti-thyroid medications may influence the thyroid function and cause discordant cytomorphological patterns on aspiration smears [15].

Abundant MVs were not recorded in any case of colloid goiter in this study. Moderate MVs were present in 14.3% of colloid goiter cases. The results of our study are in fair agreement with other studies who reported MVs in 5.2% and 11% cases of colloid goiter [1,13]. Some studies have reported moderate MVs in 32.6% cases of nontoxic goiter [11].

Considering the correlation between abundant MVs in diffuse goiters and levels of thyroid hormone, some interesting observations emerged: None of these cases were hypothyroid; 26.7% of diffuse goiters with abundant MVs were euthyroid. Thus, this implies that the presence of abundant MVs does not necessarily indicate hyperfunctioning thyroid. Hyperthyroid cases constituted 73.3% of this group.

On a detailed search of the literature, there are only few studies correlating the density of MVs with thyroid function [13]. Correlation of MVs with various thyroid lesions, however, been reported [6,11,14].

On correlating moderate MVs in diffuse goiters and thyroid hormone levels, it was noted that a significant proportion of these were euthyroid (57%) followed by over 23% hyperthyroid and 19% hypothyroid. These results are comparable to other studies, where moderate MVs were reported in over 58% of euthyroid cases, 24% hyperthyroid and 17% were hypothyroid cases [13].

Regarding the correlation between the presence of no/scanty MVs in diffuse goiters and levels of the thyroid hormone, it was observed that euthyroid accounted for 62.5% cases. The majority of these cases belonged to the category of Hashimoto's thyroiditis and colloid goiter accounting for 47.5% and 45% cases, respectively. Hypothyroid cases accounted for 17.5% of the cases. All the hypothyroid cases were of Hashimoto's thyroiditis in which replacement of the gland with lymphoid follicles with glandular destruction and atrophy is known. We also encountered three cases of primary hyperplasia with biochemical evidence of hyperthyroidism but with no/scant MVs. This implies that even hyperthyroid cases may lack MVs. Scant MVs in diffuse goiters did not correlate with thyroid function.

Conclusion

Marginal vacuoles are a characteristic feature of toxic goiter. The presence of abundant "fire-flares" revealed a strong association with primary hyperplasia and hyperthyroid cases; but they can also be seen in patients with Hashimoto's thyroiditis and in euthyroid cases. MVs are infrequent in colloid goiter and do not correlate well with thyroid function. Further studies are needed on a larger sample size to corroborate the above conclusions because of the limited sampling size of the present study.

Acknowledgement

Our sincere gratitude to Dr. Sudhir Jadhav for his statistical assistance, Dr. Sourabh Paranjape for his assistance in microphotography, Mr Sakharam Taras for providing technical assistance and above all our patients for consenting to do this study.

References

1. Das DK, Khanna CM, Tripathi RP, Pant CS, Mandal AK, et al. (1999) Solitary nodular goiter. Review of cytomorphologic features in 441 cases. *Acta Cytol* 43: 563-574.
2. Afroze N, Kayani N, Hasan SH (2002) Role of fine needle aspiration cytology in the diagnosis of palpable thyroid lesions. *Indian J Pathol Microbiol* 45: 241-246.
3. Handa U, Garg S, Mohan H, Nagarkar N (2008) Role of fine needle aspiration cytology in diagnosis and management of thyroid lesions: A study on 434 patients. *J Cytol* 25: 13-17.
4. Bommanahalli BP, Bhat RV, Rupanarayan R (2010) A cell pattern approach to interpretation of fine needle aspiration cytology of thyroid lesions: A cyto-histomorphological study. *J Cytol* 27: 127-132.
5. Wartofsky L (2010) Increasing world incidence of thyroid cancer: increased detection or higher radiation exposure? *Hormones (Athens)* 9: 103-108.
6. Das DK (2006) Marginal vacuoles (fire-flare appearances) in fine needle aspiration smears of thyroid lesions: Does it represent diffusing out of thyroid hormones at the base of follicular cells? *Diagn Cytopathol* 34: 277-283.
7. Sharma M, Madan M, Bhasin TS, Manjari M, Piplani S, et al. (2015) Marginal vacuoles in thyroid lesions: A cytomorphological Study on Fine needle aspiration. *International Journal of Advanced Research* 3: 181-184.
8. Ramzy I (1990) *Clinical cytopathology and aspiration biopsy*. New York: Appelton and Lange.
9. Galera-Davidson H (1997) Diagnostic problems in thyroid FNAs. *Diagn Cytopathol* 17: 422-428.
10. Hamburger JI, Husain M (1988) Semiquantitative criteria for fine-needle biopsy diagnosis: Reduced false-negative diagnoses. *Diagn Cytopathol* 4: 14-17.
11. Söderström N, Nilsson G (1979) Cytologic diagnosis of thyrotoxicosis. *Acta Med Scand* 205: 263-265.
12. Jayaram G, Orell SR (2012) *Thyroid*. In: Orell SR, Sterrett GF. Orell and Sterrett's Fine Needle Aspiration Cytology. (5th eds.), Elsevier, Churchill Livingstone, New York.
13. Gupta A, Singhal M, Kalhan S, Gupta A, Singhal O, et al. (2013) Cytomorphologic significance of marginal vacuoles in diffuse thyroid enlargements. *J Cytol* 30: 125-129.
14. Jayaram G, Singh B, Marwaha RK (1989) Grave's disease. Appearance in cytologic smears from fine needle aspirates of the thyroid gland. *Acta Cytol* 33: 36-40.
15. Padhi S, Varghese R, Ramdas A, Singh K, Sahoo J, et al. (2011) Autoimmune Thyroiditis: Correlation of Cytomorphology with Drug History and Clinical Implications. *Thyroid Science* 6: CR1-5.

This article was originally published in a special issue, entitled: "Cytopathology", Edited by Borislav A. Alexiev, University of Maryland Medical Center, USA