

# Severe Calcification in the Abdominal Pocket of an Implantable Pulse Generator (IPG) in a Patient on Long-Term Hemodialysis

Sven Bamps<sup>1\*</sup>, Joost Dejaeger<sup>1</sup>, Ben Sprangers<sup>2</sup> and Tom Theys<sup>1</sup>

<sup>1</sup>Department of Neurosurgery, University Hospital Leuven, Belgium

<sup>2</sup>Department of Nephrology, University Hospital Leuven, Belgium

## Abstract

**Introduction:** Ectopic mineralization has been described in patients with end-stage renal failure managed with long-term hemodialysis. This study reports the first case of severe focal ectopic calcification in an implantable abdominal pulse generator pocket. The patient has a medical history of long-term hemodialysis and failed back surgery syndrome. The failed back surgery syndrome is treated with a spinal cord stimulator and an implantable pulse generator (IPG).

**Case report:** Severe ectopic calcification of an implantable abdominal pulse generator pocket was observed in a 58-year-old female patient undergoing IPG relocation. The patient had a medical history of long-term hemodialysis for end-stage renal failure. She is also known with a spinal cord stimulator and an IPG for failed low back surgery syndrome. Microbiological study was negative and histopathological analysis confirmed the presence of focal calcifications in the implantable abdominal pulse generator pocket and on the IPG itself.

**Discussion:** Extra-cellular matrix (ECM) calcification is highly prevalent in patients with end-stage renal failure. The exact mechanism remains unclear. Physiopathological disturbance in the calcium and phosphate homeostasis finally and a pro-inflammatory environment result in soft tissue.

**Conclusion:** This is to our knowledge the first case reported in the literature of dystrophic severe focal ectopic calcification in the abdominal pocket of an implantable pulse generator (IPG) in a patient on long-term hemodialysis. Pain physicians should be aware of this phenomenon.

**Keywords:** Calcifications; Implantable pulse generator

## Introduction

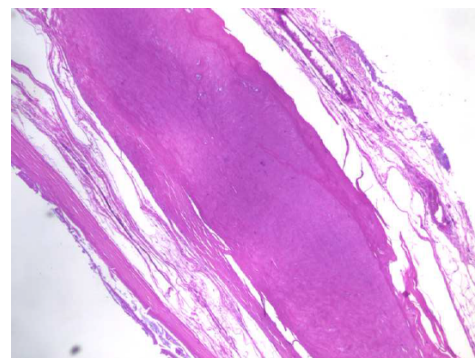
Ectopic mineralization has been described in patients with end-stage renal failure, especially in those receiving long-term hemodialysis. This study reports the first case of severe focal ectopic calcification in an implantable abdominal pulse generator pocket. The patient has a medical history of long-term hemodialysis and failed back surgery syndrome. The failed back surgery syndrome is treated with a spinal cord stimulator and an implantable pulse generator (IPG). The underlying mechanism is discussed.

## Case Report

A 58-year-old female patient with a history of end-stage renal failure resulting from reflux nephropathy is managed with long-term hemodialysis. The patient is also known with a spinal cord stimulator and an IPG for failed low back surgery syndrome. Due to an upcoming kidney transplantation a relocation of the IPG was necessary as the present IPG interfered with the surgical access to perform the transplantation in the left iliac fossa. The patient did not complain of pocket pain and there were no signs of systemic infection or inflammation. While performing the relocation a severe calcification with hard calcified plaques in the implantable abdominal pulse generator pocket and around the IPG were present (Figures 1 and 2). The lesions were firmly attached to the fascia. Furthermore there was presence of a white, milky, liquid not suggestive for pus in the abdominal pocket. The IPG was replaced to the contralateral side. To examine the calcified plaques and the white liquid, microbiological and histopathological examination was performed. The procedure went uneventful and the patient made a fast recovery. Microbiological study was negative and histopathological analysis confirmed the presence of focal calcifications in the implantable abdominal pulse generator pocket and on the IPG itself (Figures 3 and 4).

## Discussion

Extra-cellular matrix (ECM) calcification is highly prevalent in patients with end-stage renal failure. In more advanced stages of renal impairment, matrix calcification is more pronounced and severe. Intensive research in the past decades has greatly enhanced our



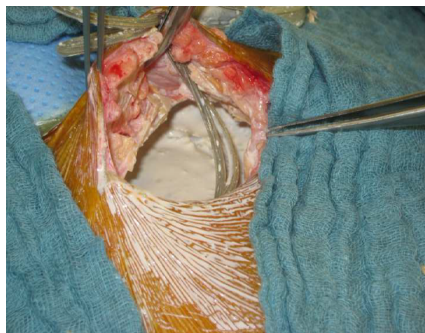
**Figure 1:** A severe calcification with hard calcified plaques in the implantable abdominal pulse generator pocket.

**\*Corresponding author:** Sven Bamps, Department of Neurosurgery, University Hospital Leuven, Belgium, Tel: +3216342861; E-mail: [sven.bamps@uzleuven.be](mailto:sven.bamps@uzleuven.be)

**Received** January 27, 2016; **Accepted** February 20, 2017; **Published** February 25, 2017

**Citation:** Bamps S, Dejaeger J, Sprangers B, Theys T (2017) Severe Calcification in the Abdominal Pocket of an Implantable Pulse Generator (IPG) in a Patient on Long-Term Hemodialysis. J Clin Case Rep 7: 923. doi: [10.4172/2165-7920.1000923](https://doi.org/10.4172/2165-7920.1000923)

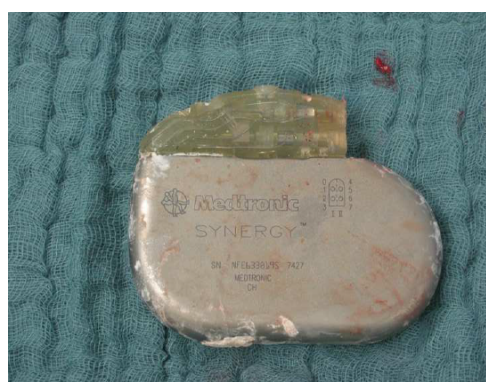**Copyright:** © 2017 Bamps S, et al. This is an open-access article distributed under the terms of the Creative Commons Attribution License, which permits unrestricted use, distribution, and reproduction in any medium, provided the original author and source are credited.



**Figure 2:** Relocation performance



**Figure 4:** Presence of focal calcifications in the implantable abdominal pulse generator pocket and on the IPG itself.



**Figure 3:** Microbiological study and histopathological analysis.

understanding of the numerous factors and mechanisms involved in ECM calcification in patients with chronic kidney disease, the exact mechanism remains unclear [1]. Disturbances in calcium and phosphate homeostasis manifested by hyperphosphatemia, hyperparathyroidism, elevated FGF-23, increased oxidative stress, and decreased calcification inhibitors such as fetuin-A and pyrophosphates are common in patients with end-stage renal failure. Phosphate probably initiates vascular calcification by activating *Runx2* leading to differentiation of mesenchymal cells into osteoblasts [2,3]. Hypercalcemia further stimulates this process [4]. Furthermore, FGF-23 and klotho decrease phosphate reabsorption and deficiency of klotho is associated with ECM calcification [5]. Increases in both local and systemic oxidative stress are closely associated with the development of vascular calcification in

CKD patients. In cell cultures, oxidative stress was found to upregulate of *Runx2* and initiate ECM calcification. Lastly, injured tissue predisposes to soft tissue calcification as injury initiates crystal nucleation and hydroxyapatite formation. Chronic inflammatory processes result in inflammatory cell infiltration and release of cytokines such as TNF- $\alpha$  [6, 7]. This inflammatory milieu will promote soft tissue calcification as happened in our patient.

#### References

1. Toussaint ND (2011) Extracellular matrix calcification in chronic kidney disease. *Curr Opin Nephrol Hypertens* 20: 360-368.
2. Jono S, McKee MD, Murry CE (2000) Phosphate regulation of vascular smooth muscle cell calcification *Circ Res* 87: E10-E17.
3. Byon C H, Javed A, Dai Q (2008) Oxidative stress induces vascular calcification through modulation of the osteogenic transcription factor Runx2 by AKT signaling. *J Biol Chem* 283: 15319-15327.
4. Shroff RC, McNair R, Skepper JN (2010) Chronic mineral dysregulation promotes vascular smooth muscle cell adaptation and extracellular matrix calcification. *J Am Soc Nephrol* 21: 103-112.
5. Hu MC, Shi M, Zhang J (2011) Klotho deficiency causes vascular calcification in chronic kidney disease. *J Am Soc Nephrol* 22: 124-136.
6. Tintut Y, Patel J, F (2000) Tumor necrosis factor- $\alpha$  promotes in vitro calcification of vascular cells via the cAMP pathway. *Circulation* 102: 2636-2642.
7. Tintut Y, Patel J, Territo M (2002) Monocyte/macrophage regulation of vascular calcification in vitro. *Circulation* 105: 650-655.