

# Safety and Efficacy of Laparoscopic Ventral Mesh Rectopexy and Sacrocolpopexy for Rectal Prolapse and Obstructed Defecation: Analysis of First 20 Cases at a UK District General Hospital

Athula Tennakoon\* and Golam Farook

Department of General Surgery, Sunderland Royal Hospital, Sunderland, United Kingdom

## Abstract

**Introduction:** Laparoscopic ventral mesh rectopexy (LVMR) is gaining wider acceptance. The aim of this study is to present that LVMR can be learnt and safely performed with short term results similar to that of establish centres.

**Materials and Methods:** All underwent anorectal physiology, defecation proctography, colon transit studies, colonoscopy or sigmoidoscopy as appropriate and pelvic floor MDT and biofeedback. Patients with high grade intussusception who did not respond to laxatives and biofeedback were offered LVMR. Surgical technique was as described by D'Hoore et al. and performed by both authors. Data are presented as median, range and proportions.

**Results:** Median age, ASA & BMI were 60.5 (34-78), 2 (1-3), 26.1 (20.4-33.1). Previous pelvic surgery included hysterectomy (35%), vaginal wall repair (15%) and rectal prolapse surgery (20%). 45% had Oxford prolapse grades 3/4 and rest were grade 5. Median operative time was 229 minutes (175-330). Synthetic mesh was used in 16 patients (Parietex 30%, TiLENE 50%) and Permacol in four (20%). 30 day mortality was zero. There were no conversions and overall complication rate was 10%. Sexual dysfunction was not reported. Median length of stay was 3 (2-6). 17 patients (85%) had 6 months or more follow up. Median patient reported outcome for satisfaction was 9.5 on a scale of 1 to 10 (2-10). Two patients developed recurrences of ODS at 6 and 12 months.

**Discussion and Conclusions:** We suggest that experienced laparoscopic surgeons can learn and safely perform laparoscopic ventral mesh rectopexy.

**Keywords:** Laparoscopy; Rectal prolapse; Intussusception; Pelvic floor disorder; Surgical mesh

## Introduction

Laparoscopic ventral mesh rectopexy (LVMR) is gaining wider acceptance amongst colorectal surgeons as the technique that can address symptoms of both external and internal rectal prolapse. It also allows correction of any associated rectocele, enterocele and posterior vaginal wall prolapse as well as vault prolapse. The learning curve for LVMR is unknown and there is no consensus on case selection. The aim of this study is to share our results to show that LVMR can be learnt and safely performed by experienced laparoscopic colorectal surgeons in district general hospitals with short term results similar to that of establish centres.

## Methodology

Prior to start of this retrospective study UK National Health Service Health Research Authority website was consulted and NHS Research Ethics Committee approval was not required. The procedures followed were in accordance with the principles of the Helsinki Declaration of 1975, as revised in 2000.

Laparoscopic Ventral Mesh Rectopexy was started at our institution in January 2011. All patients presented with obstructed defecation syndrome (ODS) and rectal prolapse from January 2011 to January 2015 are included in this analysis. Patients presenting to the out patients department with symptoms of difficulty in evacuation, sense of incomplete evacuation, pelleted stools, frequent visits to the toilet, perineal, vaginal or anal digitation, incontinence and pelvic pain were clinically diagnosed as having obstructed defecation. All with such symptoms were investigated with anorectal physiology, defecation proctography, colon transit studies, colonoscopy or sigmoidoscopy as appropriate. Patients with obvious rectal prolapse underwent either colonoscopy or sigmoidoscopy as indicated.

Fluoroscopic defecography was performed with vaginal, oral and bladder contrast. Defecography, anorectal physiology and symptoms were discussed in the fortnightly pelvic floor MDT which consists of two colorectal surgeons (both authors), one radiologist, the radiographer who performs defecography, one urogynaecologist and the colorectal nurse specialist who performs anorectal physiology and biofeedback. Fluoroscopy films were reviewed by all MDT members and intussusception was graded according to oxford prolapse grade [1] (Grade 1- High recto-rectal intussusception, Grade 2- Low recto-rectal intussusception, Grade 3- High recto-anal intussusception, Grade 4- Low recto-anal intussusception, Grade 5- Complete rectal prolapse). Evacuation time, number of attempts at evacuation and speed of opening of the anal canal were considered as subjective global markers of evacuation efficiency. In the case of rectocele barium trapping in the rectocele was considered significant. All patients with ODS then underwent maximal medical therapy as well as biofeedback. Since 2012 patients are offered trans anal irrigation as a form of conservative treatment if they do not respond to maximal medical therapy. Patients with high grade intussusception (Grade 3 and 4) and reduced

\*Corresponding author: Department of General surgery, Sunderland Royal Hospital Kayil Rd, Sunderland, SR47TP, NHS United Kingdom, Tel:+44-120544446179; Fax: +44-120544446413; E-mail: [athula@hotmail.co.uk](mailto:athula@hotmail.co.uk)

Received January 19, 2016; Accepted February 27, 2016; Published March 05, 2016

**Citation:** Tennakoon A, Farook G. Safety and Efficacy of Laparoscopic Ventral Mesh Rectopexy and Sacrocolpopexy for Rectal Prolapse and Obstructed Defecation: Analysis of First 20 Cases at a UK District General Hospital. Journal of Surgery [Jurnalul de chirurgie]. 2016; 12(1): 09-12 DOI:[10.7438/1584-9341-12-1-3](https://doi.org/10.7438/1584-9341-12-1-3)

**Copyright:** © 2016 Tennakoon A. This is an open-access article distributed under the terms of the Creative Commons Attribution License, which permits unrestricted use, distribution, and reproduction in any medium, provided the original author and source are credited.

evacuation efficiency who did not respond to maximal medical therapy and biofeedback or did not respond to trans anal rectal irrigation were offered LVMR.

Surgical technique was as described by D'Hoore et al. [2] and was performed by both authors who are experienced laparoscopic colorectal surgeons. The senior author (GF) had visited Bristol pelvic floor centre prior to offering LVMR at our Hospital.

We initially used lightweight monofilament polyester mesh (Parietex™) 4×20 cm. This was later changed to Titanium coated lightweight polypropylene mesh (TiLENE®) 4 × 20 cm for older patients or for patients who had completed the family. 4 cm ×18 cm × 1 mm biological mesh (Permacol™) was used in young patients and in patients who are in reproductive age. Length of the mesh was adjusted by cutting it intracorporeally if required, to an appropriate length to allow the distal length to reach the pelvic floor and the proximal end to be fixed to the sacral promontory without any tension. The suturing was intracorporeal and Ethibond Excel®2/0 was used to attach the mesh to the rectum. Vicryl® 2/0 was used for colpopexy and ProTack™ 5 mm for attaching the mesh to the sacral promontory. Excision of the pouch of Douglas was performed when an enterocele was present. Peritoneum was closed with continuous 2/0 Vicryl covering the mesh completely.

Data concerning demographics, operative data, complications, length of stay, recurrence and patient reported outcome were gathered from a prospective data base. Data were analysed using SOFA statistical software and are presented as median, range and proportions.

## Results

All twenty patients were females with median age of 60.5 (range 34-78). The cohort's median body mass index was 26.1 (range 20.4-33.1) (Figure 1A and B). The median ASA grade was 2 (range 1-3) and most belonged to ASA 2.

Majority of the patients did not have previous pelvic surgery or prolapse surgery prior to LVMR. Seven patients (35%) had hysterectomy or suture Sacrocolpopexy. Three patients (15%) had vaginal prolapse surgery and four patients (20%) had recurrent rectal prolapse. Five patients (25%) were having middle compartment prolapse whereas eight (40%) had rectocele and five patients had enterocele at the time of surgery (Table 1).

Nine patients (45%) underwent LVMR for obstructive defecation due to high grade intussusception and 11 patients (55%) had complete rectal prolapse. Most patients (80%) underwent synthetic mesh

rectopexy whereas four patients (20%) had a biologic mesh (Figure 2).

All operations were successfully completed laparoscopically without need for open conversion. 30 day mortality was zero. Overall complication rate was 10% (one wound infection and one port site hernia). No intraoperative complications occurred. Mesh related complications and sexual dysfunction were not reported during the period of follow up. Median operative time was 229 minutes (175-330) and median length of stay was 3(2-6) (Figure 3(A,B)). Total 17 patients (85%) had 6 months or more follow up (range 2 weeks-4 years). One patient developed recurrence of rectal prolapse after 1 year of follow up. One patient who had biological mesh for ODS developed recurrent symptomatic intussusception as well as new onset anterior and posterior vaginal prolapse after 6 months. Median patient reported satisfaction was 9.5 (range 2-10) (Figure 3(C)).

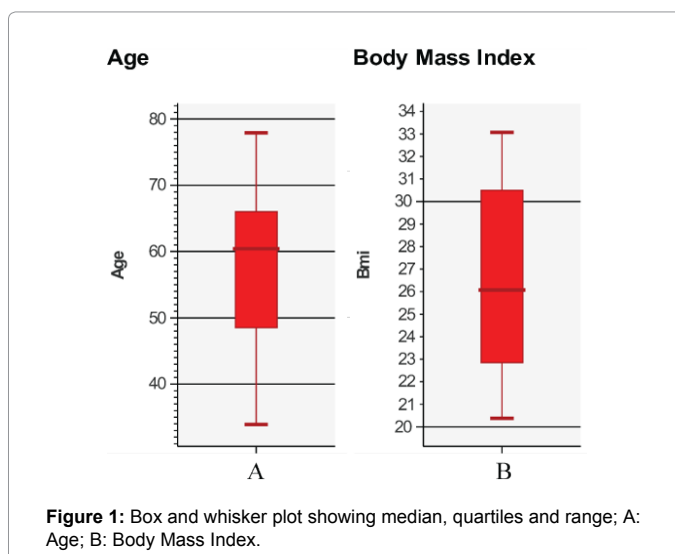## Discussion

Laparoscopic ventral mesh rectopexy is now considered safe and effective and results of large case series from tertiary centres [3-5] and systematic reviews [6,7] support this view. To our knowledge so far results of LVMR from a district general hospital in the UK has not been published. Our results in this series support that LVMR for rectal prolapse and ODS can be performed safely and effectively in a district general hospital.

Rectal prolapse and ODS is profoundly debilitating disease mainly involving older age group who are not willing to travel far for investigation and treatment. Having a pelvic floor service locally would greatly enhance delivery of good quality patient care.

We are aware of several controversies surrounding the increasing use of LVMR. There are no randomized controlled trials regarding this procedure for external rectal prolapse or ODS. No studies have been identified which compare LVMR with other surgical treatments, non-surgical treatments, or sham/no treatment for external rectal prolapse or ODS. DELivAR (Delorme's vs anterior rectopexy), a multicentre UK Health Technology Assessment commissioned randomized trial of Delorme's procedure compared with laparoscopic anterior rectopexy for external rectal prolapse is being set up and should provide the definitive answer. Restoration of normal anatomy was considered to be a definition of success, but this concept may be wrong. If ODS is caused by dysfunction of motility and sensitivity in the rectosigmoid, restoration of anatomy may only have a placebo effect. A clear correlation between surgical correction of the anatomical abnormalities and improvement in ODS has not been demonstrated. However in this series our patient selection was highly selective and guided by complete preoperative investigations, multidisciplinary discussion and maximal medical therapy. We believe this approach is essential to answer these uncertainties and controversies. Recently a panel of experts published a consensus statement [8] regarding ventral mesh rectopexy and our practice is almost consistent with the recommendations except we use permanent suture (Ethibond Excel®2/0) material to fix the mesh to the anterior rectum.

The choice of the prosthetic to be used in ventral mesh rectopexy is the remaining area of controversy. The relatively low costs of the synthetic prosthetics are attractive, but there are safety concerns with synthetic meshes and polyester mesh appears to be associated with increased mesh related complications and its use is discouraged. Biological meshes have been shown to be safe and effective. However number of biological meshes used are small and the long-term efficacy of biological materials in pelvic floor repair has yet to be defined [8,9]. The increased cost of the bio prosthetics is also of concern [10-13]. Long-term evidence and well-powered randomized trials are needed to fully define the roles of the various meshes in



**Figure 1:** Box and whisker plot showing median, quartiles and range; A: Age; B: Body Mass Index.

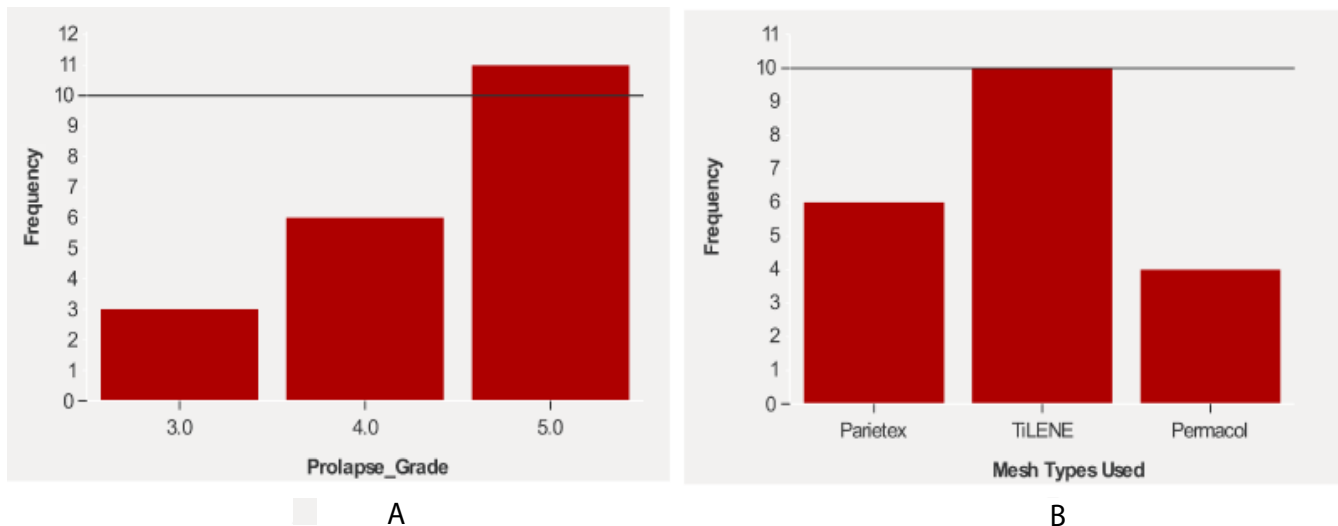


Figure 2: Bar charts of prolapse grade and type of meshes; A: Prolapse grades of patients who underwent LVMR; B: Types of meshes used in LVMR.

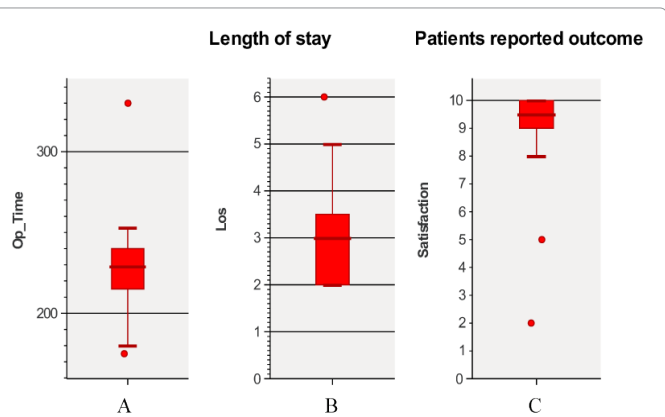


Figure 3: Box and whisker plot showing median, quartiles and range; A: Operative time (minutes); B: Length of Stay (days); C: Patient reported satisfaction on a scale of 1 to 10.

ventral mesh rectopexy.

There is no consensus on the learning curve which is assumed to be considerable, one study suggesting between 80 to 100 cases [8,9]. We do support the view that dissection in the pelvis and particularly suturing in the pelvis are demanding and require advanced laparoscopic skills. We believe that the learning curve for all the surgeons is not necessarily the same and laparoscopic technology has improved considerably and learning LVMR is more straightforward. Short term results in our series are similar to that of tertiary centres. However the median operating time and median length of stay are much longer. This reflects the fact that both operating surgeons were in their learning curve. It's also due to the fact that we took extreme care when dissecting the rectovaginal plane to avoid injury to either rectum or the vagina which would increase the risks associated with the mesh. Additionally our practice of intracorporeal suturing of the mesh contributed to the longer median operating time. There is now evidence that day case LVMR is safe and achievable [14].

There are number of limitations in this series. Follow up period is short and numbers are small. Although patient's satisfaction is high this outcome measurement is subjective. LVMR is now accepted as safe procedure that can effectively address the symptoms of rectal prolapse and obstructive defecation. There are evidence to support the view that LVMR is safe in the elderly [15] and can be performed safely in the

emergency setting. Symptoms improvement needs to be assessed objectively using validated symptoms questionnaires preoperatively as well as during follow up [16]. Therefore we have recently started using Longo's validated obstructive defecation symptom score and wexner faecal incontinence score as disease specific objective assessment of symptom severity. To assess quality of life we now use The EuroQol Group's validated EQ-5D health questionnaire. There are no published results of studies that have assessed long term quality of life using validated quality of life questionnaires. One study [17] has published quality of life using the French validated version of the gastrointestinal quality of life form (GIQLI) and shown improved quality of life at 1 year.

**Conclusion**

LVMR can be learnt and performed safely by experienced laparoscopic colorectal surgeons with relatively straightforward

Table I: Summary of previous pelvic surgery and defecography findings.

	Type	Frequency	% ¶
<b>Previous Surgery</b>			
Pelvic Surgery	Hysterectomy	6	30%
	Suture Sacrocolpopexy	1	5%
	No Surgery	13	65%
Vaginal Prolapse	Anterior + Posterior Repair	3	15%
	No Surgery	17	85%
Rectal Prolapse	Delorme's Procedure	2	10%
	Laparoscopic Suture Rectopexy	2	10%
	No Surgery	16	80%
<b>Defecography</b>			
Rectocele	Small	2	10%
	Moderate	4	20%
	Large	2	10%
	None	12	60%
Enterocele	Present	5	25%
	None	15	75%
Middle Compartment	Uterine Prolapse	1	5%
	Anterior Vaginal Wall Prolapse	1	5%
	Posterior Vaginal Wall Prolapse	1	5%
	Anterior + Posterior Wall Prolapse	2	10%
	None	15	75%

¶ denotes proportions as percentages.

learning curve. We believe best outcome can be achieved when patients are managed and selected for operative intervention in a multidisciplinary setting. We strongly support the view that outcome reporting contributes greatly to achieve quality surgical care.

#### Conflict of interest

None of the authors have any financial arrangement or other relationship that could be construed as a conflict of interest.

#### References

- Collinson R, Cunningham C, Costa DH, Lindsey I (2009) Rectal intussusception and unexplained faecal incontinence: findings of a proctographic study. *Colorectal Dis* 11: 77-83
- D'Hoore A, Penninckx F (2006) Laparoscopic ventral recto(colpo) pexy for rectal prolapse: surgical technique and outcome for 109 patients. *Surg Endosc* 20: 1919-1923.
- Randall J, Smyth E, McCarthy K, Dixon AR (2014) Outcome of laparoscopic ventral mesh rectopexy for external rectal prolapse. *Colorectal Dis* 16: 914-919.
- Evans C, Stevenson AR, Sileri P, Mercer-Jones MA, Dixon AR, et al. (2015) A Multicentre Collaboration to Assess the Safety of Laparoscopic Ventral Rectopexy. *Dis Colon Rectum* 58: 799-807.
- Slawik S, Soulsby R, Carter H, Payne H, Dixon AR, et al. (2008) Laparoscopic ventral rectopexy, posterior colporrhaphy and vaginal sacrocolpopexy for the treatment of recto-genital prolapse and mechanical outlet obstruction. *Colorectal Dis* 10: 138-43.
- Gouvas N, Georgiou PA, Agalianos C, Tan E, Tekkis P, et al. (2015) Ventral colpoporectomy for overt rectal prolapse and obstructed defaecation syndrome: a systematic review. *Colorectal Dis* 17: 34-46.
- Samaranayake CB, Luo C, Plank AW, Merrie AE, Plank LD, et al. (2010) Systematic review on ventral rectopexy for rectal prolapse and intussusception. *Colorectal Dis* 12: 504-512
- Mercer-Jones MA, D'Hoore AD, Dixon AR (2014) Consensus on ventral rectopexy: report of a panel of experts. *Colorectal Dis* 16: 82-88.
- Mackenzie H, Dixon AR (2014) Proficiency gain curve and predictors of outcome for laparoscopic ventral mesh rectopexy. *Surgery* 156: 158-167.
- Wahed S, Ahmad M, Mohiuddin K (2012) Short-term results for laparoscopic ventral rectopexy using biological mesh for pelvic organ prolapse. *Colorectal Dis* 14: 1242-1247.
- Smart NJ, Pathak S, Boorman P, Daniels IR (2013) Synthetic or biological mesh use in laparoscopic ventral mesh rectopexy. A systematic review. *Colorectal Dis* 15: 650-654.
- Smart NJ, Bryan N, Hunt JA (2012) A scientific evidence for the efficacy of biologic implants for soft tissue reconstruction. *Colorectal Dis suppl* 3: 1-6.
- Franceschilli L, Varvaras D, Capuano I, Ciangola CI, Giorgi F, et al. (2015) Laparoscopic ventral rectopexy using biologic mesh for the treatment of obstructed defaecation syndrome and/or faecal incontinence in patients with internal rectal prolapse: a critical appraisal of the first 100 cases. *Tech Coloproctol* 19: 209-219.
- Powar MP, Ogilvie JW, Stevenson AR (2013) Day-case laparoscopic ventral rectopexy: an achievable reality. *Colorectal Dis* 15: 700-706.
- Gultekin FA, Wong MT, Podevin J, Barussaud ML, Boutami M, et al. (2015) Safety of laparoscopic ventral rectopexy in the elderly: results from a nationwide database. *Dis Colon Rectum* 58: 339-343.
- Bloemendaal AL, Mishra A, Nicholson GA, Jones OM, Lindsey I, et al. (2015) Laparoscopic rectopexy is feasible and safe in the emergency admission setting. *Colorectal Dis* 17: 198-201.
- Maggiori F, Bretagnol M, Ferron Y, Panis (2013) Laparoscopic ventral rectopexy: a prospective long-term evaluation of functional results and quality of life. *Tech Coloproctol* 17: 431-436.