

Role of Radiotherapy in Primary Spinal Canal Tumors

Mahadev P*

Radiation Oncology, Apollo Hospitals, Chennai, India

*Corresponding author: Mahadev P, Senior Consultant, Radiation Oncology, Apollo Hospitals, Chennai, India, Tel: 9003239303; E-mail: mahadev62@gmail.com

Rec date: April 05, 2014; Acc date: April 29, 2014; Pub date: May 03, 2014

Copyright: © 2014 Mahadev P. This is an open-access article distributed under the terms of the Creative Commons Attribution License, which permits unrestricted use, distribution, and reproduction in any medium, provided the original author and source are credited.

Abstract

Primary spinal canal tumors are a diverse group of neoplasms constituting 4% of all central nervous system tumors. They can be broadly classified into intradural and extradural tumors. MRI is the most useful neuroimaging modality. A histopathology is mandatory in most of the cases. The primary modality of treatment is surgery. No adjuvant treatment is required if a complete excision can be done. However, in a significant number of patients, complete excision may not be feasible in view of the possibility of significant neurological complications. Hence, external radiotherapy plays an important role in the management of these neoplasms. Radiotherapy may be given as a definitive treatment or more commonly as an adjuvant. Advancements in technology have made the delivery of high precision radiotherapy like three-dimensional conformal radiotherapy, intensity modulated radiotherapy and stereotactic radiosurgery feasible and safe. The favourable prognostic features are feasibility of achieving a complete resection, low grade, caudal location, small volume disease and histology.

Keywords: Primary spinal tumors; Radiotherapy; Radiation myelitis

Introduction

Primary spinal canal tumors are rare entities but can have potentially catastrophic consequences because of their critical location. They constitute about 4% to 6% of all primary CNS (central nervous system) tumors. The incidence increases with age and the peak incidence is seen in patients above 65 years [1].

Primary spinal canal tumors can be broadly classified by the tumor location in relation to the dura – intradural and extradural. Intradural tumors can be further sub classified into intradural intramedullary and intradural extramedullary. 75% and 25% of intradural tumors are extramedullary in adults and children respectively. The common histologies seen in extramedullary tumors are the nerve sheath tumors, meningiomas, ependymomas, neurofibromas and schwannomas. Common intramedullary histologies are astrocytoma, ependymoma and hemangioblastoma. Astrocytomas are more likely to occur in the cervical and thoracic regions whereas ependymomas are commoner in the lumbosacral region with 40% of them occurring in the filum terminale. Majority of the astrocytomas in the pediatric age group are low grade and not infiltrative in nature. Most of these tumors are benign. Less than 10% of pediatric and 25% of spinal astrocytomas are malignant. Most of the extradural tumors are metastatic. However primary malignant nerve sheath tumors, soft tissue sarcomas, neuroblastomas, lymphomas and bone tumors like osteosarcomas and chondrosarcomas can arise in this site.

The symptoms largely depend upon the affected segment of the cord and are mainly due to compression of the cord and spinal nerves. The main cause of treatment failure is progressive local disease. CSF seedling, lymphatic and hematogenous spread is extremely uncommon and the major cause of death in these patients is infection and respiratory compromise secondary to paraplegia or quadriplegia.

MRI (magnetic resonance imaging) with gadolinium contrast remains the neuroimaging modality of choice with CT (computerized

tomographic) scans and angiography contributing important information in certain selected cases. A tissue diagnosis is mandatory before radiotherapy in suspected primary spinal tumors as differential diagnosis include many benign conditions like amyotrophic lateral sclerosis, syringomyelia and viral myelitis. The only situation in which emergency radiotherapy may be considered without histopathology is impending spinal cord compression not amenable to surgery because of medical contraindications. A special informed condition should be taken from the patient after explaining the pros and cons.

Principles of Radiotherapy

External radiotherapy forms an important modality in the management of primary spinal canal tumors. The aim of radiotherapy is to improve disease control, survival and improve neurologic function thereby improving quality of life. It can be used as the primary or definitive modality, adjuvant or a recurrent/palliative scenario. The commonest use is in the adjuvant setting after a subtotal resection. If surgery is not possible, radical radiotherapy with or without chemotherapy after a biopsy is a reasonable alternative. In some instances, short course of palliative radiotherapy can be given for symptomatic relief. Another scenario where radiotherapy can be sparingly used is in re-irradiation if there is a gap of at least more than 3 years after the initial irradiation. This choice should be used only if there is no other alternative for local control after fully explaining to the patient that there may not be any neurological improvement.

The treatment of choice for most intradural extramedullary tumors is a complete excision without producing significant neurological morbidity. As most of them like the nerve sheath tumors and spinal meningiomas are well encapsulated, it is possible to achieve a total resection. Intramedullary tumors, on the other hand, pose a much more challenging task as many of these tumors are infiltrating. Attempt at complete resection may result in unacceptable morbidity. A sub-total resection should be attempted in such situations. In general, completely resected tumors do not require any adjuvant radiotherapy. Sub-totally resected tumors should be considered for

postoperative radiotherapy as they have a significant risk of recurrence and progression. Adjuvant radiotherapy should be avoided in pediatric patients even if only a sub-total excision has been done as most of them are slow growing tumors. Every attempt should be made to postpone radiotherapy as long as possible in pediatric patients, especially under the age of 6 years, as there can be significant late effects of radiotherapy. If a subtotal excision relieves the pressure symptoms adequately, observation alone with meticulous regular neurological examinations and MRI scans is a reasonable option. The tumor may take a couple of years to recur or progress and this time may allow normal vertebral growth to occur in a child in the crucial growing period. Either re-surgery or surgery followed by postoperative radiotherapy can be done when there is neurological deterioration or progression of the disease on neuro-imaging.

Value of immediate adjuvant radiotherapy in incompletely resected spinal astrocytomas is not clear. Guidetti et al have reported improved outcomes with adjuvant radiotherapy after sub-total excision of ependymomas [2]. Some studies have shown a dose response relationship in ependymomas with improvements in local control with total doses greater than 50 Gy [3,4].

The principles of radiotherapy treatment planning essentially remain the same irrespective of the intent of the treatment (primary/ adjuvant). There has been lot of technological advancements in the last two decades resulting in high precision radiotherapy. Radiotherapy has evolved from 2 dimensional to 3 dimensional conformal radiotherapy (3D CRT), intensity modulated radiotherapy (IMRT), image guided radiotherapy (IGRT), stereotactic radiosurgery (SRS) and stereotactic radiotherapy (SRT). This has resulted in more conformal dose distributions (Figure 1 and 2) with better normal tissue sparing and accurate treatment delivery. International commission on radiation units and measurements (ICRU) recommendations forms the basis of 3 dimensional radiotherapy treatment planning [5]. The following volumes have to be delineated on the planning CT scans of the patient taken in the treatment position. The gross tumor volume (GTV) is the gross tumor seen on the T1 enhancing abnormality on MRI or the nonenhancing tumor on T2/FLAIR images. After a complete excision, the tumor resection cavity without edema constitutes the GTV. The clinical target volume (CTV) should include the edema on a T2 weighted MRI with a margin of 1.5cm around the GTV to include any potential microscopic disease. A margin of 0.5 to 1cm is added to the CTV to account for any treatment set-up uncertainties and any variability in the edema in the treatment field during radiotherapy. Organs at risk (OAR) are critical structures like thyroid, heart, lungs, kidneys that should also be contoured by the radiation oncologist. Every effort should be made to reduce the dose to normal structures as low as possible without compromising the target dose. The dose is prescribed to the PTV with the 95% isodose line covering the volume. The recommended dose is 50.4 Gy in 28 fractions, 5 fractions a week for most astrocytomas and ependymomas. Chordomas, chondrosarcomas and meningiomas require slightly higher doses in the region of 60 Gy.

Prognostic Features

The major prognostic features are tumor resectability, histology, grade, location, extent of the tumor, age and the use of adjuvant radiotherapy. Ependymomas, which occur frequently in the distal spinal canal, have higher complete resectability rates than astrocytomas, which occur more cranially and are more infiltrative tumors. Hence patients with spinal ependymomas survive longer than

patients with spinal astrocytomas [6,7]. Myxopapillary subtypes have a better prognosis possibly because they are more amenable to surgery. Higher grade tumors have high failure rates with most malignant astrocytoma patients surviving less than a year. Low volume tumors have better survival.

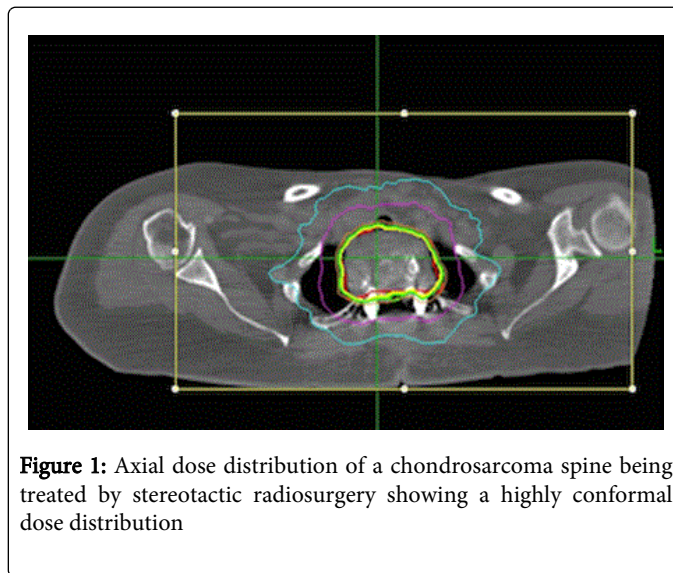


Figure 1: Axial dose distribution of a chondrosarcoma spine being treated by stereotactic radiosurgery showing a highly conformal dose distribution

Extensive tumors have more than 50% local failure rates even after surgery and radiotherapy whereas it is only 20% for small volume disease. Patients with fewer symptoms at diagnosis fare better than patients with extensive neurological symptoms. Younger age is normally associated with a better prognosis.

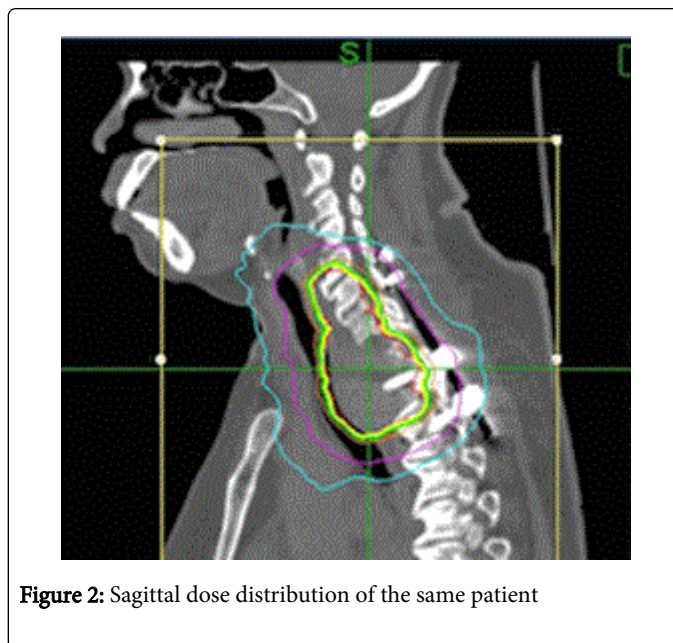


Figure 2: Sagittal dose distribution of the same patient

Results

There are no large published studies for giving firm treatment recommendations. Primary spinal canal neoplasms constitute a heterogeneous group of neoplasms with diverse treatment strategies. The 5 and 10-year survival figures for primary spinal astrocytomas

vary between 60-100% and 40-75% respectively. The same survival figures for spinal ependymomas vary between 66-100% and 62-91% respectively [8,9]. Intradural extramedullary tumors have an excellent prognosis, as recurrences are rare after complete excision.

Sequalae

The most feared complication of radiotherapy for spinal tumors is radiation myelopathy if the dose exceeds the tolerance of the spinal cord. The incidence of myelopathy with doses upto 50 Gy given in conventional fractionation is less than 0.5% and 1% to 5% after 60 Gy. However, it should be remembered that spinal cord is extremely sensitive to dose per fraction and hence radiation myelopathy incidence may be higher if the same total doses are delivered in shorter times i.e. hypofractionation. The total doses need to be reduced appropriately when hypofractionation is being used.

Radiation myelopathy may be acute or chronic. Acute myelopathy normally manifests within 2 to 6 months of radiotherapy, is reversible and does not progress to chronic myelopathy. It typically presents as L'Hermite's sign, characterized by sudden tingling, electric shock like sensation radiating to the hands and feet on neck flexion. It is self-limiting, does not require any treatment and may be due to transient demyelination of the spinal cord. Chronic myelopathy can occur months to years after radiation therapy. The mechanisms implicated are white matter injury with demyelination and / or microvascular injury. Chronic myelopathy may result in irreversible changes resulting in complete transection of the cord with total sensory and motor loss. The neurological signs should be related to the segment of the cord irradiated for a diagnosis of radiation myelopathy. The incidence of chronic irreversible myelopathy depends on the total dose, dose per fraction and the length of the cord irradiated. There is a 50% risk of myelitis when doses exceed 68 to 73 Gy.

Conclusion

Radiotherapy is an important tool in the overall management of primary spinal canal tumors. Surgery is the mainstay of treatment

whenever feasible and patients undergoing complete excision do not require adjuvant radiotherapy. In cases where radical surgery may result in neurological deterioration, a policy of subtotal resection or a biopsy followed by radiotherapy gives satisfactory results. At all times, the spinal cord tolerance to radiotherapy should be respected as very high doses can result in catastrophic consequences.

References

1. McCormick PC, Stein BM (1996) Spinal cord tumors in adults. In: Youman Jr, ed. Neurological surgery, Philadelphia: W.B.Saunders.
2. Guidetti B, Mercuri S, Vagnozzi R (1981) Long-term results of the surgical treatment of 129 intramedullary spinal gliomas. *J Neurosurg* 54: 323-330.
3. Kopelson G, Linggood RM, Kleinman GM, Doucette J, Wang CC (1980) Management of intramedullary spinal cord tumors. *Radiology* 135: 473-479.
4. Shaw EG, Evans RG, Scheithauer BW, Ilstrup DM, Earle JD (1986) Radiotherapeutic management of adult intraspinal ependymomas. *Int J Radiat Oncol Biol Phys* 12: 323-327.
5. International commission on radiation units and measurements, Inc. ICRU report 50, Prescribing, recording, and reporting photon beam therapy 50 1993. Bethesda, MD, Nuclear technology publishing.
6. Hardison HH, Packer RJ, Rorke LB, Schut L, Sutton LN, et al. (1987) Outcome of children with primary intramedullary spinal cord tumors. *Childs Nerv Syst* 3: 89-92.
7. Hulshof MC1, Menten J, Dito JJ, Dreissen JJ, van den Bergh R, et al. (1993) Treatment results in primary intraspinal gliomas. *Radiother Oncol* 29: 294-300.
8. Abdel-Wahab M1, Corn B, Wolfson A, Raub W, Gaspar LE, et al. (1999) Prognostic factors and survival in patients with spinal cord gliomas after radiation therapy. *Am J Clin Oncol* 22: 344-351.
9. Abdel-Wahab M1, Etuk B, Palermo J, Shirato H, Kresl J, et al. (2006) Spinal cord gliomas: A multi-institutional retrospective analysis. *Int J Radiat Oncol Biol Phys* 64: 1060-1071.