

## Role of Hyperbaric Oxygen Therapy in Management of Complicated Case of Fournier Gangrene to Improve Patient Outcome

Tarun Sahni<sup>1\*</sup> and Shiv Chopra<sup>2</sup>

<sup>1</sup>Department of Internal and Hyperbaric Medicine, Indraprastha Apollo Hospital, Delhi-Mathura Road, Sarita Vihar, New Delhi-110076, India

<sup>2</sup>Department of General and Gastrointestinal Surgery, Indraprastha Apollo Hospital, Delhi-Mathura Road, Sarita Vihar, New Delhi-110076, India

### Summary

Fournier's Gangrene is a life threatening urosurgical emergency and a synergistic gangrene of scrotum. It is a rapidly progressive & devastating form of necrotising fasciitis of perineal, perineum and genital area associated with high mortality and morbidity. Radical surgical debridement, broad spectrum antibiotics, negative pressure wound dressings and hyperbaric oxygen therapy are considered to be the cornerstone of treatment and contribute to improved outcomes.

We present a case of Fournier Gangrene in a 57 Year old male patient complicated by presence of rare multiple microbial which was successfully managed with early diagnosis, prompt measures and use of hyperbaric oxygen.

**Keywords:** Fournier gangrene; Necrotising fasciitis; Hyperbaric oxygen therapy; Vacuum assisted closure

### Introduction

Fournier Gangrene is acute, rapidly progressive and potentially fatal, infective necrotising fasciitis affecting external genitalia, perineal and perianal region [1-3]. It is characterised by a synergistic, polymicrobial necrotising fasciitis leading to the thrombotic occlusion of small subcutaneous vessels and the development of

Gangrene [4,5]. The disease affects all ages, both sexes and is more common in males. The predisposing factors which may contribute to development of disease are diabetes mellitus, alcoholism, malignancy, immunosuppression, liver or renal disease [3-7]. It is associated with high mortality rates, hence urgent, aggressive and effective treatment of this condition is imperative to prevent fatal outcome [8-10]. We report a case of 57 years old male patient suffering from Fournier gangrene who was successfully treated with broad spectrum antibiotics, early surgical debridement of necrotic tissues and adjunctive therapies such as Vacuum Assisted Closure (VAC) Therapy and Hyperbaric Oxygen Therapy (HBOT).

### Case Report

A 57 year old healthy male patient with five day history of fever, weakness, pain, swelling and pus discharge from his genital region presented to our unit. He denied recent trauma, and had no nausea, vomiting, abdominal pain or dysuria. He was a haemodynamically stable patient with no clinical abnormality. Local examination revealed a tender scrotum with palpable crepitations throughout. His scrotum was hard, swollen, erythematous and the left hemiscrotum was gangrenous revealing a patch of green black necrotic skin with foul odour (Figure 1, 2). Blood and urine cultures were negative and sputum cultures revealed *Klebsiella* species. Urea (62.5 mg%) and creatinine levels (0.9 mg%) was raised with random blood sugar levels of 340 mg%, though patient was non diabetic. A clinical diagnosis of Fournier gangrene was made and treatment with broad spectrum combination (meropenem, amikacin, teichoplanin and metronidazole) was initiated which was later adjusted to culture sensitivity of the microbial isolates. He underwent immediate scrotal exploration with extensive debridement of necrotic skin of scrotum and perianal region (Figure 3). The debrided tissue sample revealed acute suppurative inflammation with detection of *Escherichia coli*, *Staphylococcus aureus*, *Pseudomonas aeruginosa*, *Klebsiella* and *Aspergillus flavus*.

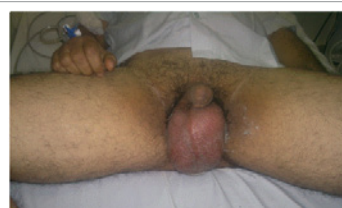


Figure 1: Initial Presentation showing oedema of scrotum.

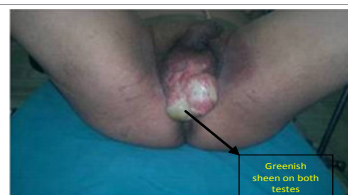

Figure 2: Progressive necrosis and greenish discoloration of scrotal skin.

He underwent five subsequent surgical debridements, with twice daily dressings (betadine/H<sub>2</sub>O<sub>2</sub>/eusol soaks/5% acetic acid soaks). His blood urea and serum creatinine came within normal range and on postoperative day 16, he was discharged home.

On postoperative day 21, both testicles showed greenish sheen with unhealthy granulation tissue and wound cultures identified strains of *Pseudomonas aeruginosa* and *Staphylococcus aureus*. Urine cultures revealed presence of *Candida albicans*. Polymicrobial and antifungal medications (voreticonazole, colistin) were added to the treatment regimen. Orchidectomy was not necessary.

Furthermore, patient underwent 10 days of VAC (kinetic concepts

**\*Corresponding author:** Dr. Tarun Sahni, Senior Consultant, Department Internal and Hyperbaric Medicine, Indraprastha Apollo Hospital, Delhi-Mathura Road, Sarita Vihar, New Delhi-110076, India, E-mail: [aimhu@live.in](mailto:aimhu@live.in)

Received June 01, 2012; Accepted July 14, 2012; Published July 16, 2012

**Citation:** Sahni T, Chopra S (2012) Role of Hyperbaric Oxygen Therapy in Management of Complicated Case of Fournier Gangrene to Improve Patient Outcome. J Clin Case Rep 2:172. doi:10.4172/2165-7920.1000172

**Copyright:** © 2012 Sahni T, et al. This is an open-access article distributed under the terms of the Creative Commons Attribution License, which permits unrestricted use, distribution, and reproduction in any medium, provided the original author and source are credited.

international, texas, USA) and 10 sessions of HBOT (at 2.40 ATA pressure for 90 minutes once daily) on postoperative day 25. On 36 days postoperatively, edema was resolved and infection was subsided with no need of further debridements (Figure 4).

All throughout patient was hemodynamically stable, ambulatory, pain free and afebrile. Patient was advised for scrotal reconstruction surgery, though he opted for the wound to heal by secondary intention with dressings at home. With regards to Diabetes Mellitus, blood glucose level remained within normal levels with diet control and oral hypoglycemic as the only treatment.

## Discussion

Fournier's gangrene is a rare and a rapidly progressive necrotizing fasciitis of the perineum and external genital organs affecting both men and women [1-3]. It is a polymicrobial infection complicated by presence of both aerobic & anaerobic organisms such as *Escherichia coli*, *Streptococcus pyogenes*, *Pseudomonas aeruginosa*, *Klebsiella pneumoniae*, *Proteus mirabilis*, *enterococci*, *Bacteroides fragilis* [4-7].

In our case, stabilization of the patient, usage of wide spectrum antibiotics, aggressive surgical intervention, VAC and hyperbaric oxygenation was the principle of management. Co morbid disease compromising the immune system of our patient was Diabetes Mellitus which was diagnosed accidentally during his presentation to our hospital.

Our case report discusses the supportive therapeutic value of HBOT and VAC in management of Fournier Gangrene. Their combination allows continuous improvement of local wound and persisting infection enabling final reconstruction. We report a case of Fournier gangrene complicated with presence of multiple aerobic & anaerobic microorganisms including rarely occurring *Pseudomonas aeruginosa*. A study published in New Zealand Medical journal says that majority of patients had a mixture of causative organisms while the most common single organism were *E.coli* followed by *Pseudomonas aeruginosa* and *Staphylococcus* [4]. *Pseudomonas aeruginosa* may cause soft tissue infections with peri-vasculitis secondary due to bacteraemia but it is rarely associated with necrotizing fasciitis [5,6].

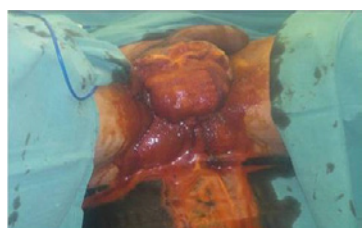

Figure 3: Intraoperative image of surgical debridement.

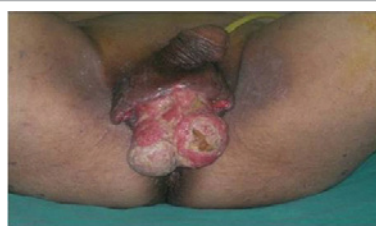

Figure 4: Postoperative image of demonstrating resolution of edema and appearance of granulation tissue.

In spite of intensive antibiotic therapy, his infection did not subside. We conducted 10 sessions of HBOT and had very good results as the bacterial count came down. Tayyab et al. [6] showed in the study involving 11 patients the positive effects of HBO in the treatment of Fournier's gangrene. HBOT provides oxygenation to ischemic areas, thus limiting the spread of infection and reducing the need for further debridement [5-7]. Hunt et al have demonstrated that oxygen adds to the effectiveness of antibiotics. In *Pseudomonas aeruginosa* infections HBO has an additive effect with antibiotics, reducing morbidity and mortality [10].

The effects of HBOT and VAC in management of infection in Fournier gangrene has been discussed in various studies in combination with antibiotics and has proved to be of value in treatment. HBOT have a direct toxic effect on anaerobic bacteria, increase wound perfusion and reduce bacterial contamination to optimize the wound bed for further intervention.

Many surgeons believe that faecal and urinary diversion is required to prevent wound contamination and is considered an integral part of management for patients requiring extensive debridement, especially if the infection arises in the anorectal region [8]. This case might have led to a severe and fast spreading necrotizing infection, but with early diagnosis, immediate surgery and HBOT, anorectal area was preserved and hence faecal diversion was not required. A routine urinary catheter was used.

In our patient, antibiotic therapy and adequate wound debridement were the mainstays of treatment but adjunctive use of HBOT and VAC proved to be optimal for wound bed preparation and also improved general well being.

## Conclusion

Our experience suggests consideration of association of surgical treatment; VAC therapy and sequential HBOT for this disease. We recommend more prospective clinical studies to be carried out to analyze this kind of approach in such life threatening disease.

## References

1. Lee CY, Kuo LT, Peng KT, Hsu WH, Huang TW, et al. (2011) Prognostic factors and monomicrobial necrotizing fasciitis: gram-positive versus gram-negative pathogens. BMC Infect Dis 11: 5.
2. Ooi A, Chong SJ (2011) Use of adjunctive treatments in improving patient outcome in Fournier's gangrene. Singapore Med J 52: e194-e197.
3. Janane A, Hajji F, Ismail TO, Chafiqi J, Ghadouane M, et al. (2011) [Hyperbaric oxygen therapy adjunctive to surgical debridement in management of Fournier's gangrene: usefulness of a severity index score in predicting disease gravity and patient survival]. Actas Urol Esp 35: 332-338.
4. Brown OR, Silverberg RG, Huggett DO (2011) Synergism between Hyperoxia and Antibiotics for *Pseudomonas aeruginosa*. Appl Microbiol 16: 260-262.
5. Papaconstantinou I, Yiallourou AI, Dafnios N, Grapsa I, Polymeneas G, et al. (2011) Successful Treatment of a Severe Case of Fournier's Gangrene Complicating a Perianal Abscess. Case Report Med.
6. Tayyab M, Aurangzeb M, Ahmad N, Saeed Q (2010) Fournier's Gangrene: A review of 15 cases. Journal of Postgraduate Medical Institute 24: 138-141.
7. Machado NO (2011) RETRACTION: Necrotizing fasciitis: The importance of early diagnosis, prompt surgical debridement and adjuvant therapy. N Am J Med Sic 3: 107-108.
8. Thompson ML, Martin C (2011) Management of necrotizing fasciitis infections. Orthopedics 34: 111-115.
9. Korhonen K, Klossner J, Hirn M, Niinikoski J (1999) Management of clostridial gas gangrene and the role of hyperbaric oxygen. Ann Chir Gynaecol 88: 139-142.
10. Hunt TK, Linsey M, Grisliis H, Sonne M, Jawetz E (1975) The effect of differing ambient oxygen tensions on wound infection. Ann Surg 181: 35-39.