

Robotic Pyeloplasty and Synchronous Removal of Many Kidney Stones: A Piece of Cake with Robotic Surgery

Abdullah Erdem Canda^{1*}, Ozer Ural Cakici², Ali Fuat Atmaca¹, Muhammed Ersagun Arslan² and Davut Kamaci²

¹Yildirim Beyazıt University, School of Medicine, Ankara Atatürk Training and Research Hospital, Department of Urology, Ankara, Turkey

²Ankara Atatürk Training and Research Hospital, Department of Urology, Ankara, Turkey

Abstract

Ureteropelvic junction obstruction is a common clinical entity in urological practice. The obstruction can result from intrinsic or extrinsic factors. The clinical course is variable due to degree of obstruction. Diagnose is usually made by contrast-enhanced excretory imaging modalities and nuclear scan. Open surgical, laparoscopic and robotic assisted laparoscopic approaches are the available surgical treatment options. In this case report, we present a congenital ureteropelvic junction obstruction treated with robotic assisted transperitoneal pyeloplasty with many intracalyceal stones surprisingly noticed during surgery and successfully treated in the same session.

Keywords: Robotic pyeloplasty; UPJ obstruction; Kidney stones

Introduction

Ureteropelvic junction (UPJ) obstruction (UPJO) is characterized by decreased or absent urine flow from renal pelvis to ureter. Its clinical result spectrum widens from asymptomatic course to total renal unit loss due to severity of obstruction. Partial obstructions allowing enough urine passage may have an asymptomatic course. It can be congenital or acquired. Acquired UPJ obstructions are usually due to stone disease, neoplastic tissues and post-inflammatory tissue reactions. Congenital UPJ obstruction can result from intrinsic or extrinsic causes. The most common intrinsic cause is presence of an aperistaltic segment. Patients with UPJ obstruction are more prone to urinary tract stone formation and concurrent stone disease with UPJ obstruction [1,2]. Treatment of UPJ obstruction depends on application of surgical techniques. Endoscopic, open and minimal invasive approaches have been described. Several different modalities are also available for the treatment of urinary stone disease. In this case report we present a congenital UPJ obstruction case with many intracalyceal stones surprisingly noticed during surgery and both of them were treated with robotic assisted laparoscopic approach.

Case Report

A 35 year-old female patient admitted to our outpatient clinic with right flank pain. Her kidney-ureter-bladder (KUB) X-ray was within normal limits without any calcification or opacity on the urinary tract (Figure 1a). Urine analysis revealed >50 leukocytes and urine culture was sterile. An ultrasonography (USG) for urinary tract and bladder was performed and grade 3 hydronephrosis with moderate parenchyma loss and 4-5 stones in 5 mm sized were reported in right kidney. An intravenous urography (IVU) and MAG-3 nuclear renal scan with intravenous furosemide revealed right ureteral obstruction at the UPJ level with T1/2>20 minutes. IVU demonstrated right hydronephrosis and extremely dilated calices and a huge right kidney (Figure 1b). Right robotic assisted laparoscopic transperitoneal pyeloplasty (RALP) was performed. Overall, 4 abdominal ports were used including the assistant port (Figure 2a).

In our case, we used da Vinci-S 4-arm surgical robot (Intuitive Surgical, Sunnyvale, CA). Before starting the surgery, our operating room nurse drapes all of the robotic arms with sterile drapes. Robotic 3D camera creates 3D images for the operating console surgeon. The da Vinci surgical system consists of five main components including an

ergonomically designed console where the surgeon sits while operating, a patient-side cart where the patient is positioned during surgery, interactive robotic arms, a 3D HD vision system, and proprietary surgical robotic instruments.

We reported our technique of RALP before in detail [3]. During surgery, contrary to the US report, when renal pelvis was opened, surprisingly we came across numerous small 5 mm sized stones that filled every calix and renal pelvis (Figure 2b). Dilated renal pelvis was excised and with the help of the robotic instruments, all of the stones were removed and every calix was cleared easily (Figure 3). Following 2 months, patient admitted with right flank pain. Non-contrast abdominal CT scan showed the kidney was stone-free. Urine analysis suggested infection that was treated with oral antibiotics

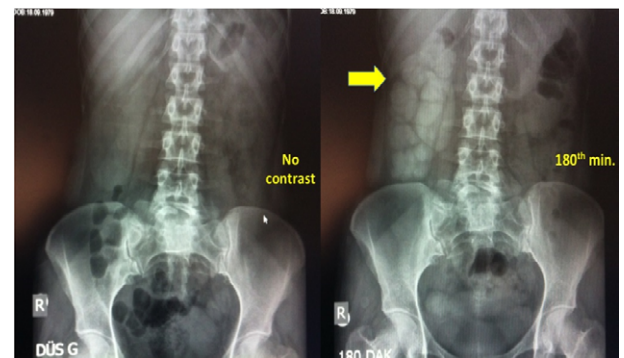

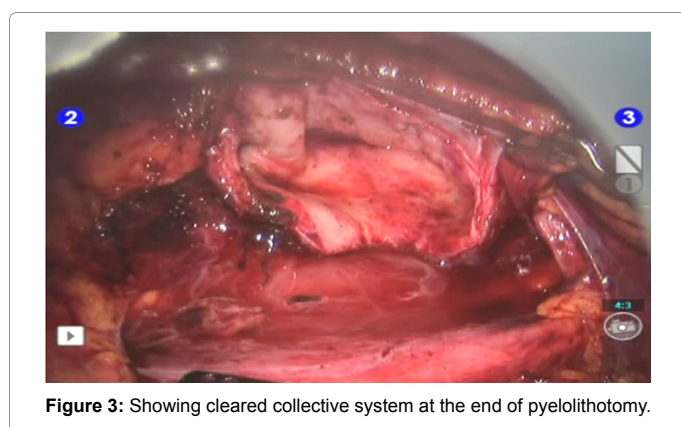
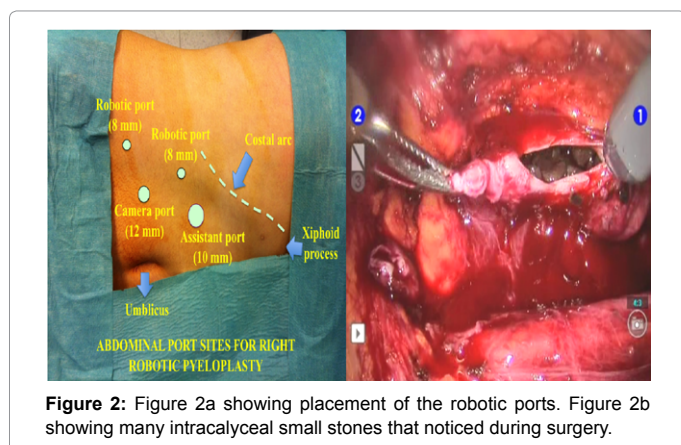
Figure 1: Figure 1a showing KUB X-Ray without any significant clinical findings. Figure 1b showing hydronephrosis in right kidney.

***Corresponding author:** Dr. Abdullah Erdem Canda, Associate Professor of Urology, Yildirim Beyazıt University, School of Medicine, Ankara Atatürk Training and Research Hospital, Department of Urology, Bilkent 06800, Ankara, Turkey, Tel: +90 312 324 15; E-mail: erdemcanda@yahoo.com

Received March 12, 2015; **Accepted** April 07, 2015; **Published** April 14, 2015

Citation: Canda AE, Cakici OU, Atmaca AF, Arslan ME, Kamaci D (2015) Robotic Pyeloplasty and Synchronous Removal of Many Kidney Stones: A Piece of Cake with Robotic Surgery. Adv Robot Autom 4: 129. doi: [10.4172/2168-9695.1000129](https://doi.org/10.4172/2168-9695.1000129)

Copyright: © 2015 Canda AE, et al. This is an open-access article distributed under the terms of the Creative Commons Attribution License, which permits unrestricted use, distribution, and reproduction in any medium, provided the original author and source are credited.



and her symptoms completely resolved. Postoperative third month MAG3 renal scan revealed significant improvement in renal excretory function. Her stone analysis was reported as amorph material.

Discussion

UPJO is the most common congenital anomaly of upper urinary tract and after widespread usage of antenatal ultrasound screening the time of diagnosis and clinical picture is evolved to prenatal era [4,5]. UPJO can be diagnosed in childhood or thereafter either incidentally or due to development of symptoms. UPJO should also be considered in the differential diagnosis of patients with recurrent urinary tract infections, acute flank pain, long-term existing dull flank pain, recurrent stone disease and also acute pyonephrosis. The diagnosis is usually based on imaging techniques and mercaptoacetyl triglycine (MAG-3) renal scintigraphy with intravenous diuretic. Ultrasound, IVU, CT-urography (CTU) or MR-urography (MRU) can be used for radiologic diagnosis. Ultrasound is usually used for antenatal screening and is indispensable in both follow-up and initial diagnosis of hydronephrosis. On the other hand, ultrasound is incapable of determining the exact localization of obstruction and is an operator dependent imaging modality. IVU is a common used imaging modality in the clinical assessment of upper urinary tract obstruction. Radiation exposure and low imaging quality because of superposition of bowel gases are main disadvantages [6]. Although used widespread, US and IVU can miss most of non-opaque and soft stones as happened in our case that might be a surprising situation to handle for the surgeon. Therefore, we think that preoperative CT is essential in all patients for detecting particularly non-opaque stones as happened in our patients.

CT-urography is also a highly valuable tool with high imaging quality. CTU is capable of revealing the localization and cause of the obstruction. CT scan can also be used for assessing the vascular structures such as presence of a crossing vessel in UPJ obstruction. Utilization of three-dimensional reconstruction is also valuable [7] and lower-dose CTU is a very sensible choice in young patients and children [8]. Radiation exposure is the main disadvantage of CT. On the other hand, MR-urography has high imaging quality with no radiation exposure and also capable of differentiate split renal function [9]. In paediatric population sedation is needed for MRU. In our patient we carried out surgery with preoperative IVU and MAG-3 renal scintigraphy. During surgery we were surprised by a high stone burden with many small intracalyceal stones. Keeping in mind the well known co-incidence of stone disease and UPJO [10] we suggest a preoperative NCE-CT scan for these patients before performing pyeloplasty. CTU can also be used for both assessment of stones and etiology of obstruction.

Surgery is the mainstay of UPJO management if the treatment is indicated. Since the first pyeloplasty for UPJO, open pyeloplasty has been the gold standard treatment. After first description in 1949, Anderson-Hynes dismembered pyeloplasty has become popular and has led to high success rates [11,12]. Pyeloplasty technique is also evolved with the rise of endourology. Outcomes of initial laparoscopic pyeloplasty cases [13,14] were reported by high volume centres in 1993. With the growing clinical evidence the success of laparoscopic repair for UPJO has become vivid and laparoscopic approach has a better cosmetic result with less morbidity compared to open surgery [15]. The main disadvantage of conventional laparoscopic pyeloplasty is the steep learning curve for successful laparoscopic suturing for reconstruction of ureteropelvic junction [11]. Therefore, robotic-assisted laparoscopic pyeloplasty (RALP) is utilized for UPJO treatment in the endourology era [16,17]. RALP has shown to be feasible, safe and can lead to successful clinical results for both primary and also as a salvage procedure [18-20]. RALP has also been shown to be successful even in the hand of surgeons without significant laparoscopic experience [21]. In our patient we preferred robotic-assisted laparoscopic approach because of its benefits in intracorporeal suturing and patients' preferences. Although conventional laparoscopic treatment for both kidney stones and UPJO was shown to be feasible [22], we suggest the utilization of robotic-assisted approach for this kind of patient considering the advantages including precise, gentle and quick tissue handling with 3D magnified image capability, higher grades of wristed hand movements and decreased hand tremor that gives the surgeon the opportunity of easily entering every distal calix and removal of all small sized stones leading to a stone-free state. In addition, robotic approach has the advantages of enabling quicker tissue dissection, reconstruction, intracorporeal suturing, antegrade double-J stenting and excellent ergonomics for the console surgeon. The main disadvantage of robotic approach might be increased cost that should also be considered [23]. Lastly, it is important to mention that, the credit goes to the surgical robot in most publications as a success story and the surgeon using the surgical robot is ignored. Although the surgical robotic system has the mentioned advantages, it is the operating surgeon that applies his/her skills and knowledge with his/her hands by using the robotic system in order to operate the patient that should not be forgotten.

Conclusions

We report a challenging case of UPJO with high small sized and soft stone burden in the renal pelvis and every calix that were noticed surprisingly during surgery. We suggest having preoperative non-contrast CT scan as an essential imaging modality for this patient group.

Our experience demonstrates that robotic approach is a safe minimally invasive procedure that has excellent surgical and functional outcomes that enables the surgeon to perform reconstructive surgery including excision of the dilated renal pelvis, removal of all small sized stones in every calix and performing anastomosis following pyeloplasty.

References

1. Husmann DA, Milliner DS, Segura JW (1996) Ureteropelvic junction obstruction with concurrent renal pelvic calculi in the pediatric patient: a long-term followup. *J Urol* 156: 741-743.
2. Skolarikos A, Dellis A, Knoll T (2015) Ureteropelvic obstruction and renal stones: etiology and treatment. *Urolithiasis* 43: 5-12.
3. Canda AE, Atmaca AF, Balbay MD (2013) Robotic Pyeloplasty: Step by Step Surgical Technique. *Advances in Robotics and Automation*.
4. Nguyen HT, Benson CB, Bromley B, Campbell JB, Chow J, et al. (2014) Multidisciplinary Consensus on the Classification of Prenatal and Postnatal Urinary Tract Dilatation (UTD Classification System). *J Pediatr Urol* 10: 982-998.
5. Woodward M, Frank D (2002) Postnatal management of antenatal hydronephrosis. *B JU Int* 89: 149-156.
6. Vegar-Zubovic S, Kristic S, Lincender L (2011) Magnetic resonance urography in children-when and why? *Radiol and oncol* 45: 174-179.
7. Gadzhiev N, Brovkin S, Grigoryev V, Tagirov Nair, Korol Valeriy, et al. (2014) Sculpturing in Urology, or How to Make Percutaneous Nephrolithotomy Easier. *J Endourol*.
8. Bombinski P, Warchol S, Brzewski M, Biejat A, Dudek-Warchol T, et al. (2014) Lower-dose CT urography (CTU) with iterative reconstruction technique in children-initial experience and examination protocol. *P J Radiol* 79: 137-44.
9. Krepkin K, Won E, Ramaswamy K, Triolo M, Stiffelma M, et al. (2014) Dynamic contrast-enhanced MR renography for renal function evaluation in ureteropelvic junction obstruction: feasibility study. *AJR Am J Roentgenol* 202: 778-83.
10. Agarwal A, Varshney A, Bansal BS (2008) Concomitant percutaneous nephrolithotomy and transperitoneal laparoscopic pyeloplasty for ureteropelvic junction obstruction complicated by stones. *J Endourol* 22: 2251-2256.
11. Pahwa M, Pahwa AR, Girotra M, Abrahm RR, Kathuria S, et al. (2014) Defining the Pros and Cons of Open, Conventional Laparoscopy, and Robot-Assisted Pyeloplasty in a Developing Nation. *Adv Urol*.
12. Scardino PT, Scardino PL (1981) Obstruction at the ureteropelvic junction. The ureter. Springer, Verlag, New York.
13. Kavoussi LR, Peters CA (1993) Laparoscopic pyeloplasty. *J Urol* 150: 1891-4.
14. Schuessler WW, Grune MT, Tecuanhuey LV, Preminger GM (1993) Laparoscopic dismembered pyeloplasty. *J Urol* 150: 1795-9.
15. Jarret TW, Bauer JJ, Bishoff JT, Moore RG, Chen RN, et al. (1999) Laparoscopic pyeloplasty: the first 100 cases. Laparoscopic versus open pyeloplasty: assessment of objective and subjective outcome. *J Urol* 162: 692-695.
16. Moreno-Sierra J, Castillon-Vela I, Ortiz-Oshiro E, Galante-Romo I, Fernandez-Perez C, et al. (2013) Robotic Anderson-Hynes dismembered pyeloplasty: initial experience. *The Int J Med Robot* 9: 127-133.
17. Bentas W, Wolfram M, Bräutigam R, Probst M, Beecken WD, et al. (2003) Da Vinci robot assisted Anderson-Hynes dismembered pyeloplasty: technique and 1 year follow-up. *World J Urol* 21: 133-138.
18. Singh I, Hemal AK (2010) Robot-assisted pyeloplasty: review of the current literature, technique and outcome. *Can J Urol* 17: 5099-5108.
19. Yee DS, Shanberg AM, Duel BP, Rodriguez E, Eichel L, et al. (2006) Initial comparison of robotic-assisted laparoscopic versus open pyeloplasty in children. *Urology* 67: 599-602.
20. Hemal AK, Mishra S, Mikharjee S, Suryavanshi M (2008) Robot assisted laparoscopic pyeloplasty in patients of ureteropelvic junction obstruction with previously failed open surgical repair. *Int J Urol* 15: 744-746.
21. Di Gregorio M, Botnaru A, Bairy L, Lorge F (2014) Passing from open to robotic surgery for dismembered pyeloplasty: a single centre experience. Springer Plus.
22. Rivas JG, Gregorio SAY, Sanchez LC, Guerin CC, Gomez AT, et al. (2013) Approach to kidney stones associated with ureteropelvic junction obstruction during laparoscopic pyeloplasty. *Cent European J Urol* 66: 440-444.
23. Varda BK, Johnson EK, Clark C, Chung BI, Nelson CP, et al. (2014) National Trends of Perioperative Outcomes and Costs for Open, Laparoscopic and Robotic Pediatric Pyeloplasty. *J Urol* 191: 1090-1095.