

# Resection of an Osteoid Osteoma of the Talus by Arthroscopy: About a Case

Mehdi Abakka\*, Hamza El Ouagari, Mouhssine El Mhadder and MS. Berrada

Department of Traumatology and Orthopedics, CHU Ibn Sina de Rabat, Av. Bettouga, Rabat, Morocco

## Abstract

Osteoid osteoma is a benign primary bone tumor. This tumor is relatively common; it represents 12% of all benign bone tumors and about 2 to 3% of all bone tumors. We report in this work a case of osteoid osteoma treated by arthroscopy. This is a 19-year-old patient referred for chronic ankle pain evolving for 6 months.

**Keywords:** Osteoid osteoma • Bone tumor • Arthroscopy

## Introduction

The AP and lateral ankle X-rays show a heterogeneous area next to the talus neck with no soft tissue abnormalities. CT scan of the ankle showed the presence of a hypodense nodular lesion at the level of the talus neck with a slight osteosclerotic reaction [1].

## Case Presentation

### Historical reminder and principle of arthroscopy

Arthroscopy is a surgical technique invented in Japan and brought back to Europe by Dr. Henri Dorfmann, its principle consists in exploring a joint using a fiber optic endoscope introduced directly into the joint.

The arthroscopy room consists of The optical device (endoscope) consists of a flexible cable a few millimeters in diameter equipped with an optical fiber; it has a light source at one of its ends, the most efficient use a mini camera and are connected to a video screen, equipped with tweezers to take samples for laboratory analysis [2].

A control system allows the end of the endoscope to pivot in order to visualize all the corners of the joint. Arthroscopies are performed mainly at the level of the knee, shoulder and ankle. This examination studies the articular structures (cartilages, menisci, ligaments) in order to detect anomalies, take samples, perform minor surgical procedures (suture of a meniscus, removal of debris, joint washing, etc.). It thus makes it possible to search for and find the lesion of a meniscus at the level of the knee, a ligament lesion (frequent in athletes), damage of the cartilage (osteoarthritis, sequelae of infection, etc.), a foreign body or cartilage debris (Figure 1).

### Admission of the patient and diagnostic procedure

This is H.A, a 19-year-old patient referred to our department for chronic ankle pain evolving for 6 months without any notion of previous trauma. The AP and lateral ankle X-rays revealed a heterogeneous area next to the talus

neck with no soft tissue abnormalities. CT of the ankle showed the presence of a hypodense nodular lesion at the level of the talus neck with a mild osteosclerotic reaction (Figure 2).

### Therapeutic care

The patient was scheduled for resection of this process by arthroscopy. The procedure was successful and the surgical specimen was sent to the pathology laboratory for histological study. The histological study confirmed the benign tumoral nature of the resected piece, which is in favor of an osteoid osteoma (Figure 3).

### Post-operative follow-up

H.L Jaffe first described osteoid osteoma in 1935. It is a benign osteoblastic tumor, which comprises a small central fleshy vascularized, osteoid and immature lesion (the nidus), surrounded by osteocondensation reaction. Location at the level of the talus is rare, as it represents only 5 to 8% of cases, which can lead to a diagnostic delay.

## Results and Discussion

The clinical signs are dominated by inflammatory and often nocturnal pain. The classic improvement in pain with NSAIDs and aspirin is a good clinical test [3].

The treatment must meet two imperatives: carry out a complete excision of the lesion in order to avoid recurrences and not resect too widely, because there is a risk of causing fragility of the bone segment or causing disorders of

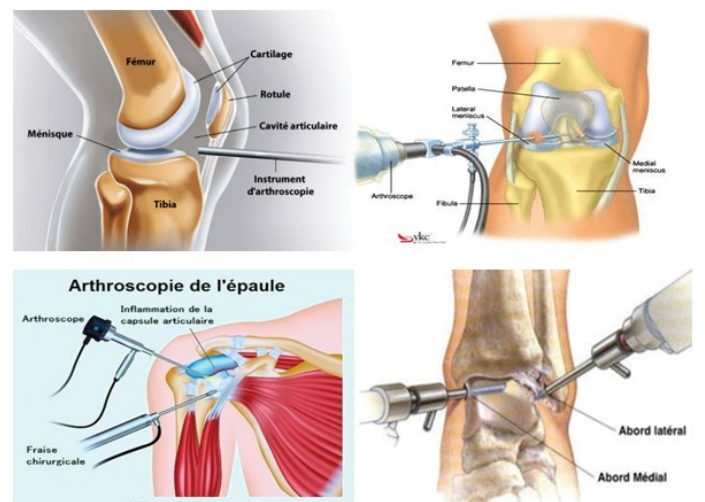
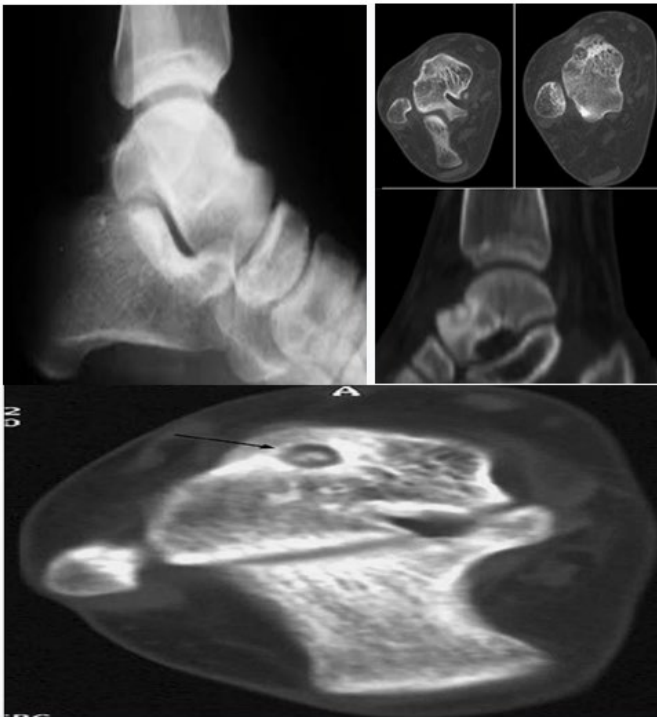

Figure 1. Arthroscopy examination studies on the articular structures.

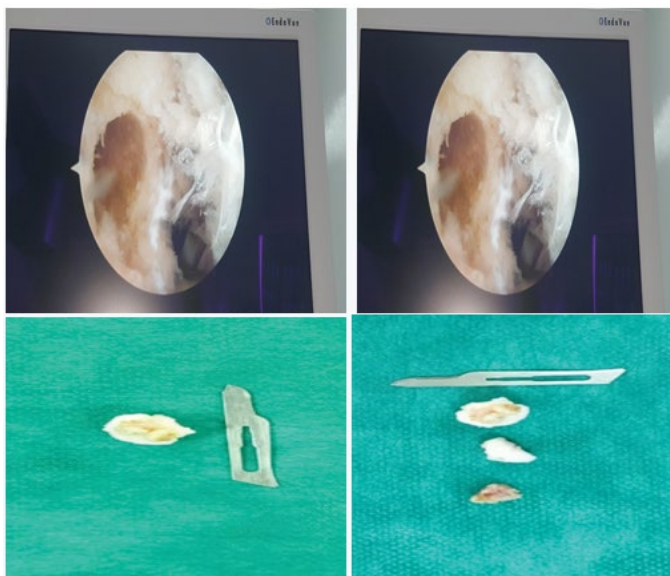
\*Address for Correspondence: Mehdi Abakka, Department of Traumatology and Orthopedics, CHU Ibn Sina de Rabat, Av. Bettouga, Rabat, Morocco; Tel: 0624308058, E-mail: mehdi.abakka@gmail.com

**Copyright:** © 2023 Abakka M, et al. This is an open-access article distributed under the terms of the Creative Commons Attribution License, which permits unrestricted use, distribution, and reproduction in any medium, provided the original author and source are credited.

**Received:** 06 January, 2023; Manuscript No. jccr-23-90151; **Editor Assigned:** 07 January, 2023; PreQC No. P-90151; **Reviewed:** 18 January, 2023; QC No. Q-90151; **Revised:** 23 January, 2023, Manuscript No. R-90151; **Published:** 30 January, 2023, DOI: 10.37421/2165-7920.2023.13.1549



**Figure 2.** The AP, lateral ankle X-rays and CT of the ankle.



**Figure 3.** The histological study after arthroscopy examination.

growth in children. Arthroscopic treatment has several advantages: it is a quick and simple procedure, which combines diagnostic and therapeutic interests. It gives the possibility of exploring the joint and thus establishing an associated lesion assessment; it is accompanied by a rapid resumption of activity as well as a limitation of the risks of infection and joint stiffness compared to an arthrotomy. In our patient, the postoperative course was good, marked by an obvious regression of pain [4].

## Conclusion

Osteoid osteoma of the talus neck is rare and therefore often diagnosed late. Surgical treatment has benefited from advances in imaging and minimally invasive surgery techniques. Complete removal of the nidus results in healing without recurrence. The advent of arthroscopy allows rapid management without major complications, just as it allows the exploration of the entire ankle joint as well as a rapid resumption of activities.

## References

1. [www.genou.com](http://www.genou.com)
2. [www.ccos.fr](http://www.ccos.fr)
3. [www.docteurrouxel.com](http://www.docteurrouxel.com)
4. [www.sofarthro.com](http://www.sofarthro.com)

**How to cite this article:** Abakka, Mehdi, Hamza El Ouagari, Mouhssine El Mhadder and MS. Berrada. "Resection of an Osteoid Osteoma of the Talus by Arthroscopy: About a Case." *Clin Case Rep* 13 (2023): 1549.