

Relief of Pitcher's Elbow by Denervation of Medial Humeral Epicondyle

A Lee Dellon*

Professor of Plastic Surgery and Neurosurgery, Johns Hopkins University, USA

Abstract

An operation is presented to relieve the pain of medial epicondylitis related to a throwing injury in a teenage baseball player. This 17 year old had progressive pain at the medial humeral epicondyle only with the pitching motion. His MRI was normal and he did not have any symptoms of ulnar nerve entrapment. A nerve block of the nerve to the medial humeral epicondyle enabled him to carry out the pitching motion without pain. The nerve was resected about 2 cm proximal to the medial humeral epicondyle at the medial intermuscular septum and the proximal end of the nerve implanted into the medial head of the triceps muscle. At three weeks after surgery he resumed pitching. At one year following the denervation, he is able to pitch without the previous pain. This is the first reported treatment of this problem in a pitcher by denervation, and demonstrates the ability to return to sports rapidly after this minimally invasive procedure.

Keywords: Medial epicondylitis; Pitcher's elbow; Thrower's elbow; Denervation

Introduction

Medial humeral epicondylitis (MHE) is a well-described, sports-limiting problem in baseball player and golfers, and increasing attention has been given recently to adolescent baseball pitchers [1-3]. MHE is to be distinguished from the classic Tommy John (ulnar collateral ligament injury) lesion and ulnar nerve entrapment at the elbow. For MHE, non-operative physical therapy approaches include steroid injection, cold laser therapy, and shock wave therapy [4-7]. The traditional operative approach requires release of the flexor/pronator muscles from the medial humeral epicondyle, is invasive and requires months of rehabilitation [8-11].

Lateral humeral epicondylitis, or tennis elbow, recently has been reported to be relieved successfully by denervation of the lateral humeral epicondyle [12,13]. This surgery has been shown to have a significantly less time required for rehabilitation than epicondylectomy [12]. The posterior cutaneous nerve to the forearm has branches to the lateral epicondyle that can be approached through an incision proximal to the elbow [13].

In 1998, the nerve to the medial humeral epicondyle was identified [14] and its resection to treat medial humeral epicondylar pain following ulnar nerve transposition reported in 2012 [15]. The present case report applies this concept, of denervation of the medial humeral epicondyle, for the first time, to the pain of thrower's elbow in a teenaged pitcher.

Case Report

A 17 year old, right handed, baseball pitcher, began to experience pain at the right medial humeral epicondyle during the throwing motion of his fast ball. After 6 months of symptoms, and after trying physical modalities such as heat, guidance by his experience trainer in throwing motion technique, ultrasound treatments, he had an MRI of the elbow that documented no structural abnormalities. The concept of pain of neural origin was raised by a family friend and he was referred to me for evaluation.

Non-invasive neurosensory and motor testing with the Pressure-Specified Sensory Device™ demonstrated normal ulnar and median nerve function with normal pinch and grip strength. He had point tenderness at the medial humeral epicondyle during his pitching motion (Figure 1). A nerve block of the nerve to the medial humeral epicondyle directly at the medial intermuscular septum 2 cm proximal to the medial humeral epicondyle gave relief of the pain and he could do his usual throwing motion without pain. Based upon this nerve



Figure 1: The pitcher pointing to the area of pain which occurs in this phase of his throwing motion.

block's improvement in function, a denervation procedure was done (Figures 2 and 3).

Immediately after the surgery, full use and range of motion of fingers and elbow was permitted, with him wearing a sling while walking just for the first week. At the 14th day he was allowed to begin carrying a

***Corresponding author:** A Lee Dellon, Professor of Plastic Surgery and Neurosurgery, Johns Hopkins University, USA, Tel: 410 299 6927; E-mail: ALDellon@Dellon.com

Received December 31, 2013; **Accepted** March 05, 2014; **Published** March 15, 2014

Citation: Dellon AL (2014) Relief of Pitcher's Elbow by Denervation of Medial Humeral Epicondyle. J Sports Med Doping Stud 4: 135. doi:[10.4172/2161-0673.1000135](https://doi.org/10.4172/2161-0673.1000135)

Copyright: © 2014 Dellon AL. This is an open-access article distributed under the terms of the Creative Commons Attribution License, which permits unrestricted use, distribution, and reproduction in any medium, provided the original author and source are credited.

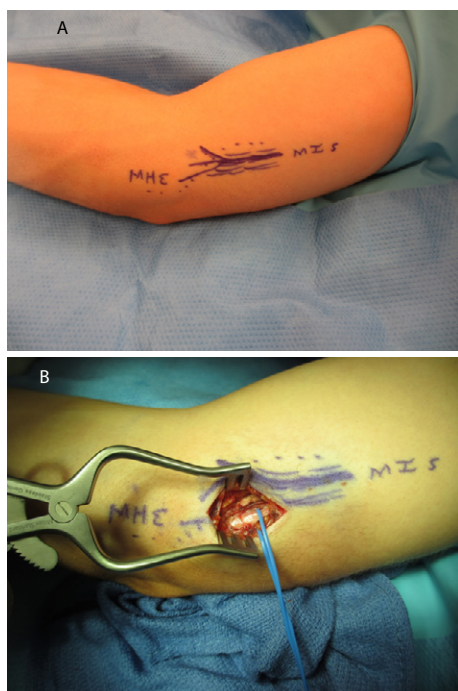


Figure 2: Intra-operative photos.

A: The marking on the right arm, showing the medial intermuscular septum (MIS) with the nerve to the medial humeral epicondyle (MHE) drawn on top of it.

B: The incision opened down to the medial intermuscular septum with the vessel loop identifying the ulnar nerve.



Figure 4: Post-operative pitching in a game 8 weeks after the surgery.

baseball with that hand. At the 21st day he resumed gentle pitching with his trainer. At the 6th week he re-entered the pitching rotation for his high school team; “3 up, 3 down” (Figure 4). He has now entered college and will play baseball as a pitcher.

Operative technique

The surgery is done using no tourniquet, and with general anesthesia. Loupe magnification of 3.5 x power is utilized with a bipolar coagulator set at a low setting, such as 10 to 12. Local anesthetic is injected into the skin, but not the subcutaneous tissue, over the planned incision site, approximately 2 to 5 cm proximal to the medial humeral epicondyle. After incising the skin, the subcutaneous tissues are gently spread, taking care not to injure a posterior branch of the medial antebrachial cutaneous nerve. The dissection goes directly to the medial intermuscular septum. Then the ulnar nerve is identified posterior to the septum, and gently encircled with a vessel loop. The nerve to the medial epicondyle can be found either directly on the septum anteriorly, but is most often found within or posterior to the septum. The nerve is just 1 mm in diameter, requiring a patient and meticulous dissection. A segment of the septum can be removed to facilitate identification of this nerve. Once identified, the nerve can be gently pulled upon to demonstrate its distal innervation into the medial epicondyle, and stimulated electrically with a disposable stimulator to demonstrate there is no motor component. Then the nerve is infiltrated with the local anesthetic, then cauterized distally, divided distally, a segment submitted to pathology for identification, and the proximal end turned and implanted bluntly and without a suture into the medial head of the triceps muscle (Figures 2 and 3).

Discussion

Medial epicondylitis is a frequent problem in youthful baseball players. In a 2 year study of 298 youth pitchers, aged 9 to 14 years, conducted by telephone calls after baseball games, arm complaints were present in about 50% of those participating, with 26% having

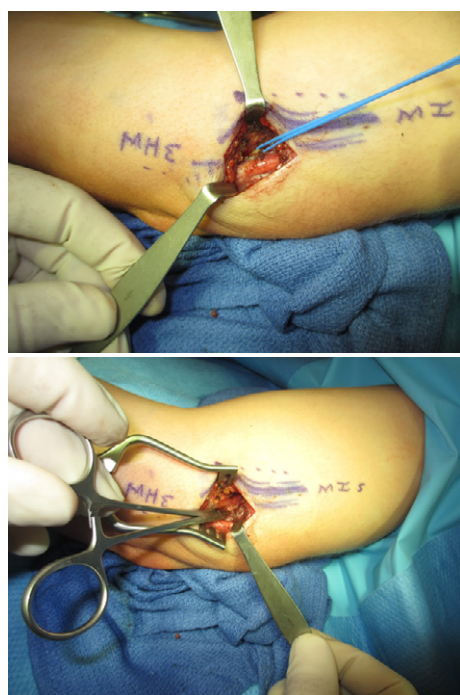


Figure 3: Intra-operative photos continues.

A: The vessel loop now encompasses the nerve to the medial epicondyle, and is a structure discrete from the ulnar nerve.

B: After excising a segment of the nerve to the medial epicondyle, the clamp is shown implanting the proximal end of the nerve into the medial head of the triceps.

elbow complaints and 32% having shoulder complaints [16]. When youth pitchers were evaluated during a one year pitching season, this same group of researchers found that throwing the slider caused elbow complaints in 52% and the curve ball caused shoulder complaints in 86% of pitchers [17]. This same group of doctors conducted an evaluation of 9 to 14 year olds, with a ten year follow-up period. Among 481 pitchers, the cumulative risk for injury was 5%, with those who threw more than 100 innings in a year having 3.5 times the risk of injury as those who threw less than 100 pitches per inning [18].

The surgical approach presented in this report, denervation of the medial humeral epicondyle, offers hope for those pitchers who have persistent MHE and who have not responded to the traditional non-operative approaches. Furthermore, the surgical technique reported here offers an approach that requires little post-operative rehabilitation, since the origins of the flexor/pronator muscle mass have not been released. This approach, as demonstrated by the youth pitcher described, permits early return to pitching.

Of course this is just the report of one patient, but it offers the possibility that those sports medicine physicians and surgeons involved with this type of problem in throwing and golfing sports can begin a more thorough evaluation of denervation in the treatment of MHE.

References

1. Kerut EK, Kerut DG, Fleisig GS, Andrews JR (2008) Prevention of arm injury in youth baseball pitchers. *J La State Med Soc* 160: 95-98.
2. Creighton RA, Bach BR Jr, Bush-Joseph CA (2006) Evaluation of the medial elbow in the throwing athlete. *Am J Orthop (Belle Mead NJ)* 35: 266-269.
3. Grana WA, Rashkin A (1980) Pitcher's elbow in adolescents. *Am J Sports Med* 8: 333-336.
4. Peters C, George SZ (2007) Outcomes following plyometric rehabilitation for the young throwing athlete: a case report. *Physiother Theory Pract* 23: 351-364.
5. Metz JP (1999) Managing golf injuries: technique and equipment changes that aid treatment. *Phys Sportsmed* 27: 41-56.
6. Simunovic Z, Trobonjaca T, Trobonjaca Z (1998) Treatment of medial and lateral epicondylitis--tennis and golfer's elbow--with low level laser therapy: a multicenter double blind, placebo-controlled clinical study on 324 patients. *J Clin Laser Med Surg* 16: 145-151.
7. Kirschek O, Hopf C, Nafe B, Rompe JD (1999) Shock-wave therapy for tennis and golfer's elbow--1 year follow-up. *Arch Orthop Trauma Surg* 119: 62-66.
8. Ciccotti MG, Ramani MN (2003) Medial epicondylitis. *Tech Hand Up Extrem Surg* 7: 190-196.
9. Erne HC, Zouzias IC, Rosenwasser MP (2009) Medial collateral ligament reconstruction in the baseball Pitcher's elbow. *Hand Clin* 25: 339-346.
10. Schipper ON, Dunn JH, Ochiai DH, Donovan JS, Nirschl RP (2011) Nirschl surgical technique for concomitant lateral and medial elbow tendinosis: a retrospective review of 53 elbows with a mean follow-up of 11.7 years. *Am J Sports Med* 39: 972-976.
11. Erickson BJ, Gupta AK, Harris JD, Bush-Joseph C, Bach BR, et al. (2014) Rate of return to pitching and performance after tommy john surgery in major league baseball pitchers. *Am J Sports Med* 42: 536-543.
12. Dellon AL, Ducic I, Dejesus RA (2006) The innervation of the medial humeral epicondyle: implications for medial epicondylar pain. *J Hand Surg Br* 31: 331-333.
13. Dellon AL (2009) Partial joint denervation I: wrist, shoulder, and elbow. *Plast Reconstr Surg* 123: 197-207.
14. Berry N, Neumeister MW, Russell RC, Dellon AL (2011) Epicondylectomy versus denervation for lateral humeral epicondylitis. *Hand (NY)* 6: 174-178.
15. Rose NE, Forman SK, Dellon AL (2013) Denervation of the lateral humeral epicondyle for treatment of chronic lateral epicondylitis. *J Hand Surg Am* 38: 344-349.
16. Lyman S, Fleisig GS, Waterbor JW, Funkhouser EM, Pulley L, et al. (2001) Longitudinal study of elbow and shoulder pain in youth baseball pitchers. *Med Sci Sports Exerc* 33: 1803-1810.
17. Lyman S, Fleisig GS, Andrews JR, Osinski ED (2002) Effect of pitch type, pitch count, and pitching mechanics on risk of elbow and shoulder pain in youth baseball pitchers. *Am J Sports Med* 30: 463-468.
18. Fleisig GS, Andrews JR, Cutter GR, Weber A, Loftice J, et al. (2011) Risk of serious injury for young baseball pitchers: a 10-year prospective study. *Am J Sports Med* 39: 253-257.