

## Refractory Ascites after Pancreato-Duodenectomy– Time to Rethink an Old Dogma

Meillat Helene<sup>1\*</sup>, Ewald Jacques<sup>1</sup>, Piana Gilles<sup>2</sup>, Sarran Anthony<sup>2</sup>, Giovannini Marc<sup>3</sup>, Bories Erwan<sup>3</sup>, Turrini Olivier<sup>1</sup> and Delpero Jean-Robert<sup>1</sup>

<sup>1</sup>Department of Surgical Oncology, Institute Paoli-Calmettes and Université de la Méditerranée, Marseille, France

<sup>2</sup>Department of Radiology, Institute Paoli Calmettes, Marseille, France

<sup>3</sup>Department of Digestive Endoscopy, Institute Paoli Calmettes, Marseille, France

### Abstract

A rare case of refractory ascites caused by benign portal vein stenosis after pancreatoduodenectomy (PD) is reported. A dogma claims that ascites is found in portal hypertension with an intrahepatic block only. However, in the postoperative state, the pathophysiologic condition is altered, which made diagnosis difficult.

A 69-year-old man who had undergone PD for lower bile duct carcinoma *in situ*, developed in postoperative course a pseudoaneurysm of the common hepatic artery successfully treated by stent graft. Six months later, the patient developed refractory ascites. CT scan revealed a severe stricture in the main trunk of the portal vein, probably due to extrinsic compression by the stent in the hepatic artery. Percutaneous transhepatic portography was performed and stent-graft was placed over the stenotic segment. Portal blood flow was corrected immediately. One week after the stenting procedure the patient was free of ascites and control physical and biochemical examination three years later is completely normal.

**Keywords:** Extrahepatic portal vein stenosis; Refractory ascites; Stent graft

### Introduction

Portal hypertension after extensive abdominal surgery is an unusual cause of refractory ascites. Portal hypertension subsequent to pancreatoduodenectomy (PD) is likely to be linked to extra-hepatic portal vein (PV) stenosis, and it can occur after its concurrent resection and anastomosis, pre- or intra-operative radiotherapy or local recurrence around the portal vein [1-4]. The incidence rate for portal vein stenosis is reported to be 11% to 23% [5,6], but the incidence of refractory ascites is unknown. Portal hypertension without hepatic dysfunction secondary to PV stenosis causes gastrointestinal bleeding from gastroesophageal or jejunal varices and refractory ascites [7]. Gastrointestinal bleeding is the most serious life-threatening complication. Little attention has been devoted to refractory ascites, an infrequent and not fatal complication.

Here, we provide the case report of one patient with PV stenosis after pancreato-duodenectomy for ampulloma, and we argue for a relationship between PV stenosis and refractory ascites.

### Case Report

#### Treatment of pseudoaneurysm in the hepatic artery

In February 2011, a 69-year-old man underwent a pancreato-duodenectomy for ampullary carcinoma as T3N0 found during an evaluation of anicteric cholestasis at a routine health check-up. The patient had a history of hypothyroidism following radioactive iodine treatment for thyrotoxicosis, hypertension and 5 pack-years of smoking (weaned for several years). The pancreatic texture was soft, and the main pancreatic duct was thin (5 mm). Pancreatico-intestinal continuity was established by intussusception of the pancreatic end into the gastric lumen with stenting of the main pancreatic duct to ensure its patency. The tumour on the specimen was a lower bile duct carcinoma *in situ* with no lymph node metastasis. All surgical resection margins were tumour-negative. Consequently, no adjuvant treatment was necessary. During the postoperative course, a minor leak from the pancreas occurred, which was resolved spontaneously. The recovery of the diet was well tolerated, and the drain was gradually removed. The patient presented no exocrine pancreatic insufficiency or diabetes.

However, on the 19<sup>th</sup> postoperative day, blood through the old drain port was collected. The patient's vital signs were stable, and laboratory examination showed moderate anemia with a haemoglobin level of 11 g/dl. No blood transfusion was necessary. Computed tomography and angiography revealed a pseudoaneurysm arising at the common hepatic artery without active bleeding. To secure the hepatoportal arterial flow, an angioplasty was performed. After stenting, embolization of the pseudoaneurysm was attempted using micro-coils to stop the inflow into the pseudo-aneurysm lumen. The patency of the hepatic artery and the disappearance of the pseudoaneurysm were confirmed by arteriography 2 days after treatment (angiography confirmed that the stent had arrested the haemorrhage and preserved the blood flow to the liver). The clinical course was uneventful, and the patient was discharged 8 days after the procedure.

#### Treatment of refractory ascites

This patient did well for 6 months after hospital discharge. From 2012, however, he was readmitted several times with ascites requiring iterative paracentesis and regular diuretic therapy. Liver and thyroid function test results and pancreatic enzyme assessments were normal.

To evaluate the aetiology of this ascites, a CT scan was performed. Hepatic arterial flow was normal, but celiac and mesenteric during the portal phase revealed a severe stricture at the main trunk of the portal vein adjacent to the hepatic stent (Figure 1). The pancreato-gastric fistula seemed dried without any intra-abdominal collection, aerobilia, and no portal vein thrombosis. No recurrent tumour was identified.

**\*Corresponding author:** Meillat Helene, Department of Surgical Oncology, Institute Paoli-Calmettes and Université de la Méditerranée, Marseille, France, Tel: 0491223660; Fax: 0491223550; E-Mail: [meillath@ipc.unicancer.fr](mailto:meillath@ipc.unicancer.fr)

**Received** October 16, 2017; **Accepted** November 23, 2017; **Published** November 28, 2017

**Citation:** Helene M, Jacques E, Gilles P, Anthony S, Marc G, et al. (2017) Refractory Ascites after Pancreato-Duodenectomy– Time to Rethink an Old Dogma. J Clin Case Rep 7: 1043. doi: [10.4172/2165-7920.10001043](https://doi.org/10.4172/2165-7920.10001043)

**Copyright:** © 2017 Helene M, et al. This is an open-access article distributed under the terms of the Creative Commons Attribution License, which permits unrestricted use, distribution, and reproduction in any medium, provided the original author and source are credited.

Hepatofugal collaterals had also developed via the left gastric vein. Moreover, collateral vessels were observed around the hepaticojejunostomy, creating jejunal varices in the lifted limb towards the hepatic hilum.

The paracentesis initially had a milky appearance consistent with chylous ascites and low amylase concentration. Triglyceride and albumin levels were normal. Cytological examination and bacteriological analyses were negative.

The ascites was temporarily resolved with diuretics and suitable diet, but from May 2012, the patient presented with a recurrence of ascites and a recurrent sub-cutaneous abscess at the previous fistula drainage site corresponding to the reactivation of the pancreatic fistula, probably favoured by the ascites and requiring surgical drainage. The paracentesis had a low protein concentration consistent with portal hypertension.

The CT-scan was unchanged except for increased portal vein stenosis. Due to the refractory ascites and to prevent complete venous occlusion, we decided to attempt portal venous decompression by a transjugular transhepatic approach. A percutaneous transhepatic portography (PTP) into the hepatic side of the portal vein above the stenosis was performed (puncture in the anterior branch of the right portal vein). As seen in Figure 2, PTP findings were consistent with those obtained by CT-scan. A self-expandable metallic stent, 12 mm

in diameter and 60 mm in length, was deployed through the stenotic segment. The stent-graft was then mechanically dilated using a balloon dilatator 12 × 40, resulting in full expansion of the graft. Portal blood flow was corrected immediately.

As shown in Figure 2, portography revealed good portal blood flow through the stent-graft, and the jejunal varices had disappeared. Intravenous heparin administration was performed at a dose of 15000 UI per day for seven days after the stent placement, and this was followed by an antiplatelet drug. Currently, the patient is doing well without repetitive episodes of ascites for 4 years after the procedure (Figure 3).

## Discussion

Postoperative ascites is a rare and little-known complication of pancreatic surgery. Indeed, it can occur secondary to a number of pathological conditions difficult to diagnose in this context. Getting the correct diagnosis was a challenge in our patient. Peritoneal carcinosis was immediately eliminated in the context of low grade dysplasia and negative cytology in the ascitic fluid. Chylous ascites was our first hypothesis in the context and according to the milky appearance of the first paracentesis. Chyloperitoneum is more prevalent after extensive abdominal operation involving the retroperitoneum [8]. Patients undergoing pancreatic resection develop a chyle leak in 1.8% to 11% [9] of cases, possibly due to surgical disruption of the cisterna chyli or its major tributaries located at the same level as the pancreas [10] induced by extended lymphadenectomy or dissection of the retroperitoneum. Another explanation may be the obstruction or malignant infiltration of lymphatic channels [11] with subsequent development of a lymphatic fistula that communicates with the peritoneal cavity, which is unlikely in this patient.

Although the late onset and prolonged evolution of this ascites were not in favour of this diagnosis, some authors have demonstrated that increased portal pressure, in the cirrhotic liver for example, is a risk factor for chylous ascites [12,13], and the initial clinical course with a diuretic and suitable diet was satisfactory.

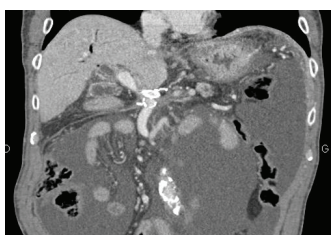
Afterward, the evolution towards refractory ascites with a low protein concentration consistent with portal hypertension led to the conclusion that the ascites was due to the portal vein stenosis. Portal vein stenosis is the main cause of prehepatic portal hypertension [14,15]. After a pancreatoduodenectomy for periampullary cancer, tumour recurrence around the PV is the most frequent cause of early PV stenosis [16].

Benign extrahepatic portal vein stenosis is a less common complication, occurring later than disease recurrence [16]. Stenosis can be caused by inflammation of the structures surrounding the portal vein or can result from surgical injury and post-surgical adhesion to the portal vein [4-6].

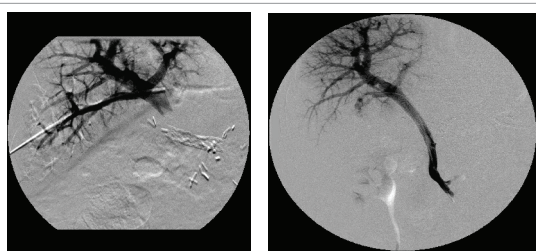
In our patient, periportal inflammation associated with pancreatic leakage and local sepsis may have induced damage to the vascular walls and generated venous spasm, venous stasis and thrombosis [5] in the same manner as inflammation weakened the hepatic artery wall resulting in a pseudoaneurism.

Progressive fibrosis due to the prolonged drainage associated with surgical vascular skeletonisation led to progressive constriction of the splenomesentericoportal axis that passes through the pancreatic substance.

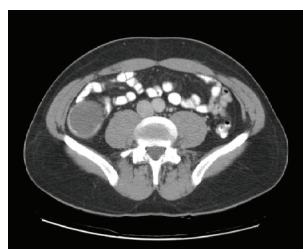Another factor contributing to EPH encompasses extrinsic compression by the stent in the hepatic artery.



**Figure 1:** Coronal multiplanar reformation image shows stenosis of the main portal vein above the level of the splenoportal junction with expansion of the superior mesenteric vein upstream.



**Figure 2:** Percutaneous transhepatic portography during portal venous stent placement.



**Figure 3:** Normal blood flow in the hepatic artery and portal vein after insertion of the portal stent (3 years after stenting) and complete disappearance of ascites.

The complication rate of benign extrahepatic portal vein stenosis is low, no greater than 2% [17,18].

There are several reports of bleeding from jejunal varices in patients with biliary reconstruction after resection of the hepatic bile duct [19,20], but there are no reports about refractory ascites.

The lack of reports is partly because there is a dogma claiming that ascites is found in portal hypertension with an intrahepatic block only.

Indeed, natural compensatory phenomena are set up and explain the absence of clinical consequences during the interruption of portal flow. The first compensatory mechanism is the immediate vasodilatation of the hepatic artery in response to a decrease in portal venous flow (arterial “buffer” response) [21]. In this case, the implementation of the stent in the hepatic artery probably made its wall stiff, making it nonreactive to the stimulus of vasodilatation.

The second compensatory mechanism is the rapid development in a few days of collateral veins (hepatopetal channels) at the periphery or within the adjacent structures of the obstructed portion of the portal vein: the bile duct, gallbladder, pancreas, gastric antrum, or duodenum; this developed is aimed at re-establishing portal blood flow to the liver. As the obstruction of the trunk of the portal vein persists, the collateral veins tend to become progressively more voluminous, and the portal vein is replaced by a “cavernoma”.

Once again, in our patient, the number of collaterals was less than that of normal blood vessels after the pancreatoduodenectomy because of dissection, extended lymphadenectomy and skeletonisation of the vasculature [22]. Need to restore portal flow

After pancreatoduodenectomy, re-exploration around the portal vein might be limited due to the presence of adhesions, the length of the involved portal vein segment, and increased risk of hepatic artery injury [23].

Although portosystemic shunt procedures can offer long-term protection from variceal haemorrhage and refractory ascites [5,24,25], the operative mortality rate [22], especially in a septic context, and the incidence of adverse effects, including a decrease in intrahepatic portal flow or development of post-shunt encephalopathy, are reported to be high [26].

Therefore, a direct surgical approach does not seem indicated in most cases of postoperative portal venous stenosis. The results of many studies on percutaneous transhepatic portal vein stent placement suggest that the procedure is safe and has few major complications [1,3,6,8,23,27].

In the liver transplant population, the results of percutaneous recanalization of the portomesenteric veins are comparable to those of surgical re-intervention [14]. However, there is limited literature available on the role of angioplasty and stenting in patients with portal hypertension due to non-transplant postoperative benign extrahepatic portal vein stenosis. Failure risk factors include Child C cirrhosis, high final portal pressure despite recanalization, splenic vein or SMV involvement and untreated hepatic malignancy [28,29]. Kim et al. found a patency period of  $30.1 \pm 25.6$  months in their 11 patients with postoperative benign portal vein stenosis [23].

In our case, the procedure itself was without complications. The stent was patent as long as the patient survived and relieved intractable ascites with a follow-up of 5 years.

Because in this case there was a possibility for normal portal venous

flow, an angioplasty using either stent-grafts or balloons could be used. If the portal vein had been completely obstructed by inflammatory changes and the obstructed segments were too great in length [30] treatment other than angioplasty would have been chosen.

The main risk is instant restenosis or even stent thrombosis. Some investigators have performed anticoagulant therapy during and after stent placement to prevent it [1,3,6,9,15,19,20]. On the other side, anticoagulation can be responsible for bleeding along the percutaneous transhepatic route, hypersensitivity, and heparin-induced thrombocytopenia. Our patient received antiplatelet therapy but no anticoagulation treatment, in agreement with Novellas et al. [7]. These authors prescribed anticoagulation only in case of decreased portal flow, but they do not prescribe it in cases of normalized flow in the portal vein after stenting.

## Conclusion

Benign postoperative portal vein stenosis may result in uncontrollable and symptomatic portal hypertension. Percutaneous transhepatic stent placement is a safe and effective option in the management of such patients. Stent placement improves quality of life and prognosis by preventing the adverse consequences of portal hypertension. Surgical options have largely been supplanted and may eventually be proposed in the event of failure or inability to provide a stent.

## References

1. Shimizu Y, Yasui K, Fuwa N (2005) Late complication in patients undergoing pancreatic resection with intraoperative radiation therapy: gastrointestinal bleeding with occlusion of the portal system. *J Gastroenterol Hepatol* 20: 1235-1240.
2. Yamakasi S, Kuramoto K, Itoh Y (2005) Clinical significance of portal venous metallic stent placement in recurrent periampullary cancer. *Hepatogastroenterology* 52: 191-193.
3. Ota S, Suzuki S, Mitsuoka H, Mitsuoka H, Unno N, et al. (2005) Effect of a portal venous stent for gastrointestinal haemorrhage from jejunal varices caused by portal hypertension after pancreatoduodenectomy. *J Hepatobiliary Pancreat Surg* 12: 88-92.
4. Yamashita Y, Ryo H, Takasaki K (2004) Clinical study of transient portal vein stenosis induced after pancreatic head resection. *Surg Today* 34: 925-931.
5. Mitsunaga S, Kinoshita T, Kawashima M, Konishi M, Nakagohri T, et al. (2006) Extrahepatic portal vein occlusion without recurrence after pancreatic duodenectomy and intraoperative radiation therapy. *Int J Radiat Oncol Biol Phys* 64: 730-735.
6. Hoffer EK, Krohmer S, Gemery J, Zaki B, Pipas JM (2009) Endovascular recanalization of symptomatic portomesenteric venous obstruction after pancreaticoduodenectomy and radiation. *J Vasc Interv Radiol* 20: 1633-1637.
7. Novellas S, Denys A, Bize P, Kuboki S, Brunner P, et al. (2009) Palliative portal vein stent placement in malignant and symptomatic extrinsic portal vein stenosis or occlusion. *Cardiovasc Intervent R Diol* 32: 462-470.
8. Avrin RA, High R (1985) Chylous ascites after abdominal aortic surgery. *Surgery* 98: 866-869.
9. Kuboki S, Shimizu S, Yoshidome H, Ohtsuka M, Kato A, et al. (2013) Chylous ascites after pancreaticoduodenectomy. *Br J Surg* 100: 522-527.
10. Loukas M, Wartmann CT, Louis RG Jr, Tubbs RS, Salter EG, et al. (2007) Cisterna chyli: A detailed anatomical investigation. *Clin Anat* 20: 683-688.
11. Hwang S, Sung KB, Park YH, Jung DH, Lee SG (2007) Portal vein stenting for portal hypertension caused by local recurrence after pancreatoduodenectomy for periampullary cancer. *J Gastrointest Surg* 11: 333-337.
12. Aalami OO, Allen DB, Organ CH (2000) Chylous ascites: A collective review. *Surgery* 128: 761-778.
13. Zhou DX, Zhou HB, Wang Q, Zou SS, Wang H, et al. (2009) The effectiveness of the treatment of octreotide on chylous ascites after liver cirrhosis. *Dig Dis Sci* 54: 1783-1788.

14. Cohen J, Edelman RR, Chopra S (1992) Portal vein thrombosis: a review. *Am J Med* 92: 173-182.
15. Jang JY, Chang YR, KangMJ, Jung W, Kim SW (2015) Portal vein patency after pancreatoduodenectomy for periampullary cancer. *Br J Surg* 102: 77-84.
16. Little AG, Moossa AR (1981) Gastrointestinal hemorrhage from left-sided portal hypertension. An unappreciated complication of pancreatitis. *Am J Surg* 141: 153-158.
17. Hoshal VL, Benedict MB, David LR (2004) Personal experience with the Whipple operation: Outcomes and lessons learned. *Am Surg* 70: 121-125.
18. Hiraoka K, Kondo S, Ambo Y, Hirano S, Omi M, et al. (2001) Portal venous dilatation and stenting for bleeding jejunal varices: Report of two cases. *Surg Today* 31: 1008-1011.
19. Koike N, Hatori T, Imaizumi T, Harada N, Fukuda A, et al. (2002) Successful treatment with an expandable metallic stent of gastrointestinal bleeding resulting from anastomotic stricture in the reconstructed region of the portal vein. *Nihon Syokakigeka Gakkaizasshi (Jpn J Gastroenterol Surg)* 35: 1394-1398.
20. Eipel C, Abshagen K, Vollmar B (2010) Regulation of hepatic blood flow: The hepatic arterial buffer response revisited. *World J Gastroenterol* 16: 6046-6057.
21. Bassi C, Dervenis C, Butturini G, Fingerhut A, Yeo C, et al. (2005) Postoperative pancreatic fistula: An international study group (ISGPF) definition. *Surgery* 138: 8-13.
22. Kim KR, Ko GY, Sung KB, Yoon HK (2011) Percutaneous transhepatic stent placement in the management of portal venous stenosis after curative surgery for pancreatic and biliary neoplasms. *Am J Roentgenol* 196: 446-450.
23. Xu CE, Zhang SG, Yu ZH, Li GX, Cao LL et al. (2004) Combined devascularization and proximal splenorenal shunt: Is this a better option than either procedure alone? *J Hepatobiliary Pancreat Surg* 11: 129-134.
24. Yamamoto S, Sato Y, Nakatsuka H, Oya H, Kobayashi T, et al. (2007) Beneficial effect of partial portal decompression using the inferior mesenteric vein for intractable gastricesophageal variceal bleeding in patients with liver cirrhosis. *World J Surg* 31: 1266-1271.
25. Sarin SK, Nundy S (1985) Subclinical encephalopathy after portosystemic shunts in patients with non-cirrhotic portal fibrosis. *Liver* 5: 142-146.
26. Woodrum DA, Bjarnason H, Andrews JC (2009) Portal vein venoplasty and stent placement in the non- transplant population. *J Vasc Interv Radiol* 20: 593-599.
27. Stein M, Link DP (1999) Symptomatic spleno-mesenteric-portal venous thrombosis: Recanalization and reconstruction with endovascular stents. *J Vasc Interv Radiol*; 10: 363-371.
28. Yamakado K, Nakatsuka A, Tanaka N, Fujii A, Terada N, et al. (2001) Malignant portal venous obstructions treated by stent placement: Significant factors affecting patency. *J Vasc Interv Radiol* 12: 1407-1415.
29. Smith SC, Winters KJ, Lasala JM (1997) Stent thrombosis in a patient receiving chemotherapy. *Cathet Cardiovasc Diagn* 40: 383-386
30. Bilodeau L, Hearn JA, Dean LS, Roubin GS (1993) Prolonged intracoronary urokinase infusion for acute stent thrombosis. *Cathet Cardiovasc Diagn* 30: 141-146.