

Case Report

Open Access

# Recurrent Interstitial Lung Disease Induced By Various Therapies for Non-Small Cell Lung Cancer

Yu Saida<sup>1</sup>, Satoshi Watanabe<sup>2\*</sup>, Junko Baba<sup>3</sup>, Jun Koshio<sup>3</sup>, Rie Kondo<sup>3</sup>, Masaaki Okajima<sup>3</sup>, Satoru Miura<sup>3</sup>, Tetsuya Abe<sup>1</sup>, Hiroshi Tanaka<sup>1</sup>, Junta Tanaka<sup>3</sup>, Hiroshi Kagamu<sup>3</sup>, Hirohisa Yoshizawa<sup>2</sup> and Ichiei Narita<sup>3</sup>

<sup>1</sup>Niigata Cancer Center Hospital, 951-8566 Niigata, Japan

<sup>2</sup>Bioscience Medical Research Center, Niigata University Medical and Dental Hospital, 951-8520 Niigata, Japan

<sup>3</sup>Department of Medicine (II), Niigata University Medical and Dental Hospital, 951-8520 Niigata, Japan

## Abstract

Erlotinib is a human epidermal growth factor receptor type 1 tyrosine kinase inhibitor which is used for non-small cell lung cancer treatment. Interstitial lung disease has been reported as an adverse event of erlotinib. We report the case of a 39-year-old man with erlotinib-induced interstitial lung disease in a non-small cell lung cancer patient. Although interstitial lung disease had improved by steroid therapy, palliative radiotherapy recalled the pneumonitis beyond the radiation fields. After the pneumonitis was well controlled, the patient was started on irinotecan, but the interstitial lung disease recurred shortly thereafter. We may have to abandon further cytotoxic therapies to avoid the recurrence of interstitial lung disease in patients who develop erlotinib-induced interstitial lung disease once.

**Keywords:** Tyrosine-kinase inhibitor; Non small cell lung cancer; interstitial lung disease

## Introduction

Erlotinib is a human epidermal growth factor receptor-1/epidermal growth factor receptor (HER-1/EGFR) Tyrosine-Kinase Inhibitor (TKI). It has been approved in many countries for the treatment of advanced Non-Small Cell Lung Cancer (NSCLC) and maintenance treatment of NSCLC, as well as in combination with gemcitabine for the treatment of advanced pancreatic cancer. Interstitial Lung Disease (ILD) has been reported as an adverse event of erlotinib [1,2]. The treatment of erlotinib-induced ILD has not been established and the clinical outcome of erlotinib-induced ILD is poor. Moreover, there are no treatment options for patients after recovery from erlotinib-induced ILD. We herein report a case of severe erlotinib-ILD in a NSCLC patient, which was improved by steroid therapy. However, ILD repeatedly occurred during subsequent chemotherapy or radiotherapy.

## Case Presentation

A 39-year-old man who complained of non-productive cough was found to have lung cancer. He was an ex-smoker with a smoking index of 6 pack-years. He did not have family history of respiratory disease, family history of cancer or history of allergy to any drugs. Chest Computed Tomography (CT) demonstrated a mass measuring 5 cm in diameter in the right middle lobe, enlarged mediastinal lymph-nodes, and pleural effusion. Cytological analysis of the pleural effusion revealed adenocarcinoma with mutation-negative *EGFR*. Bone scintigraphy showed multiple bone metastases. The clinical stage was T4N2M1b (Oss) stage IV. The patient received 4 courses of chemotherapy consisting of vinorelbine and paclitaxel, five courses of pemetrexed, and two courses of docetaxel (Figure 1A).

The patient was started on treatment 150 mg erlotinib daily as a fourth-line chemotherapy. On day 8, after the initiation of erlotinib, the patient developed shortness of breath. A chest CT showed diffuse Ground-Glass Opacity (GGO) bilaterally in the lungs without evidence of tumor growth (Figure 1B). The serum LDH and KL-6 levels were elevated to 785 IU/L and 4,580 U/mL, respectively. Arterial blood gasses at rest ( $\text{FiO}_2=0.60$ ) were  $\text{PaO}_2=55.4$  Torr and  $\text{A-aDO}_2$  310 Torr. The results of sputum culture for bacteria or fungi and general blood tests, including beta-D-glucan, fungal antigens, and cytomegalovirus antigens, were negative.

We considered these lesions to be consistent with erlotinib-related Interstitial Lung Disease (ILD). The differential diagnoses for this case were community acquired pneumonitis, atypical viral or fungal pneumonitis, and drug induced pneumonitis, including pulmonary toxic effects of the cytotoxic agent. Infectious pneumonitis including opportunistic infection could be excluded by serological examination and cultivation survey. Any oral medicine had not been started shortly before the onset of ILD. Erlotinib was discontinued, and high-dose intravenous methylprednisolone (1000 mg daily for 3 days) was administered. The patient's symptoms and chest CT findings improved immediately (Figure 1C). The steroid dose was reduced by 5mg biweekly to 0.25 mg/kg of oral prednisolone and maintained.

Seventy days after the onset of erlotinib-ILD, palliative radiotherapy for metastasis to thoracic vertebrae was performed, with minimal exposure to the lung. Five days after the initiation of radiotherapy, the patient again developed dyspnea. A chest CT revealed diffuse bilateral GGO in the lungs, which was not in the radiation fields (Figure 1D). The patient received high-dose methylprednisolone followed by 0.4-0.6 mg/kg of oral prednisolone, and the clinical findings again improved immediately (Figure 1E).

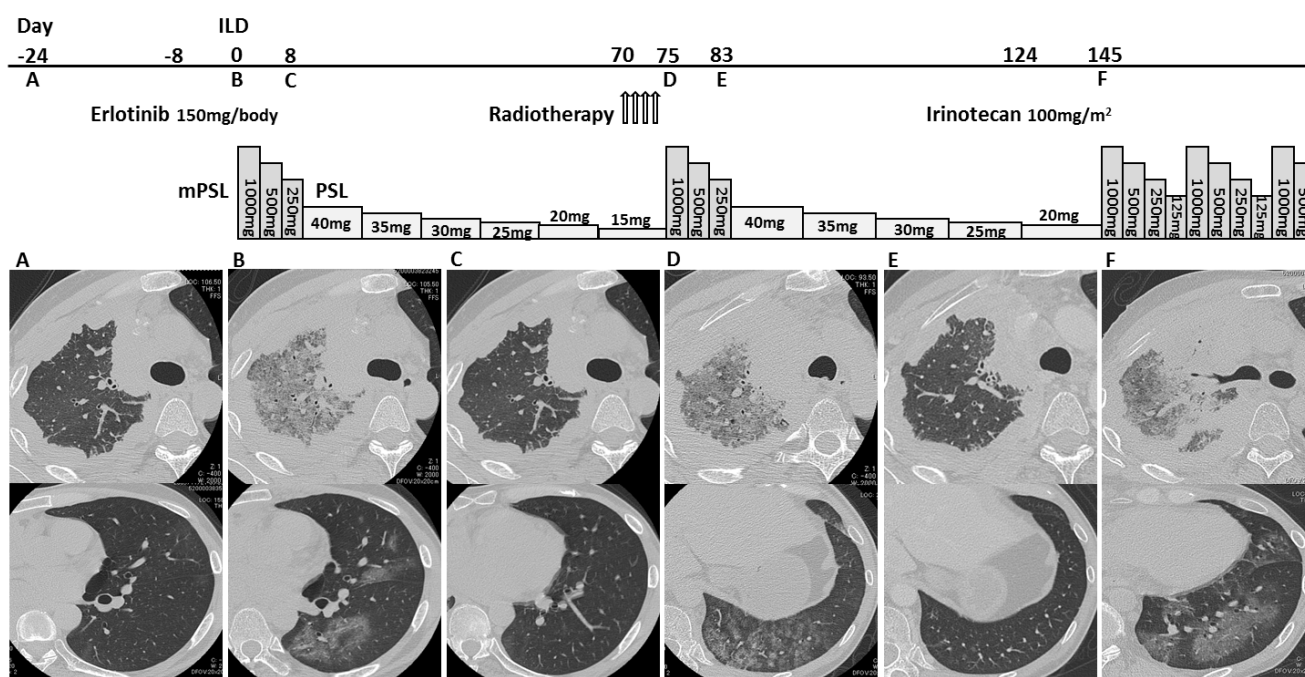
After the pneumonitis was well controlled, the patient and his family held high hopes for further chemotherapy. The patient was started on irinotecan treatment as fifth-line chemotherapy 150 days after the onset of erlotinib-ILD. On day 22, after the initiation of irinotecan, the patient developed dyspnea and fever. A chest CT showed bilateral GGO (Figure 1F). High-doses of methylprednisolone were administered repeatedly; however, respiratory failure developed due to progression of ILD and cancer. The patient died 184 days after the first onset of ILD. We could not obtain the bereaved family's consent for postmortem biopsy.

**\*Corresponding author:** Satoshi Watanabe, Bioscience Medical Research Center, Niigata University Medical and Dental Hospital, 951-8520 Niigata, Japan, Tel: +81-25-227-2517; Fax: +81-25-227-2517; E-mail: [satoshi7@med.niigata-u.ac.jp](mailto:satoshi7@med.niigata-u.ac.jp)

**Received** November 06, 2014; **Accepted** December 24, 2014; **Published** December 31, 2014

**Citation:** Saida Y, Watanabe S, Baba J, Koshio J, Kondo R, et al. (2014) Recurrent Interstitial Lung Disease Induced By Various Therapies for Non-Small Cell Lung Cancer. J Clin Case Rep 4: 471. doi:10.4172/2165-7920.1000471

**Copyright:** © 2014 Saida Y, et al. This is an open-access article distributed under the terms of the Creative Commons Attribution License, which permits unrestricted use, distribution, and reproduction in any medium, provided the original author and source are credited.



**Figure 1:** Chest CT scans of the patient before (A) and 8 days after initiation of treatment with erlotinib (B). Diffuse bilateral GGO in the lungs was apparent on day 8 of erlotinib administration. After steroid therapy, chest CT demonstrated disappearance of GGO (C). Five days after initiation of radiotherapy, chest CT revealed diffuse bilateral GGO in the lungs, which was not in the radiation fields (D). After steroid therapy, chest CT demonstrated disappearance of GGO (E). Twenty-two days after the initiation of treatment with irinotecan, bilateral GGO recurred (F).

## Discussion

Several randomized phase III trials have demonstrated the survival benefit of erlotinib in NSCLC patients [1-4]. Although erlotinib has been shown to be effective for several types of cancer, severe adverse events related to erlotinib treatment, including ILD, have also been reported. The incidence of erlotinib-induced ILD in Japanese NSCLC patients is consistently reported to be higher than its incidence in the other parts of the world (4.5% vs. 1.0%) [1,2]. Although previous case reports have demonstrated the effectiveness of high-dose corticosteroid therapy for erlotinib-ILD, a treatment for erlotinib-ILD has not yet been established and the clinical outcome of erlotinib-ILD is very poor (36% mortality rate) [1].

Even after NSCLC patients recover from pulmonary toxicity caused by erlotinib-ILD, the management of these patients is difficult because of the deterioration of their performance status. Several cases of NSCLC patients successfully rechallenged with erlotinib following the development of gefitinib-induced ILD have been reported [5,6]; however, few cases of patients have received chemotherapy after recovery from EGFR-TKI-induced ILD. This is the rare case of erlotinib-induced ILD that recurred during subsequent radiotherapy or chemotherapy.

Herein, we describe a case of severe ILD in a NSCLC patient treated with erlotinib. Although ILD had improved by steroid therapy once previously, cytotoxic therapies, including palliative radiotherapy and irinotecan, recalled pneumonitis. The mechanism governing how ILD was repeatedly induced in this case is unknown. Previous findings indicated that EGFR-TKIs inhibit the EGFR-mediating signalling and interfere with the repair of lung injury [7]. Miyake et al. [8] also

demonstrated that EGFR-TKI increased infiltration of inflammatory cells into lungs, which produced pro-inflammatory cytokines using irradiated rat models [8]. A chest CT of our patient showed improvement of erlotinib-ILD by steroid treatment, but it is possible that pulmonary damage remained. One hypothesis is that radiation or irinotecan recalled damaged cells to inflammatory reaction.

## Conclusion

We reported a case of ILD repeatedly induced by various therapies for non-small cell lung cancer. We should consider the possibility of recurrent ILD in patients who develop ILD once and should make careful decisions regarding cancer treatment on the basis of adequate informed consent.

## References

1. Nakagawa K, Kudoh S, Ohe Y, Johkoh T, Ando M, et al. (2012) Postmarketing surveillance study of erlotinib in Japanese patients with non-small-cell lung cancer (NSCLC): an interim analysis of 3488 patients (POLARSTAR). J Thorac Oncol 7: 1296-1303.
2. Rosell R, Carcereny E, Gervais R, Vergnenegre A, Massuti B, et al. (2012) Erlotinib versus standard chemotherapy as first-line treatment for European patients with advanced EGFR mutation-positive non-small-cell lung cancer (EORTAC): a multicentre, open-label, randomised phase 3 trial. Lancet Oncol 13: 239-246.
3. Shepherd FA, Rodrigues Pereira J, Ciuleanu T, Tan EH, Hirsh V, et al. (2005) Erlotinib in previously treated non-small-cell lung cancer. N Engl J Med 353: 123-132.
4. Zhou C, Wu YL, Chen G, Feng J, Liu XQ, et al. (2011) Erlotinib versus chemotherapy as first-line treatment for patients with advanced EGFR mutation-positive non-small-cell lung cancer (OPTIMAL, CTONG-0802): a multicentre, open-label, randomised, phase 3 study. Lancet Oncol 12: 735-742.

5. Fukui T, Otani S, Hataishi R, Jiang SX, Nishi Y, et al. (2010) Successful rechallenge with erlotinib in a patient with EGFR-mutant lung adenocarcinoma who developed gefitinib-related interstitial lung disease. *Cancer Chemother Pharmacol* 65: 803-806.
6. Takeda M, Okamoto I, Makimura C, Fukuoka M, Nakagawa K (2010) Successful treatment with erlotinib after gefitinib-induced severe interstitial lung disease. *J Thorac Oncol* 5: 1103-1104.
7. Suzuki H, Aoshiba K, Yokohori N, Nagai A (2003) Epidermal growth factor receptor tyrosine kinase inhibition augments a murine model of pulmonary fibrosis. *Cancer Res* 63: 5054-5059.
8. Miyake K, Tani K, Kakiuchi S, Suzuka C, Toyoda Y, et al. (2012) Epidermal growth factor receptor-tyrosine kinase inhibitor (gefitinib) augments pneumonitis, but attenuates lung fibrosis in response to radiation injury in rats. *J Med Invest* 59: 174-185.