

Purulent Pericarditis: Report of a Case with Postoperative Chronic Pericardial Effusion

Chikahiko Koeda*, Maiko Hozawa, Kan Takahashi, Kunio Hirano, Shohei Yamaya, Karera Mukunoki, Masanobu Niyama and Iwao Goto

Department of Cardiology, Iwate Prefectural Kuji Hospital, Japan

Abstract

Nowadays, purulent pericarditis (PP) has become a rare disease with the increased use of antibiotics in clinical practices. The outcome of PP is poor due to severe infection and haemodynamic failure by the inhibition of the ventricle repletion, and no consensus exists on the treatment. We describe a case of PP with postoperative chronic pericardial effusion changing to the abscess. Following literature, the patient was treated with drainage and intrapericardial injection of urokinase. Inflammation and haemodynamic indexes with the transthoracic echocardiography were improved. We report a valuable case with literature discussion.

Keywords: Purulent pericarditis; Bacterial translocation; Sepsis

Introduction

Purulent pericarditis (PP) is a serious disease characterized with formation of abscess in the pericardial sac with the mortality rate of 20% to 30% [1]. We describe a case of PP with localized chronic pericardial effusion changing to the abscess hematogenously, and had a good outcome by drainage and intrapericardial injection of urokinase to pericardial effusion.

Case Report

A 70-year-old male was admitted to our hospital for chills and abdomen distension. His past medical history were infective endocarditis, and chronic kidney disease. In his 50's, he had enforced aortic valve replacement and mitral valve plasty with no surgical complications and the empyema was completely eliminated. Nine years after surgery, he had a localized chronic pericardial effusion in a left ventricle (LV) backside with computed tomography (CT) and transthoracic echocardiography (TTE) without any findings of inflammation.

His clinical characteristics were: height 165 cm, weight 75.5 kg, blood pressure 108/74 mmHg, heart rate 79 beats per minute, body temperature 38.4°C, and heart sound was pericardial knock. The jugular venous distention was 12 cm, and it showed a paradoxical rise during inspiration. Blood test results were as follows: White blood cell $13.4 \times 10^3 / \mu\text{L}$, C-reactive protein 13.2 mg/dL, blood urea nitrogen 47.3 mg/dL, serum creatinine 2.1 mg/dL, brain natriuretic peptide (BNP) 293.9 pg/mL. A chest X-ray showed a cardiothoracic ratio of 79% with lung congestion and pleural fluid. The size of the chronic pericardial fluid of the LV backside was constant with CT. TTE and transesophageal echocardiography revealed a high brightness on posterolateral pericardium, and fibrin deposits in cardiac sac (Figure 1). The findings of infective endocarditis such as vegetation and abscesses were not found. The respiratory fluctuation of two ventricle inflow velocity patterns was not clear. Two atriums were large, and the posterior wall flattened in mid diastolic LV wall motion. The interventricular septal wall showed the early diastolic notch. The reversal hepatic venous flow in diastolic phase increased (Figure 2a-2f).

Although an inflammatory focus was not clear after hospitalization, we started intravenous antibiotic treatment with Tazobactam-Piperacillin hydrate after having blood cultures (Figure 3). In addition, the abdominal symptom was judged as a right heart failure sign due to constrictive pericarditis after the open heart surgery because physical examination and TTE findings were concordant with constrictive pericarditis, and we added Tolvaptan for right heart failure.

Enterococcus was detected in blood cultures, and we changed the antibiotics to the meropenem while using a gamma globulin together from the eighth day, but the inflammatory reaction passed without any improvement. On the 18th day, systemic gallium scintigraphy revealed accumulation in cardiac sac. This site showed a high signal with a magnetic resonance imaging (MRI) diffusion weighted image and a T2-weighted image. Hence, it had diagnosis of an abscess with clinical course. The patient underwent drainage of pericardial effusion guided by a CT on the 21st day (Figure 2d-2e). After draining 180 ml of effusion, it was odorless and turbidity like a café au lait (Figure 4a). In this fluid, bacterial culture result showed no growth, but white blood cell was high at $256.0 \times 10^3 / \mu\text{L}$. The patient was treated with transcatheter intrapericardial saline and urokinase (120,000 IU each, three times a day for two days) and the tendency for the inflammatory reaction had disappeared. A fibrinous deposit was shown in washings (Figure 4b).

Soon after the drainage, an abdominal symptom disappeared, but the jugular venous distention was remained. On the TTE findings, the flattening finding of the posterior LV wall in the early phase of diastolic filling had disappeared. Then, the LV diastolic diameter spread, and the diastolic phase reflux wave form in the hepatic vein has decreased. There was reflected expansion of the capacity in the LV and the estimated stroke volume increased from 46 ml to 86 ml. The BNP value at the chronic stage decreased to 95.1 pg/mL whereas the BNP value at the admission was 293.9 pg/mL, and the patient was discharged on the 50th day.

Discussion

PP is a serious bacterial infection with a high mortality rate. The primary source of PP in the pre-antibiotics era was pneumonia, and accounts for 40% of acute constrictive pericarditis [1]. In the 1960s, some PP cases were reported frequently as much as a review of 425 cases [2], but PP cases have become rare and hematogenous infection

*Corresponding author: Koeda C, Department of Cardiology, Iwate Prefectural Kuji Hospital, 10-1 Asahityou, Kuji, Iwate 028-8040, Japan, Tel: +81-194-53-6131; Fax: +81-194-52-2601; E-mail: c-koeda@pred.iwate.jp

Received August 08, 2016; Accepted September 16, 2016; Published September 22, 2016

Citation: Koeda C, Hozawa M, Takahashi K, Hirano K, Yamaya S, et al. (2016) Purulent Pericarditis: Report of a Case with Postoperative Chronic Pericardial Effusion. J Clin Case Rep 6: 856. doi: [10.4172/2165-7920.1000856](https://doi.org/10.4172/2165-7920.1000856)

Copyright: © 2016 Koeda C, et al. This is an open-access article distributed under the terms of the Creative Commons Attribution License, which permits unrestricted use, distribution, and reproduction in any medium, provided the original author and source are credited.

in recent years, and the epidemiological surveys have become less and small-scale. Although the most common microorganisms were *Streptococci*, *Pneumococci*, and *Staphylococci* [3,4], several reports have listed *Escherichia coli* as the causative bacteria [5].

This case was sepsis, and the inflammatory focus was confirmed to a cardiac sac by systemic gallium scintigraphy. Based on the result of MRI which confirmed the features of abscess, we strongly suspected the patient with PP. The culture results of the pericardial fluid were negative, but we should not ignore the likelihood of the PP because

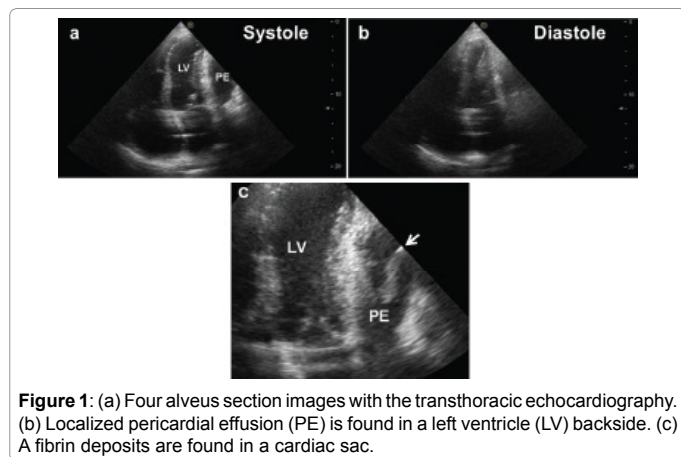


Figure 1: (a) Four-lead section images with the transthoracic echocardiography. (b) Localized pericardial effusion (PE) is found in a left ventricle (LV) backside. (c) Fibrin deposits are found in a cardiac sac.

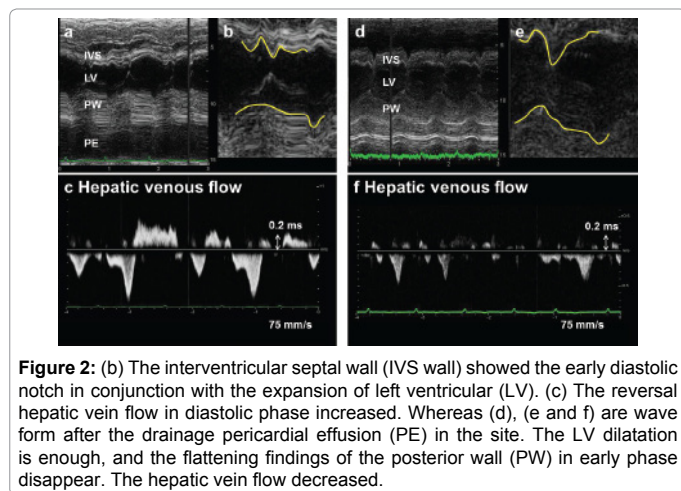


Figure 2: (b) The interventricular septal wall (IVS wall) showed the early diastolic notch in conjunction with the expansion of left ventricular (LV). (c) The reversal hepatic vein flow in diastolic phase increased. Whereas (d), (e) and (f) are wave form after the drainage pericardial effusion (PE) in the site. The LV dilatation is enough, and the flattening findings of the posterior wall (PW) in early phase disappear. The hepatic vein flow decreased.

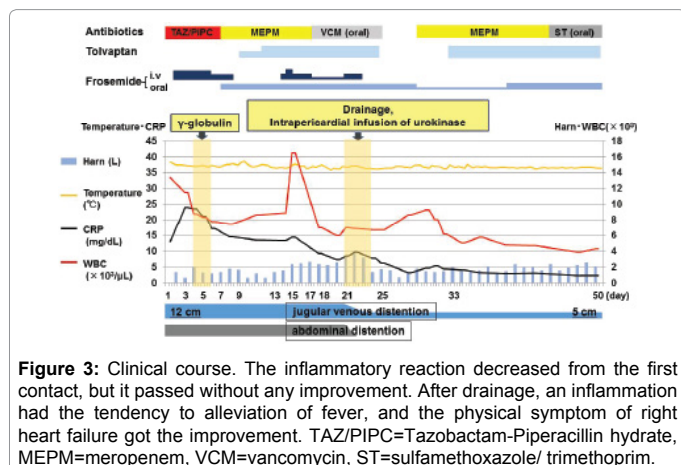


Figure 3: Clinical course. The inflammatory reaction decreased from the first contact, but it passed without any improvement. After drainage, an inflammation had the tendency to alleviation of fever, and the physical symptom of right heart failure got the improvement. TAZ/PIPC=Tazobactam-Piperacillin hydrate, MEPM=meropenem, VCM=vancomycin, ST=sulfamethoxazole/ trimethoprim.

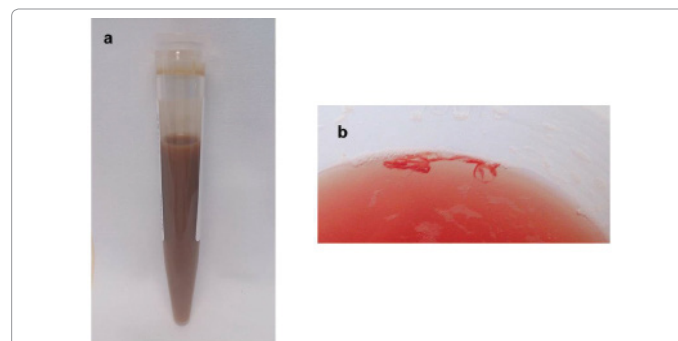


Figure 4: (a) The coloring matter like a cafe au lait was obtained from the cardiac sac (b) A fibrin deposit was aspirated when the cardiac sac of the patient was rinsed with saline and urokinase irrigation.

several reports have demonstrated that 16 out of 21 PP cases were no growth in the past [6], and there was detected many inflammatory cells in pericardial fluid.

PP affects the hemodynamics and it also has other factors as the chronic inflammatory disease due to the abscess. There is no consensus about its treatment, but many reports have investigated the efficacy of intrapericardial fibrinolysis with urokinase and pericardiocentesis [1,7]. In the controlled trial where cardiac sac of patients were rinsed with saline and they were treated with urokinase irrigation, fibrous formation to make intrapericardial surface become fibrotic was inhibited in patients who were treated with urokinase, and it significantly reduced the thickness and adhesion of pericardium [7]. On the other hand, there are few reports about serious complication by the intrapericardial fibrinolysis.

The respiratory-dependent change of the hepatic venous flow, ventricle inflow velocity patterns and the flattening of mid and late diastolic LV wall motion were known as the characteristics of constrictive pericarditis [8], and the improvement of those indexes and stroke volume were confirmed in this case. The drainage of an abscess mechanically may be the best method for haemodynamic stabilization with improvement of the ventricular filling and removal of the infection focus. On the other hand, this case was considered as basis on constrictive pericarditis that was already formed for long term after an open heart surgery, because jugular distention did not completely disappear. It is necessary to follow clinical course carefully to see how the protective efficacy of the prevention of pericardial constriction for chronic phase by the intrapericardial fibrinolysis with urokinase affects the prognosis of this case.

Although the primary source of infection in this case was undetected because the culture results of the pericardial fluid were no growth, the *Enterococcus* which was the main pathogen as origin bacteria of bacterial translocation was detected by blood cultures [9,10]. Furthermore, intestinal immunocompetence decreases with the patients of chronic heart failure with edema [11]. Thus, immunomechanism of the intestinal mucosa in this case has failed due to chronic right heart failure and fell into sepsis by a mechanism of bacterial translocation, and it was considered that a localized pericardial fluid caused the abscess hematogenously. Since there is no previous paper that reported chronic pericardial effusion changing to the abscess, this investigation was considered as a rare case.

Conclusions

We experienced a case of PP with localized chronic pericardial effusion that caused the abscess. After performing the drainage and injection of

urokinase in the cardiac sac for PP, inflammation and haemodynamic system improved, and we were able to obtain a good outcome.

References

1. Augustin P, Desmard M, Mordant P, Lasocki S, Maury JM, et al. (2011) Clinical review: Intrapericardial fibrinolysis in management of purulent pericarditis. *Critical Care* 15: 220.
2. Boyle JD, Pearce ML, Guze LB (1961) Purulent pericarditis: review of literature and report of eleven cases. *Medicine* 40: 119-144.
3. Sagristà-Sauleda J, Barrabés JA, Permanyer-Miralda G, Soler-Soler J (1993) Purulent pericarditis: review of a 20-year experience in a general hospital. *J Am Coll Cardiol* 22: 1661-1665.
4. Tokuyasu H, Saitoh Y, Harada T, Touge H, Kawasaki Y, et al. (2009) Purulent Pericarditis Caused by the *Streptococcus milleri* Group: A Case Report and Review of the Literature. *Inter Med* 48: 1073-1078
5. Parikh SV, Memon N, Echols M, Shah J, McGuire DK, et al. (2009) Purulent Pericarditis: report of 2 Cases and Review of the Literature. *Medicine* 88: 52-65
6. Liem NT, Tuan T, Dung le A (2006) Thoracoscopic pericardiectomy for purulent pericarditis: experience with 21 cases. *J Laparoendosc Adv Surg Tech A* 16: 518-521.
7. Cui HB, Chen XY, Cui CC, Shou XL, Liu XH, et al. (2005) Prevention of pericardial constriction by transcatheter intrapericardial fibrinolysis with urokinase. *Chin Med Sci J* 20: 5-10.
8. Oh JK, Hatle LK, Seward JB, Danielson GK, Schaff HV, et al. (1994) Diagnostic role of Doppler echocardiography in constrictive pericarditis. *J Am Coll Cardiol* 23: 154-162.
9. Berg RD, Garlington AW (1979) Translocation of certain indigenous bacteria from the gastrointestinal tract to the mesenteric lymph nodes and other organs in a gnotobiotic mouse model. *Infect Immun* 23: 403-411.
10. O'Boyle CJ, MacFie J, Mitchell CJ, Johnstone D, Sagar PM, et al. (1998) Microbiology of bacterial translocation in humans. *Gut* 42: 29-35.
11. Niebauer J, Volk HD, Kemp M, Dominguez M, Schumann RR, et al. (1999) Endotoxin and immune activation in chronic heart failure: a prospective cohort study. *Lancet* 353: 1838-1842.