

## Pupil-sparing Isolated Fascicular Third Cranial Nerve Palsy due to Infarction: Report of a Case and Literature Review

Min-Ju Kang<sup>1</sup>, Dong-Jin Shin<sup>1</sup>, Kwang-Dong Choi<sup>2</sup>, Ji-Soo Kim<sup>3</sup> and Dong Hoon Shin<sup>1\*</sup>

<sup>1</sup>Department of Neurology, Gachon University Gil Medical Center, Incheon, South Korea

<sup>2</sup>Department of Neurology, Pusan National University Hospital, Busan, South Korea

<sup>3</sup>Department of Neurology, Seoul National University College of Medicine, Seoul National University Bundang Hospital, Seoul, South Korea

\*Corresponding author: Dong Hoon Shin, Department of Neurology, Gachon University Gil Medical Center, Incheon, South Korea, Tel: +82-32-460-3346; Fax: +83-32-460-3344; E-mail: [dr.donghoon.shin@gmail.com](mailto:dr.donghoon.shin@gmail.com)

Rec date: Oct 08, 2016, Acc date: Oct 14, 2016, Pub date: Oct 16, 2016

Copyright: © 2016 Kang MJ, et al. This is an open-access article distributed under the terms of the Creative Commons Attribution License, which permits unrestricted use, distribution, and reproduction in any medium, provided the original author and source are credited.

### Abstract

Because of their anatomic proximity, pupillary and inferior rectus functions are linked in most cases of fascicular oculomotor palsy, with either sparing or involvement of both. A 40-year-old woman presented with painless binocular diplopia and left ptosis. Examination additionally showed limitations of the adduction and depression in the presence of normal supraduction and intact pupillary function in the left eye.

Findings of other neurological neuro-ophthalmologic examination were normal. A magnetic resonance imaging revealed a diffusion restriction in the left dorsomedial midbrain. An ischemic lesion restricted to the oculomotor fascicles can cause inferior rectus palsy in the presence of pupillary sparing, which should be differentiated from a microvasculopathic lesion involving the subarachnoid portion of the oculomotor nerve.

**Keywords:** Midbrain; Cerebral infarct; Oculomotor fascicle; Diplopia; ptosis; Unilateral

### Introduction

Pupil-sparing isolated third cranial nerve palsy mostly indicates a microvascular lesion involving the subarachnoid portion of the oculomotor nerve. Even though isolated fascicular third cranial palsy is extremely rare, it was once suggested that pupillary and inferior rectus functions may be linked, with sparing or involvement of both, in most cases of fascicular oculomotor palsy since the nerve fibers for the inferior rectus and pupil sphincter are located nearby in the oculomotor fascicles [1-4].

Herein, we present a patient with unilateral ptosis, and medial and inferior rectus palsy without a pupillary involvement from a midbrain infarction. We also performed a systematic literature review of the cases on isolated fascicular third nerve palsy to confirm that co-involvements or co-sparing of the inferior rectus and pupillary function is the rule in lesions involving the oculomotor fascicle.

### Case Report

A 40-year-old woman presented sudden binocular diplopia and left ptosis for two days. She also reported mild headache and nausea with the ocular symptoms. She had a history of an anterior chamber paracentesis for central retinal artery occlusion in the left eye two years before. Findings of general physical examination were normal. The patient showed an incomplete left ptosis and limitations of adduction and depression. However, the supraduction, abduction and pupillary function were preserved (Figure 1a).

Findings of other neurologic examination were normal. The electrolytes, renal function, and complete blood counts were also

within normal ranges. However, the activity of protein S was measured 38% (normal range: 55% to 123%). Magnetic resonance imaging (MRI) showed a focal diffusion restriction involving the left dorsomedial portion of lower midbrain. No vascular abnormalities or other parenchymal lesions were found (Figure 1b). She was diagnosed with pupil sparing isolated fascicular third cranial nerve palsy from an acute midbrain infarction due to protein S deficiency. The ptosis and adduction limitation began to improve two days later, and resolved by two weeks.

### Literature Review

We conducted a review of the literature on clinical features of fascicular third cranial nerve palsy due to ischemia. This was performed by a web-based search for English ([www.ncbi.nlm.nih.gov/pubmed](http://www.ncbi.nlm.nih.gov/pubmed)) publications using the following terms: oculomotor nerve; third cranial nerve; stroke; ischemia; ischemic; infarct; infarction; fascicle; fascicular palsy; midbrain; mesencephalon; intra-axial. Our search was conducted up to June, 2016. In addition, we reviewed the reference list of the articles identified by this search strategy. We excluded the cases with an etiology other than infarction (such as hemorrhage, demyelinating, inflammation, infection, and compression by mass), oculomotor nuclear involvement, or other cranial nerve palsy. Patients without original data or a confirmation with MRI were also excluded.

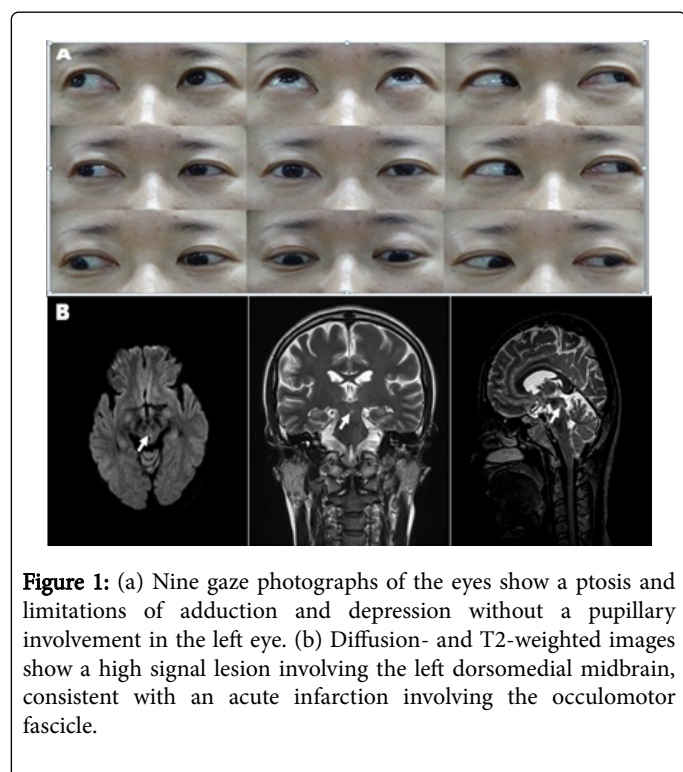
We recruited 52 articles, and 24 of which were excluded due to absence of description on ocular motor findings (n=3), lack of MR imaging (n=2), other etiologies than ischemia (n=4), language other than English (n=12), and associated ophthalmologic abnormalities such as oscillopsia and horizontal gaze palsy (n=3). After a full-text review, we identified 46 cases of oculomotor fascicular palsy due to

midbrain infarct [5–33]. The demographics and clinical characteristics of these cases are shown in Table 1.

Author	Age/Gender	Signs	Pupil involve	Prevalence (%)
<b>Both IR and pupillary involvement</b>				15.2
1	Bogousslavsky J. et al. [5]	71/F	IR, MR, IO, SR, LP	yes
2	Bogousslavsky J. et al. [5]	63/F	IR, MR, IO, SR, LP	yes
3	Saeki N et al. [6]	67/M	IR, MR, IO, SR, LP	yes
4	Leys D et al. [7]	43/M	IR, MR, IO, SR	yes
5	Ogawa K et al. [8]	75/F	IR, MR, LP	yes
6	Ogawa K et al. [8]	51/M	IR, MR, LP	yes
7	Randhawa S et al. [9]	48/M	IR, MR, IO, SR, LP	yes
<b>Pupillary involvement with sparing of IR</b>				17.4
8	Castro O et al. [10]	69/M	IO	yes
9	Murakami M et al. [11]	62/M	MR, LP	yes
10	Tsuda H et al. [12]	30/M	MR, IO, SR	yes
11	Ogawa K et al. [13]	40/F	MR	yes
12	Ogawa K et al. [13]	30/M	MR, SR	yes
13	Celebisoy N et al. [14]	62/M	IO, SR, LP	yes
14	Chen L et al. [15]	38/M	LP	yes
15	Hashimoto M et al. [16]	55/M	none	yes
<b>IR involvement with sparing of pupil</b>				26.1
16	Ogawa K et al. [13]	55/M	IR, MR, SR	no
17	Champion BL et al. [17]	24/F	IR, MR, IO, SR, LP	no
18	Breen LA et al. [18]	78/F	IR, MR, IO, SR, LP	no
19	Lee DK et al [19]	56/F	IR	no
20	Saeki N et al. [6]	68/F	IR, MR, IO, SR, LP	no
21	Tsuda H et al. [20]	72/M	IR, MR, SR, IO, LP	no
22	Kim JS et al. [21]	53/M	IR, MR, IO, SR, LP	no
23	Kim JS et al. [21]	42/F	IR	no
24	Negoro K et al. [22]	73/F	IR	no
25	Ogawa K et al. [13]	70/M	IR, MR, SR, LP	no
26	Ogawa K et al. [8]	61/M	IR, MR, SR	no
27	Tsuda H et al. [23]	80/M	IR, MR, IO, SR, LP	no
<b>Sparing of both IR and pupil</b>				41.3
28	Schwartz TH. et al [24]	34/F	LP, MR, IO, SR	no
29	Purvin V [25]	72/M	MR, IO, SR, LP	no
30	Saeki N et al. [26]	52/M	MR, IO, SR	no

31	Rabadi MH et al. [27]	79/M	MR, LP	no	
32	Miura K et al. [28]	69/M	MR, IO, SR, LP	no	
33	Hriso E et al. [29]	75/F	IO, SR, LP	no	
34	Khurana DD et al. [30]	68/M	MR, LP	no	
35	Tsuda H et al. [20]	70/M	MR, IO, SR, LP	no	
36	Amano et al. [31]	74/M	MR, IO, SR, LP	no	
37	Amano et al. [31]	66/M	MR, IO, SR, LP	no	
38	Amano et al. [31]	79/M	MR, IO, SR, LP	no	
39	Amano et al. [31]	71/M	MR, IO, SR, LP	no	
40	Amano et al. [31]	58/M	IO, SR, LP	no	
41	Fujioka T et al. [32]	49/M	MR, IO, SR, LP	no	
42	Ogawa K et al. [13]	88/F	SR	no	
43	Ogawa K et al. [13]	74/F	MR, SR, LP	no	
44	Ogawa K et al. [8]	78/M	MR, LP	no	
45	Choi YJ et al. [33]	57/F	IO, SR, LP	no	
46	Choi YJ et al. [33]	71/F	IO, SR, LP	no	

**Table 1:** Reported cases with isolated oculomotor fascicular infarction.



## Discussion

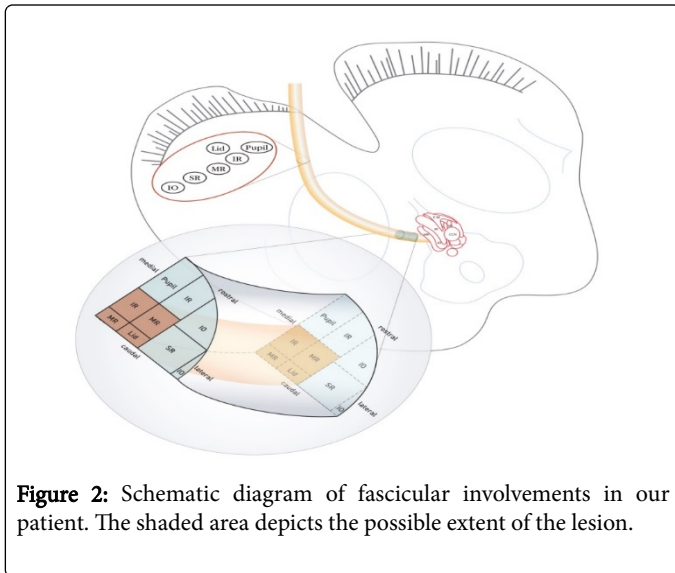
Our patient developed isolated fascicular third cranial nerve palsy due to an acute midbrain infarction. Of interest, the supraduction and pupillary function were spared in the presence of ptosis and limitations of adduction and infraduction.

The oculomotor fascicles are somatotopically arranged from lateral to medial [2] and rostrocaudally (Figure 2) [3,4]. Since the fascicles for the inferior rectus and pupillary sphincter are located adjacently in the rostral and medial part of the oculomotor fascicles [3,4], it was once suggested that the oculomotor fascicular infarctions may co-involve or co-spare the fibers for the pupillary sphincter and inferior rectus [1]. It was also presumed that preserved pupillary function in the presence of inferior rectus indicates an extra-axial oculomotor nerve palsy [1].

However, our patient with inferior rectus palsy and normal pupillary function from an infarction involving the oculomotor fascicle does not support this presumption (Figure 2). Furthermore, a thorough literature review revealed several cases of pupil-sparing inferior rectus palsy from ischemic lesions involving the oculomotor fascicle (Table 1). Indeed, the pupil was spared in 26.1% of patients with fascicular inferior rectus palsy and the inferior rectus was preserved in 17.4% of patients with an involvement of the pupillary fascicle.

Pupil-sparing isolated third cranial nerve palsy mostly indicates a microvascular lesion involving the subarachnoid portion of the oculomotor nerve. However, the pupillary function was spared in the majority of patients (67.4%) with isolated oculomotor palsy from a fascicular infarction.

To the best of our knowledge, this is the first report on fascicular involvements of the inferior and medial recti and levator palpebrae in the presence of normal superior rectus function due to a midbrain infarction. Thus, fascicular lesions usually spare pupillary fibers and may involve fascicular subdivisions in various combinations. Even though rare, a fascicular lesion should also be considered in patients with isolated pupil-sparing third cranial nerve palsy.



**Figure 2:** Schematic diagram of fascicular involvements in our patient. The shaded area depicts the possible extent of the lesion.

## References

- Johkura K (2009) Examination of eye movement. *Shinkeinaika* 70: 1-7.
- Warwick R (1953) Representation of the extra-ocular muscles in the oculomotor nuclei of the monkey. *J Comp Neurol* 98: 449-503.
- Ksiazek SM, Slamovits TL, Rosen CE, Burde RM, Parisi F (1994) Fascicular arrangement in partial oculomotor paresis. *Am J Ophthalmol* 118: 97-103.
- Abdollah A, Francis G (1990) Intraaxial divisional oculomotor nerve paresis suggests intraaxial fascicular organization. *Ann Neurol* 28: 589-590.
- Bogousslavsky J, Maeder P, Regli F, Meuli R (1994) Pure midbrain infarction clinical syndromes, MRI, and etiologic patterns. *Neurology* 44: 2032-2032.
- Saeki N, Murai N, Sunami K (1996) Midbrain tegmental lesions affecting or sparing the pupillary fibres. *J Neurol Neurosurg Psychiatry* 61: 401-402.
- Leys D, Nègre A, Rondepierre P, Ares G, Godefroy O (1992) Small infarct limited to the ventromedial part of the red nucleus: partial, transient and isolated unilateral oculomotor nerve palsy. *Cerebrovasc Dis* 2: 378-379.
- Ogawa K, Suzuki Y, Takahashi K, Kamei S, Ishikawa H (2016) Clinical study of eleven patients with midbrain infarction-induced oculomotor nerve palsy. *J Stroke Cerebrovasc Dis* 25(7): 1631-1638.
- Randhawa S, Donohue MM, Hamilton SR (2010) Concomitant presentation of three rare mesencephalic syndromes: Case report. *Clin Neurol Neurosurg* 112: 697-700.
- Castro O, Johnson LN, Mamourian AC (1990) Isolated inferior oblique paresis from brain-stem infarction: perspective on oculomotor fascicular organization in the ventral midbrain tegmentum. *Arch Neurol* 47: 235-237.
- Murakami M, Kitano I, Hitoshi Y, Ushio Y (1994) Isolated oculomotor nerve palsy following midbrain infarction. *Clin Neurol Neurosurg* 96: 188-190.
- Tsuda H, Ishikawa H, Majima T, Sawada U, Mizutani T (2005) Isolated oculomotor nerve palsy in Churg-Strauss syndrome. *Intern Med* 44: 638-640.
- Ogawa K, Suzuki Y, Oishi M, Kamei S (2011) Clinical study of twenty-one patients with pure midbrain infarction. *Eur Neurol* 67: 81-89.
- Çelebisoy N, Çelebisoy M, Tokuçoğlu F, Özdemir I (2006) Superior division paresis of the oculomotor nerve: Report of four cases. *Eur Neurol* 56: 50-53.
- Chen L, Maclaurin W, Gerraty R (2009) Isolated unilateral ptosis and mydriasis from ventral midbrain infarction. *J Neurol* 256: 1164-1165.
- Hashimoto M, Ohtsuka K (1998) Bilateral internal ophthalmoplegia as a feature of oculomotor fascicular syndrome disclosed by magnetic resonance imaging. *Am J Ophthalmol* 125: 121-123.
- Champion BL, Choy F, Schrieber L, Roche J, Rowe DB (2002) Isolated fascicular oculomotor nerve palsy as the initial presentation of the antiphospholipid syndrome. *J Clin Neurosci* 9: 691-694.
- Breen LA, Hopf HC, Farris BK, Gutmann L (1991) Pupil-sparing oculomotor nerve palsy due to midbrain infarction. *Arch Neurol* 48: 105-106.
- Lee DK, Kim JS (2006) Isolated inferior rectus palsy due to midbrain infarction detected by diffusion-weighted MRI. *Neurology* 66: 1956-1957.
- Tsuda H, Tanaka K (2012) Clinico-anatomical analysis of the fibers to the inferior rectus muscle in the oculomotor fascicles. *Intern Med* 51: 2031-2034.
- Kim JS, Kang JK, Lee SA, Lee MC (1993) Isolated or predominant ocular motor nerve palsy as a manifestation of brain stem stroke. *Stroke* 24: 581-586.
- Negoro K, Sasabe F, Morimatsu M (1993) Isolated inferior rectus muscle paresis from midbrain infarction. *Rinsho Shinkeigaku* 33: 434-436.
- Tsuda H, Fujita T, Maruyama K, Ishihara M (2015) Claude's syndrome without ptosis caused by a midbrain infarction. *Intern Med* 54: 1799-1801.
- Schwartz TH, Lycette CA, Yoon SS, Kargman DE (1995) Clinoradiographic evidence for oculomotor fascicular anatomy. *J Neurol Neurosurg Psychiatry* 59: 338.
- Purvin V (2010) Isolated fascicular third nerve palsy. *J Neuroophthalmol* 30: 263-265.
- Saeki N, Murai H, Mine S, Yamaura A (2000) Fascicular arrangement within the oculomotor nerve MRI analysis of a midbrain infarct. *J. Clin. Neurosci* 7: 268-270.
- Rabadi MH, Beltmann MA (2005) Midbrain infarction presenting isolated medial rectus nuclear palsy. *Am J Med* 118: 836-837.
- Miura K, Nagaoka T, Ikeda K, Hirayama T, Kawabe K, et al. (2012) A case of inferolateral oculomotor fascicular infarction: a review of the clinoradiological literature. *Intern Med* 51: 921-924.
- Hriso E, Masdeu JC, Miller A (1991) Monocular elevation weakness and ptosis: An oculomotor fascicular syndrome? *J Neuroophthalmol* 11: 111-113.
- Khurana DD (2011) Teaching neuroimages: A case of partial oculomotor palsy. *Neurology* 77: e150.
- Amano Y, Kudo Y, Kikyo H, Imazeki R, Yamamoto M, et al. (2015) Isolated unilateral oculomotor paresis in pure midbrain stroke. *J Neurol Sci* 351: 191-195.
- Fujioka T, Segawa F, Ogawa K, Kurihara T, Kinoshita M (1995) Ischemic and hemorrhagic brain stem lesions mimicking diabetic ophthalmoplegia. *Clin Neurol Neurosurg* 97: 167-171.
- Choi YJ, Lee SH, Park MS, Kim BC, Kim MK (2015) Midbrain infarction presenting with monocular elevation palsy and ptosis: topographic lesion analysis. *J Neuroophthalmol* 35: 175-178.