

Pulmonary Metastasis on TC-99m MDP Bone Scan Mimicking Metastatic Rib Lesions in Breast Cancer

Qi Cao^{1*}, Jonathon Heath², Jinqing Liang¹, Jian Zhang¹, Rikka Saito¹ and Ailin Cao³

¹Department of Diagnostic Radiology and Nuclear Medicine, University of Maryland School of Medicine, 22 S. Greene St., Baltimore, MD 21201, USA

²Department of Pathology, University of Maryland School of Medicine, 22 S. Greene St., Baltimore, MD 21201, USA

³School of Arts and Science, University of Pennsylvania, 120 Claudia Cohen Hall, 249 South 36th Street, Philadelphia, PA 19104-6304, USA

*Corresponding author: Qi Cao, Department of Diagnostic Radiology and Nuclear Medicine, University of Maryland School of Medicine, 22 S. Greene St., Baltimore, MD 21201, USA; Tel: +01 410 328 9586; Fax: +01 410 328 1600; E-mail: qcao@umm.edu

Received date: Jul 31, 2014, Accepted date: Feb 16, 2015, Publication date: Feb 19, 2015

Copyright: © 2015 Cao Q, et al. This is an open-access article distributed under the terms of the Creative Commons Attribution License, which permits unrestricted use, distribution, and reproduction in any medium, provided the original author and source are credited.

Abstract

Bone scan has been widely employed to detect osteoblastic bone metastasis because of the imaging technique's high sensitivity. However, care should be taken to distinguish false positive bone lesions which result from microcalcification of soft tissue malignancy with real osseous metastasis by correlating other modalities of fluorodeoxyglucose positron emission tomography/computed tomography (FDG PET/CT). We report, for the first time, a patient who was initially diagnosed with stage II left breast infiltrating ductal carcinoma and was under clinical management for 20 years. The patient subsequently presented with thoracic symptoms. Bone scan showed multiple focal uptakes within bilateral thoracic ribs. FDG PET/CT scans, however, showed numerous metabolically active bilateral pulmonary nodules with no osseous lesions in ribs. This case demonstrates abnormal findings on bone scans mimicking metastatic rib lesions from micro-calcified pulmonary metastatic nodules in a patient with breast cancer. Thus, care should be taken to correlate interpretation of high sensitivity but non-specificity bone imaging with other modalities such as FDG PET/CT.

Keywords: Whole body bone scan; FDG PET/CT; Breast cancer; Pulmonary metastasis; Bony metastasis

Summary

Tc-99m MDP whole body bone scan is very sensitive and widely applied for clinical staging, monitoring therapeutic response, and evaluating malignant tumor recurrence in patients with malignant cancers, specifically breast cancer in female patients, prostate cancer in male patients, and other cancers including pulmonary cancers. However, attention should be paid by clinicians when they dictate bone imaging given that the various false positive findings may diminish specificity of the study. We presented a case for the first time that demonstrates abnormal findings on bone scans mimicking metastatic rib lesions from micro-calcified pulmonary metastatic nodules in the patient with breast cancer.

Introduction

In addition to metastasis to regional lymph nodes, lung, liver, and brain, breast cancer also metastasizes to skeletal structures. Among the sites of bony metastasis, the thigh, sternum, and spinal vertebral bodies are very common [1]. Breast carcinoma is initially diagnosed by mammogram and biopsy. Computerized Tomography (CT) and F18-fluorodeoxyglucose (FDG) positron emission tomography/computed tomography (PET/CT) are useful in staging, measuring therapeutic response and detecting recurrence [1]. Breast cancers at stage III or stage IV are monitored with technetium-99m methylene diphosphate (99m Tc MDP) whole body bone scan (bone scan) for osteoblastic metastatic disease, while breast cancer at stage I and II is seldom monitored with bone scan because of less opportunity of osseous

metastasis at the early stages [2,3]. Bone scan for osteoblastic metastatic lesions is highly sensitive but not specific. False positive findings of bone scan result from microcalcification of soft tissue cancers, benign bone neoplasm, bone fracture, healing osseous trauma, and osteomyelitis [4-8]. In this case report, we describe a patient with a 20 year history of breast cancer who presented with symptomatic chest signs. Bone scan was performed to evaluate bone metastasis. Multiple thoracic ribs demonstrated radiotracer uptake on bone scan. Correlation of FDG PET/CT with bone scan excluded rib lesions. We learned from this case that abnormalities of non-osseous malignant lesions on bone scan could mimic metastatic osseous lesions, thus, physicians should seek to correlate these findings with other imaging techniques to avoid basing treatment on false positive findings.

Case Report

A 64-year-old African American female with history of stage II left breast infiltrating ductal carcinoma, status post radical mastectomy, axillary lymph node dissection and chemotherapy post 20 years presented complaining of increasing persistent hoarseness and dry cough. CT of the chest showed multiple bilateral pulmonary metastases (Figure 1) with no evidence of osseous lesions.

Fine needle aspiration of the lung mass and mass tissue histopathology showed moderately differentiated adenocarcinoma. Immunohistochemical staining revealed that the tumor was negative for estrogen receptor and progesterone receptor, but positive for high estrogen responders (HER)2/neu. Screening mammogram showed indeterminate new nodule in the right breast (data not shown). These findings are consistent with metastatic breast cancer.

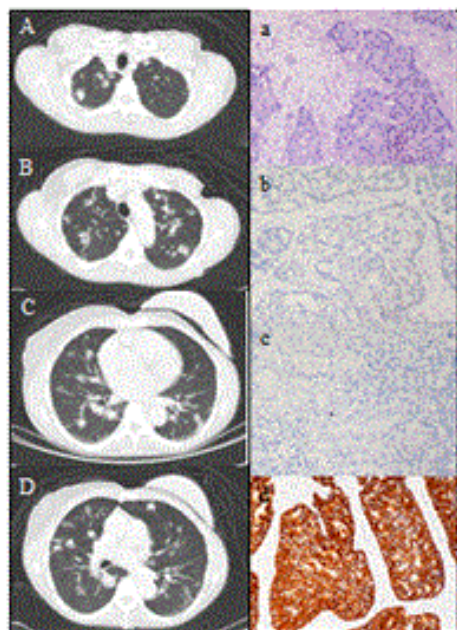


Figure 1: CT of chest and history of pulmonary nodules. CT of the chest showed multiple bilateral pulmonary metastases. A to D, axial views from apex to basal region of the lung. Fine needle aspiration of the lung nodules showed moderately differentiated adenocarcinoma on H&E staining (a). Immunohistochemical staining of the lung nodule biopsies for: (b), estrogen receptor, (c), progesterone receptor, and (d), positive for high estrogen responders (HER)2/neu. Original magnification, x400.

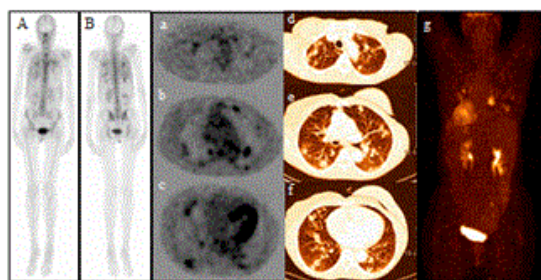


Figure 2: Whole body bone scan and FDG PET/CT images. Bone scan images of 99m Tc MDP demonstrated multiple foci of increased activity in chest with more prominence on the posterior view. A, anterior view, and B, posterior view. FDG PET/CT imaging for restaging demonstrated numerous metabolically active bilateral lung nodules compatible with extensive lung metastasis. There was no evidence of osseous liver or lymph node metastasis. a, b, and c, PET axial views from apex to basal lungs, d, e, and f, hybrid PET/CT axial views from apex to basal lung, and g, maximum intensity projection.

The patient underwent bone scan to evaluate osseous metastasis. Bone scan images acquired 180 minutes after intravenous injection of

1110 MBq of 99m Tc MDP demonstrated multiple foci of increased activity in chest with more prominence on the posterior view (Figure 2).

Abnormal focal uptake appeared within ribs on bone scan. The patient underwent FDG PET/CT imaging for restaging. FDG PET/CT imaging acquired 60 minutes after intravenous injection of 378 MBq of FDG demonstrated numerous metabolically active bilateral lung nodules compatible with extensive lung metastasis. There was no evidence of osseous liver or lymph node metastasis (Figure 2). It was determined after careful evaluation of both bone scan and PET/CT imaging, that the foci of uptake were most likely from microcalcification of lung metastatic lesions, rather than from rib metastasis.

Discussion

There are many reports demonstrating mimicking bony lesions on bone scan in patients with infectious and inflammatory diseases, and cancers including breast cancer [6-9]. But no reports demonstrate mimicking osseous metastasis in ribs on bone scan in patients with breast cancer. Breast cancer can metastasize to lymph nodes, bones including sternum, spine, and thighs, and other organs including lungs, liver, and brain through lymphatic and/or blood spreading [1,10]. Early stage of breast carcinoma is usually determined by mammogram, followed by biopsy and pathological diagnosis. The staging and restaging of breast cancer is usually made with CT and FDG PET/CT. Bone scan is the standard method to assess for metastatic lesions associated with breast cancers. These cancers have higher incidence of osteoblastic than osteolytic lesions. Suspicious bone metastasis which has high incidence in patients with stage III and IV breast cancer is normally monitored by bone scan. Bone scan is used less frequently in patients with stage I and II breast cancer, given the occurrence of osseous metastasis at early stages is rare [2,3].

Bone scan is non-specific but highly sensitive in diagnosing osseous metastasis. Bone scan shows more sensitivity than plain film, an advantage for whole body imaging. However, bone scan lacks specificity and mainly detects osteoblastic lesions. False positive findings can result from calcification of soft tissue of primary and metastatic malignancy, benign bone neoplasms, bone fracture, healing trauma, and osteomyelitis. The current case demonstrates multiple abnormal uptakes in the ribs of a patient with metastatic breast cancer. In correlation with FDG PET/CT imaging, we excluded osseous rib metastasis due to no corresponding active osseous lesions on PET/CT images. Further evaluation of the chest on FDG PET/CT demonstrated that diffuse pulmonary nodules contributed to mimicking rib lesions on bone scan. This mimicking rib metastasis from metastatic pulmonary nodules most likely resulted from microcalcification of the malignant tissues. This is the first time that metastatic pulmonary nodules mimicking rib metastatic lesions has been reported in the literature, although metastatic breast cancer demonstrates osseous lesions in a wide range of axial and appendicular skeleton, such as in spine [11], ribs [12], pelvic bone [13], femur [14], skull [15,16], and sternum [17]. Correlation of FDG PET/CT imaging findings assisted us in distinguishing these false positive events on bone scan. An accurate diagnosis enables appropriate therapy and management. Abnormal findings on body scan in patients with breast cancer or other cancers may represent infectious and inflammatory diseases, extra-skeletal muscular ossification and benign osseous tumor [1-5,18,19]. Correlation with other modalities such as MRI, CT, and FDG PET/CT provides further information to determine differential diagnosis and staging and restaging of breast cancer and other

malignant neoplasms. CT is more sensitive than plain films. But it is not as sensitive as bone scan for blastic lesions. MRI is nearly as sensitive as bone scan, with much higher anatomic resolution. However, MRI has limitations for whole body imaging and is restricted to regional problem solving. FDG PET/CT is very useful for identifying osseolytic and bone marrow lesions and is of significance for baseline disease burden, for therapeutic response, and for recurrence. A recent study shows the NaF18 PET imaging modality is of higher resolution than PET. NaF18 PET images have higher sensitivity than bone scan for identifying osseous metastasis, but this technique is not available clinically [20].

In this case, the patient demonstrated pure early stage breast cancer without any metastasis twenty years ago. She was stabilized until two years ago, at which point she presented with thoracic symptoms. Chest CT showed diffuse pulmonary nodular lesions with biopsy confirmation of metastatic breast cancer. To evaluate possible osseous metastasis, bone scan was performed. FDG PET/CT imaging was then acquired for restaging and it turned out that the patient showed extensive lung metastasis with no active osseous metastasis after careful comparison with abnormal findings on the bone scan. The findings of focal uptake in the ribs on bone scan was actually from micro-calcification of pulmonary metastatic lesions. The patient underwent chemotherapy. Follow up imaging demonstrated stability of the pulmonary lesions with no other new lesions detected.

Conclusions

In summary, the current case, for the first time, demonstrates mimicking metastatic rib lesions on bone scan in a patient with pulmonary metastatic lesions originated from recurrent breast cancer. Correlating findings of FDG PET/CT imaging with the metabolically active diffusive metastatic lesions only in the lungs adds important value to distinguish metastatic lung lesions from an abnormal appearing rib cage on bone scan.

References

1. Lee SC, Jain PA, Jethwa SC, Tripathy D, Yamashita MW (2014) Radiologist's role in breast cancer staging: providing key information for clinicians. *Radiographics* 34: 330-342.
2. Ouvrier MJ, Vignot S, Thariat J (2013) [State of the art in nuclear imaging for the diagnosis of bone metastases]. *Bull Cancer* 100: 1115-1124.
3. Glendenning J, Cook G (2013) Imaging breast cancer bone metastases: current status and future directions. *Semin Nucl Med* 43: 317-323.
4. Singh H, Sharma P, Naswa N, Nazar AH, Khangembam BC, et al. (2012) Schmorl's node mimicking metastasis in a patient with breast cancer: diagnosis with 99mTC methylene diphosphonate SPECT-CT. *Clin Nucl Med* 37: 674-675.
5. Hoos A, Berho M, Blumencranz PW, Brady MS (2000) Giant cellular blue nevus of the anterior chest wall mimicking metastatic melanoma to the breast: a case report. *J Surg Oncol* 74: 278-281.
6. Tomono H, Fujioka S, Kato K, Yoshida K, Nimura Y (1998) Multiple myeloma mimicking bone metastasis from breast cancer: report of a case. *Surg Today* 28: 1304-1306.
7. Statta J, Hahn S, Gauler T, Eberhardt W, Mueller SP, et al. (2009) Osteoblastic response as a healing reaction to chemotherapy mimicking progressive disease in patients with small cell lung cancer. *Eur Radiol* 19: 193-200.
8. Voravud N, Theriault R, Hortobagyi G (1992) Vertebral osteomyelitis mimicking bone metastasis in breast cancer patients. *Am J Clin Oncol* 15: 428-432.
9. Girschick HJ, Mornet E, Beer M, Warmuth-Metz M, Schneider P (2007) Chronic multifocal non-bacterial osteomyelitis in hypophosphatasia mimicking malignancy. *BMC Pediatr* 7: 3.
10. Sinn P, Aulmann S, Wirtz R, Schott S, Varga Z, et al. (2013) Multigene assays for classification, prognosis, and prediction in breast cancer: a critical review on the background and clinical utility. *Geburtshilfe Frauenheilkd* 73: 932-40.
11. Cheng P, Su X, Gao H, Zhang T1 (2013) All vertebral body metastases of breast cancer: a case report and literature review. *Eur J Gynaecol Oncol* 34: 473-475.
12. Kusama M (2012) Doxifluridine, medroxyprogesterone acetate and cyclophosphamide (DMPC) combination therapy found effective for case of chest wall recurrent breast cancer with bone and pleural metastases. *Gan To Kagaku Ryoho* 39: 1239-1241.
13. Twining P, Williams MR, Morris AH, Blamey RW (1988) The use of the pelvic radiograph alone to assess therapeutic response in bone metastases from breast cancer. *Clin Radiol* 39: 583-585.
14. Samsani SR, Panikkar V, Venu KM, Georgiannos D, Calthorpe D (2004) Breast cancer bone metastasis in femur: surgical considerations and reconstruction with Long Gamma Nail. *Eur J Surg Oncol* 30: 993-997.
15. Obajimi MO, Ogbole GI, Adeniji-Sofoluwe AT, Adeleye AO, Elumelu TN, et al. (2013) Cranial computed tomographic findings in Nigerian women with metastatic breast cancer. *Niger Med J* 54: 123-128.
16. Brucoli M, Arcuri F, Stellin L, Benech A (2010) Zygomatic metastasis from breast cancer. *J Craniofac Surg* 21: 2012-2014.
17. Tsuda M, Satou S, Ichiki K, Doki Y, Misaki T, et al. (2005) [Sternal metastasis of breast cancer; report of a case]. *Kyobu Geka* 58: 341-343.
18. Jakovljevic SD, Spasic MB, Milosavljevic MZ, Azanjac GL, Protrka ZM, et al. (2013) Pure primary osteosarcoma of the breast: a case report. *Eur J Gynaecol Oncol* 34: 476-479.
19. Jacene HA, Stearns V, Wahl RL (2006) Lymphadenopathy resulting from acute hepatitis C infection mimicking metastatic breast carcinoma on FDG PET/CT. *Clin Nucl Med* 31: 379-381.
20. Freesmeyer M, Stecker FF, Schierz JH, Hofmann GO, Winkens T (2014) First experience with early dynamic (18)F-NaF-PET/CT in patients with chronic osteomyelitis. *Ann Nucl Med* 28: 314-321.