

Protective effect of vitamin C on biochemical alterations induced by subchronic co-administration of chlorpyrifos and lead in Wistar rats

Ambali SF^{1*}, Angani M¹, Adole AO¹, Kawu MU¹, Shittu M¹, Akande MG² and Oladipo OO³

¹Department of Veterinary Physiology and Pharmacology, Ahmadu Bello University, Zaria, Nigeria

²Department of Veterinary Pharmacology and Toxicology, University of Abuja, Nigeria

³National Veterinary Research Institute, Vom, Nigeria

Abstract

Oxidative stress is one of the molecular mechanisms involved in chlorpyrifos (CPF) and lead poisoning. The present study investigated the role of vitamin C in mitigating the biochemical alterations induced by co-administration of CPF and lead. Forty adult male Wistar rats divided into 4 groups of 5 animals in each group were used for this study. Group I was dosed with corn oil (2 ml/kg) while group II was given vitamin C (100 mg/kg). Group III was co-administered CPF (4.25 mg/kg~ 1/20th LD₅₀) and Pb (225 mg/kg~1/20th LD₅₀) while group IV was pretreated with vitamin C (100 mg/kg) and then co-administered with CPF (4.25 mg/kg) and Pb (225 mg/kg), 30 min later. The regimens were administered once daily by oral gavage for a period of 9 weeks. The rats were sacrificed and sera obtained from the blood samples were analyzed for the total proteins, albumin, globulin, electrolytes (Na⁺, K⁺, Cl⁻), urea and liver malonaldehyde concentrations. The activities of serum aspartate aminotransferase, alanine aminotransferase, alkaline phosphatase, gamma-glutamyl transferase and lactate dehydrogenase were evaluated. The result showed that alterations in the biochemical parameters induced by co-exposure to CPF and lead were mitigated by pretreatment with vitamin C.

Keywords: Chlorpyrifos; lead; co-exposure; biochemical profiles; oxidative stress; vitamin C

Abbreviations: CPF-Chlorpyrifos; OP- Organophosphate; AST- Aspartate aminotransferase; ALT- Alanine aminotransferase; ALP- Alkaline phosphatase; GGT- Gamma glutamyl transferase; LDH- Lactate dehydrogenase; C/oil-corn oil; VC- Vitamin C

Introduction

The advancement in technology and the need to satisfy the basic needs of man has led to an increasing number of chemicals being deliberately released into the environment. These chemicals interact with each other and also with the environment resulting in adverse health and environmental consequences [1]. Current understanding of the toxicity of many environmental toxicants/pollutants is based primarily on toxicity studies performed on laboratory animals exposed to a single agent [2,3]. However, with the environment being perverted with multiple chemical contaminants interacting with each other, it is increasingly becoming clearer that animal models focusing on the effect of single contaminant will be most misleading because it does not reflect environmental reality.

Pesticides are one of the most pervasive groups of environmental chemicals that are being increasingly used due to the compelling need to feed the ever-growing human and animal population and to control public health. Organophosphate (OP) insecticides are one of the most widely used, accounting for about 50% global insecticide use [4]. Its widespread use has however been associated with adverse consequences on human and animal health. Following its introduction into the United States of America's market in 1965, chlorpyrifos (CPF) has been one of the most widely used OP insecticides in agriculture, horticulture and public health. Although some of its domestic uses have been banned by United States Environmental Protection Agency in 2000 [5], there is ample evidence that CPF remains one of the most common environmental contaminants [6,7].

Lead is the most ubiquitous heavy metal contaminant [8] because of its widespread industrial and domestic uses. Exposure to lead adversely affects human and animal health [9]. Lead is used in

industries and in the homes, and it is present in the soil where it poses a lot of risk to humans and animals [10]. Lead is a major source of environmental pollution and residues have been detected in children toys and household kitchen materials, watering cans and pipes [11].

From the foregoing, therefore, CPF and lead are among the most pervasive environmental contaminants, especially considering their persistent nature. Although both contaminants are known to cause multiple organ toxicity, the mechanisms by which each of these agents causes toxicity are quite different, some of them are interrelated. The induction of oxidative stress is a common biochemical mechanism implicated in CPF [1,12-19], and lead [8,20-22] poisonings. CPF and lead have been shown to increase the production of free radical and decrease the availability of antioxidant molecules that mitigate the resultant damage. Vitamin C is a low-molecular weight antioxidant molecule that protects the cellular compartment from hydrophilic oxygen-nitrogen radicals; a property that makes it an efficacious antioxidant of the hydrophilic phase [23,24]. Earlier studies have shown the ability of vitamin C to mitigate toxicity induced by CPF [1,14,16,19,25] and lead [26-29]. Although very few studies have shown that co-exposure to CPF and lead induces toxicity [30, 31], there has been paucity of information on the role of vitamin C in mitigating biochemical alterations induced by subchronic co-administration of CPF and lead. Therefore, the present study investigated the role of vitamin C in mitigating the biochemical alterations induced by

***Corresponding author:** Ambali S.F, Department of Veterinary Physiology and Pharmacology, Ahmadu Bello University, Zaria, Nigeria, Tel: +234 8037015411, E-mail: fambali2001@yahoo.com; atunluse@gmail.com

Received October 26, 2011; **Accepted** November 25, 2011; **Published** November 28, 2011

Citation: Ambali SF, Angani M, Adole AO, Kawu MU, Shittu M, et al. (2011) Protective effect of vitamin C on biochemical alterations induced by subchronic co-administration of chlorpyrifos and lead in Wistar rats. J Environment Analytic Toxicol 1:108. doi:10.4172/2161-0525.1000108

Copyright: © 2011 Ambali SF, et al. This is an open-access article distributed under the terms of the Creative Commons Attribution License, which permits unrestricted use, distribution, and reproduction in any medium, provided the original author and source are credited.

co-exposure to CPF and lead. This is especially in view of the role of biochemical profiling as a useful indicator of the health status of the individual and in predicting clinical outcomes.

Materials and Methods

Experimental animals

Forty 6-week old adult male Wistar rats weighing 132-146g were obtained from the Animal House of the Department of Veterinary Physiology and Pharmacology, Ahmadu Bello University, Zaria, Nigeria. The rats were fed on standard rat pellets and water provided *ad libitum*. The experiment was performed in compliance with the National Institutes of Health Guide for Care and Use of Laboratory Animals [32].

Chemicals

Commercial grade CPF (TERMICOT[®] 20% EC, Sabero Organics, Gujarat, India) was reconstituted in soya oil to make 10% stock solution, which was subsequently used for the experiment. Analytical grade lead acetate (Kiran Light Laboratories, Mumbai, India) used for the study was made into a 20% stock solution using distilled water. Commercial grade vitamin C tablets (Emzor Pharmaceutical Ltd, Nigeria, BN: 618N) were prepared in distilled water to make 10% stock solution just prior to daily administration.

Animal treatments

Forty weaned male Wistar rats were divided at random into four groups of 10 animals per group. Group I was administered corn oil (2 ml/kg), while group II was given vitamin C (100 mg/kg). Group III was co-administered CPF (4.25 mg/kg~1/20th LD₅₀ [25]) and lead acetate (225 mg/kg~1/20th LD₅₀ [29]), respectively. Group IV were pretreated vitamin C (100 mg/kg) and then co-administered CPF (4.25 mg/kg) and Pb (225 mg/kg), 30 min later. These regimens were administered orally by gavage once daily for a period of 9 weeks. The rats were examined for toxic signs. At the termination of the dosing, the animals were killed via jugular venesection after light chloroform anesthesia. Blood samples were collected into labeled test tubes and then incubated on the shelf for 30 min. These were then centrifuged at 800 x g for 10 minutes, to obtain sera samples used for the biochemical assays.

Evaluation of serum biochemical parameters

The sera samples were evaluated for the concentration of electrolytes (Na⁺, K⁺ and Cl⁻), total proteins (TP), albumin, urea, and the activities of aspartate aminotransferase (AST), alanine aminotransferase (ALT), alkaline phosphatase (ALP), gamma glutamyl transferase (GGT) and lactic dehydrogenase (LDH). These parameters were analyzed using an auto analyzer (Bayer Express Plus, Germany). Globulin concentration was obtained by subtracting albumin concentration from that of the total serum proteins, and consequently the albumin:globulin ratio was calculated.

Assessment of hepatic lipoperoxidation

The assessment of the level of hepatic lipoperoxidation was done by evaluating the malonaldehyde (MDA) concentration using the double heating method of Draper and Hadley [33] as modified by Yavuz et al. [34]. The MDA concentration was calculated by the absorbance coefficient, MDA-TBA complex 1.56x10⁵/cm and expressed in nmol/mg of protein. The protein concentration was determined using the method described by Lowry et al. [35].

Statistical analysis

Data were expressed as mean ±SEM and subjected to one-way analysis of variance followed by Tukey's multiple comparison test using Graph Pad Prism version 4.0. Values of P<0.05 were considered significant.

Results

Clinical signs

There was no clinical manifestation observed in C/oil and VC groups. However, rats in the CPF+Pb group showed lacrimation, congested ocular membranes, rough hair coat, piloerection, reduced feed intake and death in one animal. Lacrimation was the only apparent sign recorded in the VC+CPF+Pb group.

Serum electrolytes

There was no significant difference (P>0.05) in the Na⁺, K⁺ and Cl⁻ concentrations in between the groups. However, the serum concentration of each of these electrolytes was marginally higher in the CPF+Pb group compared to those recorded in the other groups (Figure 1).

Effect of treatments on serum proteins

The effect of treatments on serum protein concentrations is shown in Figure 2. There was a significant (P<0.01) decrease in the serum TP concentration in the CPF+Pb group compared to either C/oil or VC group. Although not significant (P>0.05), the TP concentration in the VC+CPF+Pb group increased by 9.4% relative to the CPF+Pb group. There was a significant (P<0.05) decrease in the TP concentration in the VC+CPF+Pb group compared to the VC group but no significant (P>0.05) change relative to that obtained in the C/oil group. There was no significant (P>0.05) change in the TP concentration in the C/oil group relative to those recorded in the VC group.

The albumin concentration in the CPF+Pb group decreased significantly (P<0.01) compared to that recorded in the C/oil or VC group. Although, not significant (P>0.05), the albumin concentration in the VC+CPF+Pb group increased by 9.4% compared to that recorded in the CPF+Pb group. There was no significant (P>0.05) change in the albumin concentration in the VC+CPF+Pb group compared to either C/oil or VC group. The albumin concentration in the C/oil group was not significantly different (P>0.05) from those obtained in the VC group (Figure 2).

The globulin concentration in the CPF+Pb group decreased significantly (P<0.05) relative to the VC group but no significant change (P>0.05) compared to either the C/oil or VC+CPF+Pb group. However, the globulin concentration in the CPF+Pb group was comparatively lower when compared to that of C/oil (16%) or VC+CPF+Pb (9%) group. There was no significant (P>0.05) change in the globulin concentration in the VC+CPF+Pb group relative to C/oil or VC group (Figure 2).

The effect of treatments on albumin/globulin ratio is shown in Figure 3. Although there was no significant (P>0.05) change in between the groups, the albumin/globulin ratio in the CPF+Pb group decreased marginally when compared to either C/oil (5%) and VC+CPF+Pb (1%) group but increased by 1% when compared to the VC group.

Effect of treatments on urea concentration

The effect of treatments on urea concentration is shown in Figure

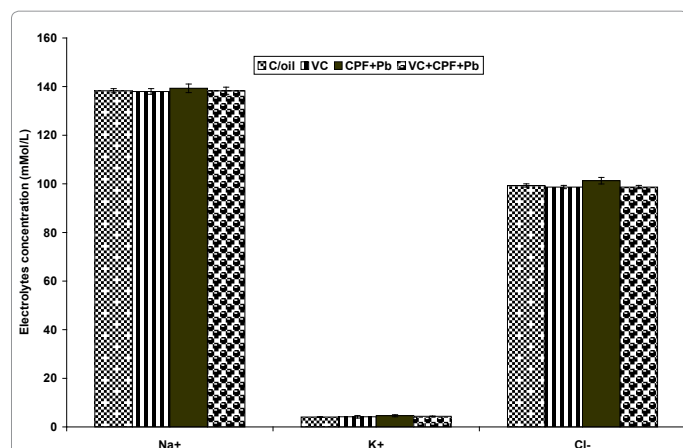


Figure 1: Effect of corn oil (C/oil), vitamin C (VC) and/or co-administration of chlorpyrifos (CPF) and lead (Pb) on serum electrolyte concentrations in Wistar rats.




Figure 2: Effect of corn oil (C/oil), vitamin C (VC) and/or co-administration of chlorpyrifos (CPF) and lead (Pb) on serum total proteins (TP), albumin and globulin concentrations in Wistar rats.^{ab}P<0.01 versus C/oil and VC, respectively; ^cP<0.05 versus VC.

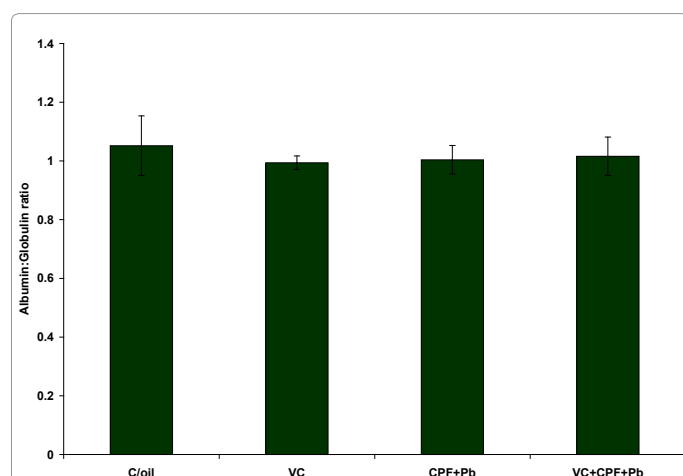


Figure 3: Effect of corn oil (C/oil), vitamin C (VC) and/or co-administration of chlorpyrifos (CPF) and lead (Pb) on albumin:globulin ratio concentrations in Wistar rats.

4. There was a significant increase in urea concentration in the CPF+Pb group relative to either the C/oil ($P<0.01$) or VC ($P<0.05$) group but no significant change ($P>0.05$) was recorded when compared to that of VC+CPF+Pb group. However, the urea concentration in the CPF+Pb group increased by 16% relative to VC+CPF+Pb group. There was a significant ($P<0.05$) increase in urea concentration in the VC+CPF+Pb group relative to C/oil group but no significant ($P>0.05$) change was recorded when compared to the VC group. There was no significant ($P>0.05$) change in the urea concentration in the C/oil group relative to VC group.

Effect of treatments on hepatic enzymes activities

The effect of treatments on serum hepatic enzymes activities is shown in Figure 5. There was a significant ($P<0.05$) increase in AST activity in the CPF group relative to either C/oil or VC group. Although there was no significant change ($P>0.05$), the AST activity in the CPF+Pb group increased by 18% relative to VC+CPF+Pb group. There was no significant ($P>0.05$) change in the AST activity in the VC+CPF+Pb group relative to those recorded in either the C/oil or VC group. There was no significant ($P>0.05$) change in the AST activity in the C/oil group relative to that of VC group.

There was a significant increase in the ALT activity in the CPF+Pb group relative to C/oil ($P<0.01$), VC ($P<0.01$) or CPF ($P<0.05$) group. There was no significant ($P>0.05$) change in the ALT activity in the VC+CPF+Pb group compared to those recorded in either the C/oil or VC group. There was no significant ($P>0.05$) change in the ALT activity in the C/oil group relative to VC group.

There was a significant ($P<0.05$) increase in ALP activity in the CPF+Pb group compared to that in the C/oil, VC or VC+CPF+Pb group. There was no significant ($P>0.05$) change in the ALP activity in the VC+CPF+Pb group relative to that of C/oil or VC group. The ALP activity in the C/oil group was not significantly ($P>0.05$) different from that recorded in the VC group.

The GGT activity in the CPF+Pb group was significantly ($P<0.01$) higher compared to C/oil, VC or VC+CPF+Pb group. The GGT activity in the VC+CPF+Pb group was not significantly ($P>0.05$) different from those recorded in either the C/oil or the VC group. The AST activity in the C/oil group was not significantly different ($P>0.05$) compared to those in the VC group.

The LDH activity in the CPF+Pb group increased significantly ($P<0.05$) compared to that obtained in the C/oil, VC or VC+CPF+Pb group. There was no significant change ($P>0.05$) in the LDH activity in the VC+CPF+Pb group compared to that recorded either C/oil or VC group. There was no significant ($P>0.05$) change in the LDH activity in the C/oil group compared to that recorded in the VC group.

Effect of treatments on hepatic lipoperoxidation

There was a significant increase in the hepatic MDA concentration in the CPF+Pb group relative to those obtained in the C/oil ($P<0.05$), VC ($P<0.01$) or VC+CPF+Pb ($P<0.05$) group. There was no significant ($P>0.05$) change in the MDA concentration in the VC+CPF+Pb group relative to that in the C/oil or VC group. The MDA concentration in the C/oil group was not significantly ($P>0.05$) different compared to that recorded in the VC group (Figure 6).

Discussion

The clinical signs recorded in the group co-administered CPF and lead reflect cholinergism apparently due to the ability of both CPF

[12,14,15,17] and lead [36-38] to inhibit AChE activity. The inhibition of AChE activity results in accumulation of acetylcholine in the cholinergic receptors in the peripheral and central nervous systems [39]. This results in initial stimulation and then subsequent paralysis of the cholinergic receptors. Anorexia recorded in the CPF+Pb group may be due to lead component of the combination [40,41]. The ability of vitamin C to reduce toxic signs associated with co-exposure to CPF and lead may be due to its ability to restore AChE activity [16,34] and complex to lead [27] thereby reducing its free form in the body. These effects and those related to its radical scavenging properties may have contributed to the reduction in toxic signs in group pretreated with vitamin C.

The marginal increase in the serum concentration of Na⁺, K⁺ and Cl⁻ in the group co-administered CPF and Pb shows that these environmental contaminants slightly alters metabolic status. Alterations in the serum electrolytes concentration had earlier been reported following co-administration of CPF and lead [30]. Pretreatment with vitamin C was able to mitigate the apparent increase in the serum concentrations of these electrolytes, indicating apparent normalization of the metabolic alterations induced by co-exposure to CPF and lead.

The study revealed that subchronic co-exposure to CPF and lead caused a decrease in serum total proteins concentration apparently due to hypoalbuminemia. The hypoalbuminemia may be due to a decrease in serum albumin synthesis as a result of hepatic impairment and/or increase urinary excretion due to impaired renal function arising from renal injury. Earlier studies have shown that CPF causes hepatic [14,18,42,43] and renal [14,25] impairments. Similarly, hepatic [29,44] and renal [45] impairments have been recorded in lead poisoning. Besides, albumin as an antioxidant [46] may have been used up in the process of combating oxidative stress evoked by both CPF and lead, thereby contributing to the low albumin concentration in the CPF+Pb group. Furthermore, the ability of albumin to directly scavenge OP and bind to it, therefore reducing the measurable free albumin available in the system may have contributed to the decline in its concentration. Earlier studies [25,47-49] have demonstrated hypoproteinemia following CPF exposure. Similarly, an apparent hypoglobulinemia was recorded in the group exposed to CPF and lead. Hypoglobulinemia recorded following CPF exposure in earlier studies [14,18] has been partly attributed to lymphocytic leukopenia [14,18,50]. Apoptotic damage to the immune cells has also been described following pesticide exposure [51]. Similarly, leucopenia has been reported in lead poisoning [52].

Pretreatment with vitamin C has been shown by the present study to mitigate hypoproteinemia, hypoalbuminemia and the relative hypoglobulinemia associated with co-exposure to CPF and lead. The mitigation of the hypoalbuminemia by vitamin C may be due to protection of the liver from oxidative damage provoked by co-exposure to CPF and lead, apparently due to its antioxidant effect. The improved globulin concentration by pretreatment with vitamin C may also be due to reduction in apoptotic damage to the WBC due to its antioxidant properties. Vitamin C has been shown to mitigate leukopenia induced by CPF poisoning [25].

The increase in serum urea concentration in the group co-administered CPF and lead is suggestive of damage to the kidneys. Ambali [25] reported that a significant increase in serum urea concentration is observed when there is damage to the kidneys. The liver is responsible for the production of urea in the body, while the kidneys excrete it. A compromised kidney will not be able to perform

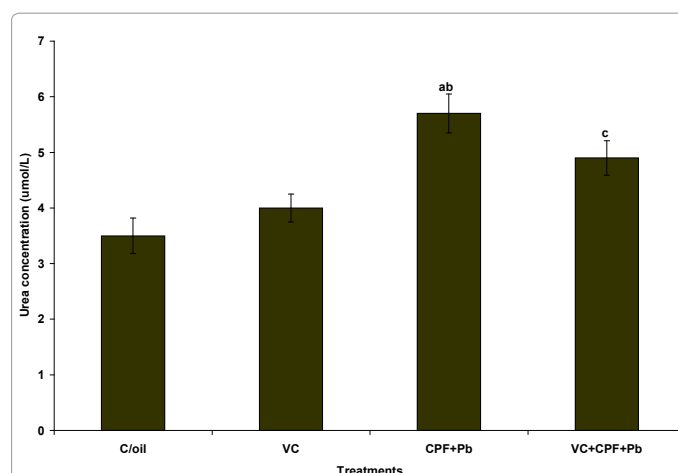


Figure 4: Effect of corn oil (C/oil), vitamin C (VC) and/or co-administration of chlorpyrifos (CPF) and lead (Pb) on serum urea concentrations in Wistar rats. ^aP<0.01 versus C/oil; ^bP<0.05 versus VC; ^cP<0.05 versus C/oil.

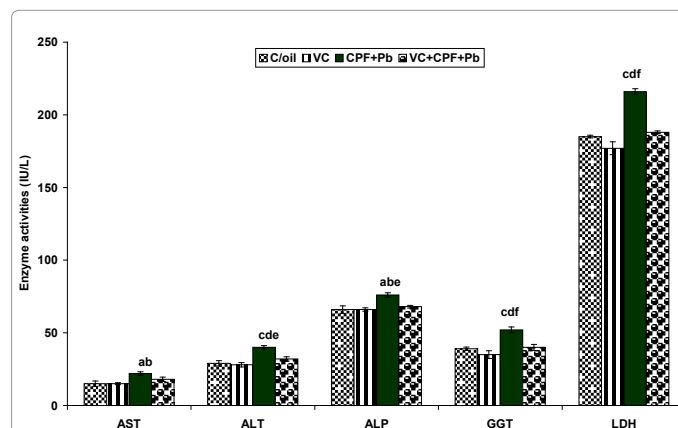
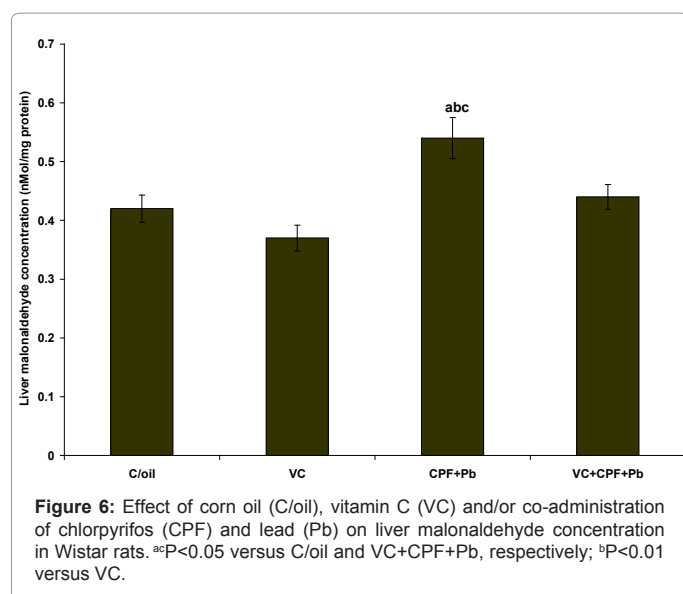


Figure 5: Effect of corn oil (C/oil), vitamin C (VC) and/or co-administration of chlorpyrifos (CPF) and lead (Pb) on some serum enzyme concentrations in Wistar rats. ^{ab}P<0.05 versus C/oil and VC groups, respectively; ^cP<0.01 versus C/oil and VC groups, respectively; ^aP<0.05 versus VC+CPF+Pb group; ^bP<0.01 versus VC+CPF+Pb group. Aspartate transferase (AST), alanine transferase (ALT), alkaline phosphatase (ALP), gamma glutamyl transferase (GGT), lactate dehydrogenase (LDH).

the urea excretion function leading to uremia. This observation agreed with those obtained by Ambali [25] following chronic CPF-intoxication in Wistar rats. Pretreatment with vitamin C resulted in a decrease in urea concentration apparently due to protection of the kidneys from oxidative damage induced by subchronic co-administration of CPF and Pb.

The result also showed that subchronic co-administration of CPF and lead caused a significant increase in the activity of serum AST, an enzyme found not only in the liver but also in the skeletal muscle and myocardial cells. The significant increase in AST activity observed in this study may indicate hepatic or muscular damage induced by co-administration of CPF and lead thereby provoking increased AST liberation into the peripheral circulation. Pre-treatment with vitamin C caused a decrease in the activity of AST suggesting amelioration of hepatic or muscular damage. This shows that vitamin C protect the organs from the damage caused by co-administration of CPF and lead. Similarly, the significant increase in serum ALT activity recorded in the group co-administered CPF and lead is an indication of hepatic damage



since the enzyme is more liver specific than AST [53]. Liver damage has been associated with CPF [14,18,25,42] and lead [44,54] poisonings. AST and ALT play essential roles in the intermediary metabolism of amino acids and in gluconeogenesis, and their concentration in liver is high relative to other tissues. ALT is found primarily in the cytosol of the hepatocytes, while AST is present in both cytosol and mitochondria [55]. In hepatic injury, there is leakage of the enzymes into the plasma thereby increasing its serum concentration [43].

Elevated ALP activity was also recorded in the group co-exposed to CPF and lead. ALP is a hydrolase enzyme for removing many types of molecules, including nucleotides, proteins and alkaloids, and therefore its activity is high in tissue involved in high level of metabolism. Increased ALP activity is not limited to liver damage only, it is also associated with pathological changes in the bone, kidneys, biles and placenta. Therefore, the high level of ALT activity may be due to damage or perturbations in any of these organs. Increased ALP activity has been associated with CPF [14,25,42,43] and lead [44] poisonings.

The study also showed a significant increase in the level of GGT in group co-administered CPF and lead. GGT is a liver-specific enzyme involved in transportation of amino acids and peptides into the cells, and it also takes part in glutathione metabolism. GGT is a good indicator of hepatobiliary disease [56] and its main use is to confirm if the elevations in ALP levels is of hepatic etiology, since the two enzymes have been termed cholestatic liver enzyme because of their increased activity in inflamed or damaged bile duct. Its activity in serum is higher when the epithelia of the bilious channels in the peripheral regions are damaged, in necrotic changes of bile channels, bile obstructions, cholangiohepatitis, cirrhosis and fatty liver [57]. The higher GGT activity recorded in the group co-administered with CPF and lead is an indication that the higher ALP activity in this group resulted significantly from lesions in the liver and bile duct.

The study also revealed a high LDH activity in the group co-administered CPF and lead. LDH catalyzes the interconversion of pyruvate and lactate with concomitant interconversion of NADH and NAD⁺ [58]. LDH converts pyruvate, the final product of glycolysis to lactate when oxygen is absent or in short supply and it performs the reverse reaction during the Cori cycle in the liver. At high concentrations of lactate, the enzyme exhibits feedback inhibition

and the rate of conversion of pyruvate to lactate is decreased. This is an important step in energy production [59]. Organs that are rich in this enzyme include the liver, heart, kidney and muscle, and death or damage to any of these organs results in its leakage into the blood stream [58]. Therefore, the high serum activity of this enzyme in the group co-administered CPF and lead may be due to damage to any of these organs. Oxidative stress, which is a mechanism involved in both CPF and lead toxicity causes multiple organ injury. Therefore, the high LDH activity may not be attributed to damage to only one organ but has been particularly linked to hepatocellular necrosis leading to leakage of the enzyme into the blood stream [8].

In summary, the increase in the activities of AST, ALT, ALP, GGT and LDH is a strong pointer to hepatotoxicity evoked by both CPF and lead. Exposure to either CPF [14,18,25,42,43] or lead [44,54] has been shown to evoke hepatic damage. The hepatotoxicity in the group co-administered CPF and lead may have arisen from increased lipoperoxidative changes as shown by high hepatic lipoperoxidation.

Pre-treatment with vitamin C has been shown in the present study to cause a decrease in the activities of AST, ALT, ALP, GGT and LDH. This shows the protective effect of vitamin C on tissue damage caused by co-exposure to CPF and lead. This may be partly due to the antioxidant role of the vitamin resulted in scavenging the reactive oxygen and nitrogen species and neutralizing their effect before they could cause damage to the organs. Studies have shown the ability of vitamin C to mitigate organ toxicity provoked by CPF [1,14,19,25,60] and lead [29,44]. The organ shown to have been mostly protected from oxidative damage induced by co-administration of CPF and lead in the present study is the liver. The ability of vitamin C to protect the liver from peroxidative changes may have contributed to the mitigation of the hepatotoxicity recorded in the group pretreated with the vitamin.

The study showed that subchronic co-administration of CPF and lead caused an increase in liver MDA concentration. MDA is a biomarker of lipid oxidative damage and is a major oxidative product of peroxidized polyunsaturated fatty acids [61,62]. An increase in MDA concentration indicates lipoperoxidative changes in the hepatocytes, hence oxidative stress. Indeed, lipoperoxidative changes have been implicated in pesticide toxicity [63]. The ability of pesticides to cause multiple organ damage may be due to its pro-oxidative effect [64]. CPF has been shown by earlier studies to induce membrane lipoperoxidation hence oxidative stress [12,14-18,42]. Similarly, lead has been shown to cause oxidative damage to tissues [8,20,21,22]. Apart from damaging lipids, oxidative stress alters the fluidity of the cell membranes and the DNA [65,66]. The consequence of oxidative damage to the cell is the alteration of the cellular integrity and functions. These may have been partly responsible for the altered biochemical parameters recorded in the CPF+Pb group in the present study.

Pre-treatment with vitamin C has been shown to significantly decrease the MDA concentration in the liver indicating its amelioration of the oxidative damage induced by co-administration of CPF and lead. Vitamin C, a potent hydrophilic antioxidant has been shown in many studies to protect the biological system from the ravaging effect of free radical induced by CPF [14,19,60]. In addition, vitamin C increases the activity of paraoxonase (PON), especially PON I [67], an esterase enzyme involved in the metabolism of OP compounds. Apart from protecting tissue against lead-evoked oxidative stress [29,44,68], vitamin C is also known to complex with lead [27], thereby mitigating the toxicity induced by the heavy metal [26,27,69,70].

In conclusion, the study has shown that subchronic co-

administration of CPF and lead causes an alteration in biochemical parameters indicating damages to some organs such as the liver and kidneys. The study equally revealed that oxidative damage to the liver may have been partly involved in the molecular mechanism associated with these biochemical alterations. Pretreatment with vitamin C for the first time has equally been shown to apparently restore the biochemical alterations caused by co-administration of CPF and lead partly due to its antioxidant effect.

References

- Ambali SF, Shuaib K, Edeh R, Oriji BC, Shittu M, Akande MG, (2011b) Hyperglycemia induced by subchronic co-administration of chlorpyrifos and lead in Wistar rats: Role of pancreatic lipoperoxidation and alleviating effect of vitamin C. *Biol Med: Article in press*
- Brouwer A, Morse DC, Lans MC, Schoor AG, Mork AJ, et al. (1998) Interactions of persistent environmental organohalogens with the thyroid hormone system: mechanisms and possible consequences for animal and human health. *Toxicol Ind Health* 14: 59-84.
- Wade GM, Warren GK, Edwards VY, McMahon A, Leingartner K, et al. (2002) Effects of subchronic exposure to a complex mixture of persistent contaminants in male rats: Systemic, immune and reproductive effects. *Toxicol Sci* 67: 131-143.
- Casida JE, Quistad GB (2004) Organophosphate toxicology: safety aspects of nonacetylcholinesterase secondary targets. *Chem Res Toxicol* 17: 983-998.
- United States Environmental Agency (US EPA) (2000) Chlorpyrifos: Re-evaluation report of the FQPA Safety Factor Committee. HED Doc. No. 014077. Washington, DC. US Environmental Protection Agency.
- Meeker JD, Singh NP, Ryan L, Duty SM, Barr DB, et al. (2004) Urinary levels of insecticide metabolites and DNA damage in human sperm. *Hum Reprod* 19: 2573-2580.
- Meeker JD, Ryan L, Barr DB, Herrick RF, Bennett DH, et al. (2004) The relationship of urinary metabolites of carbaryl/naphthalene and chlorpyrifos with human semen quality. *Environ Health Perspect* 112: 1665-1670.
- Patrick L (2006) Lead Toxicity Part II: The Role of Free Radical Damage and the Use of Antioxidants in the Pathology and Treatment of Lead Toxicity. *Altern Med Rev* 11: 114-127.
- Wang X, Zhai W, (1988) Cellular and biochemical in bronchoalveolar lavage fluids of rats exposed to fenvalerate. *Zhongguo Yaolixue Yudaixue Zoghi* 2: 271-276.
- United States Environmental Protection Agency (US EPA) (2006) Evaluation Report. Opportunities to Improve Data Quality and Children's health through Food Quality Protection Act. Office of inspector General, report no. 2006-p-0009.
- Centre for Disease Control and prevention (CDC) (1999) Illness associated occupational use of flea-control products in California, Texas and Washington, 1997-1998. *J Am Med Assoc* 282: 125-126.
- Gultekin F, Delibas N, Yasar S, Kilinc S (2001) In vivo changes in antioxidant systems and protective role of melatonin and a combination of vitamin C and vitamin E on oxidative damage in erythrocytes induced by chlorpyrifos-ethyl in rats. *Arch Toxicol* 75: 88-96.
- Dantoine T, Debord J, Merle L, Charnes JP, (2003) Roles of paraoxonase-I in OP compounds toxicity and in arteriosclerosis. *Rev Med interne* 24: 436-442.
- Ambali S, Akanbi D, Igbokwe N, Shittu M, Kawu M, et al. (2007) Evaluation of subchronic chlorpyrifos poisoning on hematological and serum biochemical changes in mice and protective effect of vitamin C. *J Toxicol Sci* 32: 111-120.
- Ambali SF, Abubakar AT, Shittu M, Yaqub LS, Anafi SB, et al. (2010) Chlorpyrifos-induced alteration of hematological parameters in Wistar rats: Ameliorative effect of Zinc. *Res J Environ Toxicol* 4: 55-66.
- Ambali SF, Idris SB, Onukak C, Shittu M, Ayo JO (2010) Ameliorative effects of vitamin C on short-term sensorimotor and cognitive changes induced by acute chlorpyrifos exposure in Wistar rats. *Toxicol Ind Health* 26: 547-558.
- Ambali SF, Ayo JO, Ojo SA, Esievo KAN, (2010) Vitamin E protects rats from chlorpyrifos-induced increased erythrocyte osmotic fragility in Wistar rats. *Food Chem Toxicol* 48: 3477-3480.
- Ambali S, Akanbi D, Shittu M, Giwa A, Oladipo OO, et al. (2010d) Chlorpyrifos-Induced Clinical, Hematological and Biochemical Changes in Swiss Albino Mice- Mitigating effect by co-administration of vitamins C and E. *Life Sci J* 7: 37-44.
- Ambali SF, Ayo JO, Ojo SA, Esievo KAN (2011) Ameliorative effect of vitamin C on chlorpyrifos-induced increased erythrocyte fragility in Wistar rats. *Hum Exp Toxicol* 30: 19-24.
- Moreira EG, Vassilief I, Vassilief, VS (2001) Developmental lead exposure: behavioral alterations in the short- and long-term. *Neurotoxicol Teratol* 23: 489-495.
- Nihei MK, McGlothlan JL, Toscano CD (2001) Low level Pb²⁺ exposure affects hippocampal protein kinase ca gene and protein expression in rats. *Neurosci Lett* 298: 212-216.
- Slawomir K, Aleksandra K, Horakb S, Ostalowskaa A, Grucka-Mamczara E, et al. (2004) Activity of SOD and catalase in people protractedly exposed to lead compounds. *Ann Agric Env Med* 11: 291-296.
- Obara H, Harasawa R (2008) L-ascorbic acid enhances apoptosis in human gastric carcinoma ncell line AZ-521 cells infected with Mycoplasma hyorhinis. *J Vet Med Sci* 70: 11-15.
- Ogutcu A, Suludere Z, Kalender Y (2008) Dichlorvos-induced hepatotoxicity in rats and the protective effects of Vitamin C and E. *Environ Toxicol Pharmacol* 26: 355-361.
- Ambali SF (2009) Ameliorative effect of vitamins C and E on neurotoxicological, hematological and biochemical changes induced by chronic chlorpyrifos in Wistar rats, PhD Dissertation, Ahmadu Bello University, Zaria.
- Goyer RA, Cherian GM (1979) Ascorbic acid and EDTA treatment of lead toxicity in rats. *Life Sci* 24:433-438.
- Flora SJS, Tandon SK (1986) Preventive and therapeutic effects of thiamine, ascorbic acid, and their combination on lead intoxication. *Acta Pharmacol Toxicol* 58: 374-378.
- Houston DK, Johnson MA, (2000) Does vitamin C intake protect against lead toxicity? *Nutr Rev* 58: 73-75.
- Oladipo OO, (2010) Ameliorative effects of ascorbic acid on neurobehavioural, haematological and biochemical changes induced by subchronic lead exposure in Wistar rats. MSc thesis, Ahmadu Bello University, Zaria, Nigeria.
- Krishna H, Ramachandran AV (2009) Biochemical alterations induced by the acute exposure to combination of chlorpyrifos and lead in Wistar rats. *Biol Med* 1: 1-6.
- Krishna H, Ramachandran AV (2009) Assessment of chlorpyrifos and lead acetate combination on neurobehavioral aspects in Wistar rats after subchronic dietary exposure. *Biol Med*, 1: 7-14.
- Guide for the care and use of laboratory animals, DHEW Publication No. (NIH) 85-23, Revised 1985, Office of Science and Health Reports, DRR/NIH, Bethesda, MD 20892.
- Draper HH, Hadley M (1990) Malondialdehyde determination as index of lipid peroxidation. *Methods Enzymol* 186: 421-431.
- Yavuz T, Delibas N, YâldârÂm B, Altuntao I, Candâr O, et al. (2004) Vascular wall damage in rats induced by methidathion and ameliorating effect of vitamins E and C. *Arch Toxicol* 78: 655-659.
- Lowry H, Rosebrough NJ, Farr AL, Randall RJ (1951) Protein measurements with the folin phenol reagent. *J Biol Chem* 193: 265-275.
- Edens FW (1985) Whole brain acetylcholinesterase activity in lead-exposed Japanese quail. *Poultry Sci* 64: 1391-1393.
- Devi M, Fingerman M (1995) Inhibition of acetylcholinesterase activity in the central nervous system of the red swamp crayfish, *procambarus clarkii*, by mercury, cadmium, and lead. *Bull Environ Contam Toxicol* 55: 746-750.
- Reddy GP, Basha R, Devi CB, Suresh A, Baker JL, et al. (2003) Lead induced effects on acetylcholinesterase activity in cerebellum and hippocampus of developing rat. *Int J Dev Neurosci* 21: 347-352.
- Eaton DL, Daroff RB, Autrup H, Buffler P, Costa LG, et al. (2008). Review of the toxicology of chlorpyrifos with an emphasis on human exposure and neurodevelopment. *Crit Rev Toxicol* 38: 1-125.
- Kennedy S, Crisler JP, Smith E, Bush M (1977) Lead poisoning in sandhill cranes. *J Am Vet Med Assoc* 171: 955-958.

41. Miller S, Bauk TJ (1992) Lead toxicosis in a group of cats. *J Vet Diagn Invest* 4: 362-363.
42. Goel A, Danni V, Dhawan DK (2005) Protective effects of zinc on lipid peroxidation, antioxidant enzymes and hepatic histoarchitecture in chlorpyrifos-induced toxicity. *Chemico-Biol Interact* 156: 131-140.
43. Mansour SA, Mossa AH (2010) Oxidative damage, biochemical and histopathological alterations in rats exposed to chlorpyrifos and the antioxidant role of zinc. *Pest Biochem Physiol* 96: 14-23.
44. Ajayi GO, Adeniyi TT, Babayemi DO (2009) Hepatoprotective and some haematological effects of *Allium sativum* and vitamin C in lead-exposed Wistar rats. *Int J Med Med Sci* 1: 064-067.
45. Bernard BP, Becker CE (1988) Environmental lead exposure and the kidney. *J Toxicol Clin Toxicol* 26: 1-34.
46. Roche M, Rondeau P, Singh NR, Tarnus E, Bourdon E (2008) The antioxidant properties of serum albumin. *FEBS Lett* 582: 1783-1787.
47. Bomhard E, Loser E, Schilde B, (1981) [E605- Methyl] (Methyl parathion) chronic toxicological studies in rats (2 year feeding trial) Wuppertal – Elberfeld Bayer AG, Institute of Toxicology IPCS -145: 155.
48. Schilde B, Bomhard E, (1984) E 605-methyl (Methyl parathion) supplementary histopathological test further to the 2-year feeding trials on rats. Addendum to report No. 9889.Wuppertal-Elberfeld, Bayer A. G., Institute of Toxicology (Unpublished Report No. 12559).
49. Szabo JR, Young JT, Granjean M, (1988) Chlorpyrifos: 13-week dietary toxicity study in Fisher 344 rats. Jackson Research Centre, Health and Environmental Sciences - Texas. Laboratory study No.: TXT: K-044793-071. Report dated December 28, 1988. Reviewed by PMRA, 1988.
50. Goel A, Danni V, Dhawan DK (2006) Role of zinc in mitigating the toxic effects of chlorpyrifos on hematological alterations and electron microscopic observations in rat blood. *BioMetals* 19: 483-492.
51. Rabideau CL (2001) Pesticide mixtures induce immunotoxicity: potentiation of apoptosis and oxidative stress. MSc Thesis, Virginia Polytechnic Institute and State University, Blacksburg, Virginia.
52. Simsek N, Karadeniz A, Kalkan Y, Keles ON, Unal B (2009) *Spirulina platensis* feeding inhibited the anemia- and leucopenia-induced lead and cadmium in rats. *J Hazard Mater* 164:1304-1309.
53. Ballantyne B, (1988) Xenobiotic-induced rhabdomyolysis. In: Ballantyne B, (Ed.). *Perspectives in Basic and Applied Toxicology*, Butterworth and Co (Publishers) Ltd. 70-153.
54. Sipos P, Szentmihályi K, Fehér E, Abaza M, Szilágyi M, et al. (2003) Some effects of lead contamination on liver and gallbladder bile. *Acta Biol Szegediensis* 47: 139-142.
55. Kohli R, Harris DC, Whittington PF (2005) Relative elevations of serum alanine and aspartate aminotransferase in muscular dystrophy. *J Ped Gastroenterol Nut* 41: 121-124.
56. Stojević Z, Filipović N, Božić P, Tuček Z, David J (2008) The metabolic profile of Simmental service bulls. *Vet Arhiv* 78: 123-129.
57. Kramer JW, Hoffmann WE (1997). *Clinical enzymology* In: Kaneko JJ, Harvey JW, Bruss ML (Eds.), *Clinical Biochemistry of Domestic Animals* (5th editn), Academic Press, London, New York, Tokyo, Pp. 303-325.
58. Rodwell V, (1993) *Enzymes; General Properties*. Harpers Biochemistry (24th Edition), Prentice-Hall Inc. p. 64.
59. Butt AA, Michaels S, Kissinger P (2002) The association of serum lactate dehydrogenase level with selected opportunistic infections and HIV progression. *Int J Infect Dis* 6: 178-181.
60. El-Hossary GG, Mansour SM, Mohamed AS (2009) Neurotoxic effects of chlorpyrifos and the possible protective role of antioxidant supplements: an experimental study. *J Appl Sci Res* 5: 1218-1222.
61. Vidyasagar J, Kamnaker N, Reddy MS, Rajnarayana ST, Krishna BR, (2004) Oxidative stress and antioxidant status in acute organophosphorous insecticide poisoning. *Indian J Pharmacol* 636: 76-79.
62. Zhang YT, Zheng QS, Pan J, Zheng RL (2004) Oxidative damage of biomolecules in mouse liver induced by morphine and protected by antioxidants. *Basic Clin Pharmacol Toxicol* 95: 53-58.
63. Abdollahi M, Ranjbar A, Shadnia S, Nikfar S, Rezaie A (2004) Pesticides and oxidative stress: a review. *Med Sci Monit* 10: RA141-RA147.
64. Kehrer P (1993) Free radicals as mediator of tissue injury and disease. *Crit Rev Toxicol* 23: 21-48.
65. Banudevi S, Krishnamoorthy G, Venkataraman P, Vignesh C, Aruldas MM, et al. (2006) Role of α-tocopherol on antioxidant status in liver, lung and kidney of PCB exposed male albino rats, *Food Chem Toxicol* 44: 2040-2046.
66. Zama D, Meraihi Z, Tebibel S, Benayssa W, Benayache FS, et al. (2007) Chlorpyrifos-induced oxidative stress and tissue damage in the liver, kidney, brain and fetus in pregnant rats: the protective role of the butanolic extract of *Paronychia argentea* L. *Indian J Pharmacol* 39: 145-150.
67. Jarvik GP, Tsai TN, McKinstry LA, Wani R, Brophy V, et al. (2002) Vitamin C and E intake is associated with increase paraoxonase activity. *Arterioscler Thromb Vasc Biol* 22: 1329 -1333.
68. Suzuki T, Yoshida A (1979) Effect of dietary supplementation of iron and ascorbic acid on lead toxicity in rats. *J Nutr* 109: 982-988.
69. Shallan MG, Mostafa MS, Hasouna MM, Hassab El-Nabi SE, et al. (2005) Amelioration of lead toxicity on rat liver with vitamin C and silymarin supplements. *Toxicology* 206: 1-15.
70. Raafat BM, Shafaa MW, Rizk RA, Elgohary AA, Saleh A (2009) Ameliorating effects of vitamin C against acute lead toxicity in albino rabbits. *Australian J Basic Appl Sci*, 3: 3597-3608.