

Progressive Nausea and Vomiting in Pregnancy: Eliminate Neurological Causes-A Case Report

Rosalie SN Linssen^{1*}, Annelies Verdonkschot², Jelle de Kruijk³ and W Peter Vandertop⁴

¹Academic Medical Center/University of Amsterdam, The Netherlands

²Department of Gynaecology and Obstetrics, Tergooi Ziekenhuizen, The Netherlands

³Department of Neurology, Tergooi Ziekenhuizen, The Netherlands

⁴Department of Neurosurgery, Academic Medical Center and VU University Medical Center, Amsterdam, The Netherlands

Abstract

Background: Severe nausea and vomiting in the first and second trimester of pregnancy is often diagnosed as hyperemesis gravidarum (HG), although true HG only appears in very few pregnancies. Anchoring, the tendency for clinicians to stick with an initial diagnosis even as new information becomes available, can lead to hesitation to perform MR-imaging in pregnant patients. As prompt diagnosis of intracranial neoplasm increases the chance on a favourable outcome, awareness among doctors is needed. Scant data on pregnant patients diagnosed with brain tumours is available; this case report pays attention to possible pitfalls for doctor's delay.

Case summary: A 36-year-old G2PO presented with severe nausea, vomiting and vertigo in the first and second trimester of pregnancy after IVF-treatment. An increase of symptoms, headaches and a lurching walking pattern were initially attributed to dehydration, orthostatic hypotension and later to a proven B12 deficiency. When symptoms worsened despite vitamin supplementation and drowsiness and bradyphrenia developed, a MR-scan of the brain showed severe obstructive hydrocephalus caused by a mass in the fourth ventricle. Surgical resection of a ganglioglioma (WHO grade I) was performed at a gestational age of 25 weeks.

Conclusion: HG typically resolves around the 20th week of gestation, therefore persistent nausea and vomiting during pregnancy warrants a cerebral MR-scan in order to exclude neurological causes.

Keywords: Hyperemesis gravidarum; Morning sickness; Pregnancy; Ganglioglioma

Introduction

Hyperemesis gravidarum (HG) is a condition characterized by severe nausea and vomiting in the first and second trimester of pregnancy, leading to dehydration with hypokalaemia and ketonuria, malnutrition, and weight loss of more than 5% of the pre-pregnancy weight [1,2]. Although 50 to 90% of women experience some form of nausea and vomiting during the first trimester, true HG only appears in 0.5-3% of all pregnancies [3]. As HG typically resolves around the 20th week of gestation, an atypical clinical course of nausea and vomiting during pregnancy warrants reconsideration of this diagnosis. We report a case of a 36-year-old woman who presented with severe nausea, vomiting, and neurological symptoms.

Case Presentation

A 36-year-old G2PO presented with severe nausea, vomiting and vertigo at a gestation of 8 +6 weeks. Conception was induced by in vitro fertilization (IVF), indicated by male subfertility. Ultrasound examination showed a vital single-foetus pregnancy, positive heart action and a crown-rump-length (CRL) of 23.4 mm. As clinical symptoms and laboratory findings showed no signs of dehydration outpatient care was continued. At a gestational age of 14 weeks, she reported an increase of nausea and vertigo, together with headaches and a lurching walking pattern. She was re-admitted under the suspicion of dehydration, physical examination showed low blood pressure (90/60 mmHg). Neurological examination was normal, besides inconsistent Romberg and slight ataxia. The headaches were attributed to her dehydration and orthostatic hypotension. As laboratory findings showed low vitamin B12 levels, a vitamin B12 deficiency was suggested as a possible explanation for the ataxia. Despite vitamin B12 supplementation her neurological symptoms worsened with word retrieval difficulties, dysarthria, drowsiness and bradyphrenia.

A MR-scan of the brain showed severe obstructive hydrocephalus caused by a fourth ventricular mass (Figure 1). At a gestational age of 23 weeks an endoscopic third ventriculocisternostomy was performed which led to rapid improvement. Surgical resection of the 4th ventricular mass was performed at a gestational age of 25 weeks, as the required prone position would become increasingly difficult

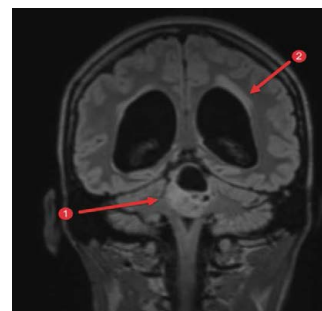

Figure 1: Preoperative T1-weighted coronal MR-image showing 1. Tumor with 4^e ventricle obstruction; 2. Enlarged lateral ventricles with transependymal CSF egress.

***Corresponding author:** Rosalie SC Linssen, Academic Medical Center/ University of Amsterdam, The Netherlands, Tel: +31 20 556 3316; E-mail: r.s.linssen@amc.uva.nl

Received December 17, 2016; **Accepted** January 23, 2017; **Published** January 28, 2017

Citation: Linssen RSC, Verdonkschot A, Kruijk J, Vandertop WP (2017) Progressive Nausea and Vomiting in Pregnancy: Eliminate Neurological Causes-A Case Report. J Clin Case Rep 7: 917. doi: [10.4172/2165-7920.1000917](https://doi.org/10.4172/2165-7920.1000917)

Copyright: © 2017 Linssen RSC, et al. This is an open-access article distributed under the terms of the Creative Commons Attribution License, which permits unrestricted use, distribution, and reproduction in any medium, provided the original author and source are credited.

with increasing gestational age. Pathology showed a WHO grade I ganglioglioma (Figure 2). After labour induction at 39+5 weeks, a healthy girl weighing 4010 grams was born. A timeline of the case is found in Table 1.

Discussion

This case illustrates three important issues: first, the important role in clinical decision-making of a doctor's 'gut feeling', a hard-to-test phenomenon, but still considered to be one of the doctor's most valuable tools [4,5]. In relation to this, a common pitfall in medicine is "anchoring": the tendency to frame a clinical problem around the first piece of information received [6]. In retrospect, the behavioural changes and disturbed walking pattern had already been observed and reported during the IVF-treatment by the fertility doctors, and might have warranted further and earlier diagnostics, as they could not be completely explained by psychological factors. Second, this case illustrates that there is no special reason to be reluctant to perform a cerebral MR-scan in pregnant patients. Due to theoretical concerns for the fetus (including teratogenesis, tissue heating, and acoustic damage) possible hesitation to perform imaging might exist, though literature has shown MR-scanning is relatively safe in pregnancy. The American College of Radiology has concluded that there are no precautions or contraindications specific to the pregnant woman, and that no special consideration is recommended for the first (versus any other) trimester in pregnancy [7]. A prompt diagnosis enables doctors to plan interventions and treatment in a timely fashion after all experts have been consulted, decreasing the risk for urgent interventions with all its subsequent risks for mother and child. Third, as HG typically resolves around the 20th week of gestation, persistent nausea and vomiting during pregnancy warrants reconsideration of this diagnosis.

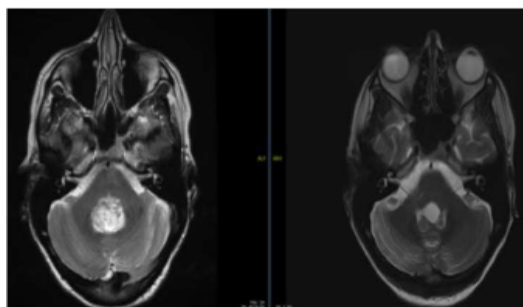


Figure 2: T2-weighted axial MR-images showing tumor in 4th ventricle (left) and after resection (right).

Pregnancy duration (weeks)	
9	First presentation; nausea and vomiting
14	Re-admission, increasing symptoms and lurching walking Consultancy Neurologist Laboratory findings: high vitamin B12
23	MRI-brain & Endoscopic ventriculocisternostomy
25	Surgical resection of the 4th ventricular mass Pathology: ganglioglioma WHO grade I
40	Labor induction and delivery

Table 1: Patient timeline.

Verheecke et al presented 27 cases of primary brain tumours or metastases diagnosed in pregnancy [8]. This case-report adds up to this information, illustrating that awareness on possible non-pregnancy-related causes of nausea and vomiting could be improved.

Conclusion

As HG typically resolves around the 20th week of gestation, persistent nausea and vomiting during pregnancy warrants a cerebral MR-scan to exclude neurological causes, preferably before onset of severe neurological symptoms. This case-report illustrates that awareness on possible non-pregnancy-related causes of nausea and vomiting could be improved and adds up to currently existing information.

References

1. Lacasse A, Rey E, Ferreira E, Morin C, Bérard A (2008) Nausea and vomiting of pregnancy: What about quality of life? BJOG An Int J Obstet Gynaecol 115: 1484-1493.
2. Holmgren C, Aagaard-Tillery KM, Silver RM, Porter TF, Varner M (2008) Hyperemesis in pregnancy: An evaluation of treatment strategies with maternal and neonatal outcomes. Am J Obstet Gynecol 198: 1-4.
3. Bailit JL (2005) Hyperemesis gravidarum: Epidemiologic findings from a large cohort. Am J Obstet Gynecol 193: 811-814.
4. Langridge N, Roberts L, Pope C (2016) The role of clinician emotion in clinical reasoning: Balancing the analytical process. Man Ther 21: 277-281.
5. Stolper CF, Van de Wiel MW, De Vet HC, Rutten AL, Van Royen P, et al. (2013) Family physicians' diagnostic gut feelings are measurable: construct validation of a questionnaire. BMC Fam Pract 14: 1.
6. Seiffer JL (2015) "Anchoring" can bias clinical judgment.
7. No Authors Listed (2016) Guidelines for diagnostic imaging during pregnancy and lactation. Committee opinion Number 656. Am Coll Obstet Gynecol 127: 1-4.
8. Verheecke M, Halaska MJ, Lok CA, Ottevanger PB, Fruscio R, et al. (2014) Primary brain tumours, meningiomas and brain metastases in pregnancy: Report on 27 cases and review of literature. Eur J Cancer 50: 1462-1471.