

## Case Report

## Open Access

# Primary Squamous Cell Carcinoma of the Ureter in a Patient with No Risk Factors

Yasser Alshomrانيا<sup>1</sup>, Anmar Nassera<sup>1</sup> and Abdulaziz Baazeema<sup>1,2\*</sup>

<sup>1</sup>Department of Surgery, Umm Al-Qura University, Makkah, Saudi Arabia

<sup>2</sup>Department of Surgery, King Faisal Specialist Hospital and Research Centre-Jeddah, Jeddah, Saudi Arabia

## Abstract

Upper urinary tract squamous cell carcinomas are uncommon tumors. Several risk factors have been identified with this entity. We present a case primary squamous cell carcinoma of the distal ureter in an individual with no identifiable risk factors. The patient is a 70 year-old man who presented with bilateral flank pain. Laboratory investigations showed high serum creatinine. There was left hydronephrosis on ultrasonography. Computed Tomography (CT) showed an ill-defined soft tissue mass in the left ureter. A left retrograde pyelogram revealed a mass 4 cm from the ureterovesical junction, with ureter dilation proximal to it. The patient underwent distal ureterectomy and stented ureteroneocystostomy. Pathological study of the tumor revealed a moderately differentiated stage 3 invasive squamous cell carcinoma. On serial follow up, the patient showed significant improvement of the left hydronephrosis and improvement of the renal function. Two-year follow-up was negative for recurrence.

**Keywords:** Ureter; Squamous cell carcinoma; Risk factors

## Introduction

Most of the tumors involving the upper urinary tract (renal pelvis and ureter) are urothelial tumors. These tumors are uncommon, representing only about 5% of urothelial tumors [1]. Squamous cell carcinomas of the upper urinary tract are even less common, constituting 1-1.6% of all urothelial tumors [2-4]. The overall survival of patients with this type of malignancy appears to be less than with transitional cell carcinoma. However, when corrected for lymph node status, patient survival appears to be comparable between the two conditions [3].

We present a case of primary squamous cell carcinoma of the ureter in a man who had no known risk factors for this disease.

## Case Report

A 70 year-old Saudi male patient, with past history of bronchial asthma, presented to the Emergency Room (ER) with a history of bilateral flank pain for 2 weeks. He also complained of anorexia, nausea and generalized weakness for 1 week. There was no history of weight loss. There were no voiding or storage symptoms. There was no hematuria. His past medical history was notable for mild bronchial asthma. He was not on any medications. On examination, his vital signs were stable. His abdomen was soft, with no organomegaly, tenderness or intra-abdominal masses.

Laboratory investigations were within normal limits apart from a high serum creatinine that reached up to 706 umol/L (reference range: 50-110 umol/L) and a low serum calcium level of 1.3 mmol/L (reference range: 2.1-2.7 mmol/L) preoperatively. Urinalysis revealed microscopic hematuria. On ultrasonography (US) of the abdomen and pelvis, the left kidney measured 11.6 × 6.3 × 5.3 cm with mild hydronephrosis. The right kidney was atrophic, and appeared to be nonfunctional. No renal stones or masses were detected. There were no stones or masses in the bladder. Computed Tomography (CT) without contrast of the abdomen and pelvis revealed no stones. However, there was (Figure 1). No contrast was administered because of the patient's poor renal function.

Cystoscopy was unremarkable. A urine cytology specimen was obtained and later came back negative for malignancy. A left retrograde pyelogram confirmed the presence of a filling defect 4 cm from the ureterovesical junction, creating an apple core appearance.

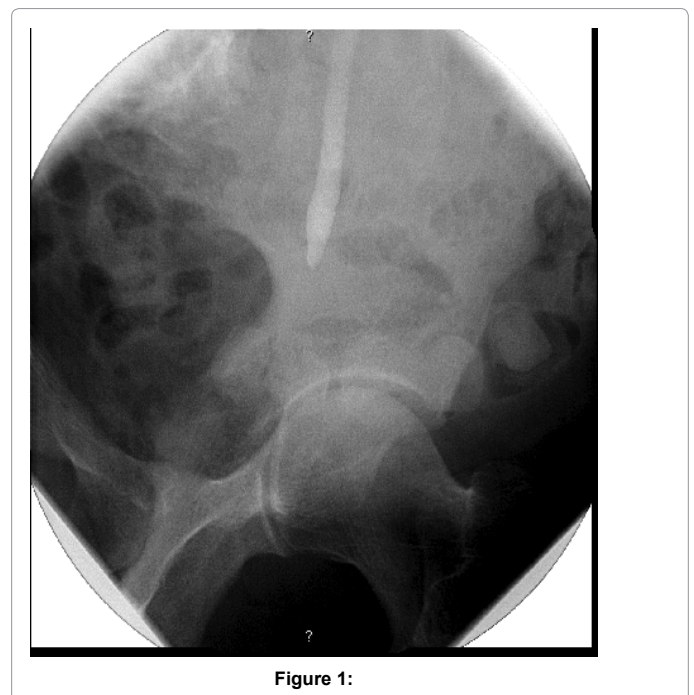


Figure 1:

The ureter was significantly dilated proximal to it. The guide wire can not negotiate beside the mass. A left nephrostomy tube was inserted. A nephrostogram showed no contrast reaching the bladder (Figure 2). The patient's serum creatinine appropriately decreased to 123 umol/L. The

**\*Corresponding author:** Abdulaziz baazeem, Department of Surgery, king faisal specialist hospital and research centre jeddah, Jeddah, Saudi Arabia, E-mail: [theurologist@gmail.com](mailto:theurologist@gmail.com)

**Received** December 01, 2014; **Accepted** February 26, 2015; **Published** February 28, 2015

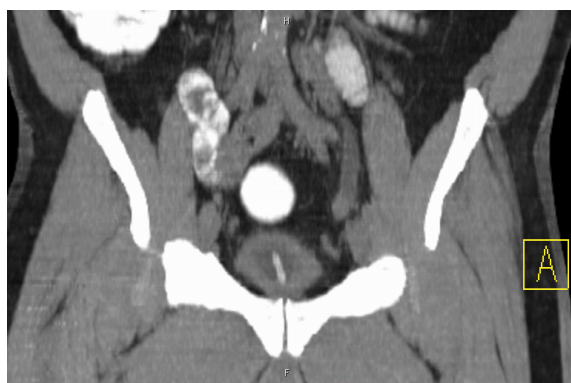**Citation:** Alshomrانيا Y, Nassera A, Baazeema A (2015) Primary Squamous Cell Carcinoma of the Ureter in a Patient with No Risk Factors. J Clin Case Rep 5: 496. doi: [10.4172/2165-7920.1000496](https://doi.org/10.4172/2165-7920.1000496)

**Copyright:** © 2015 Alshomrانيا Y, et al. This is an open-access article distributed under the terms of the Creative Commons Attribution License, which permits unrestricted use, distribution, and reproduction in any medium, provided the original author and source are credited.

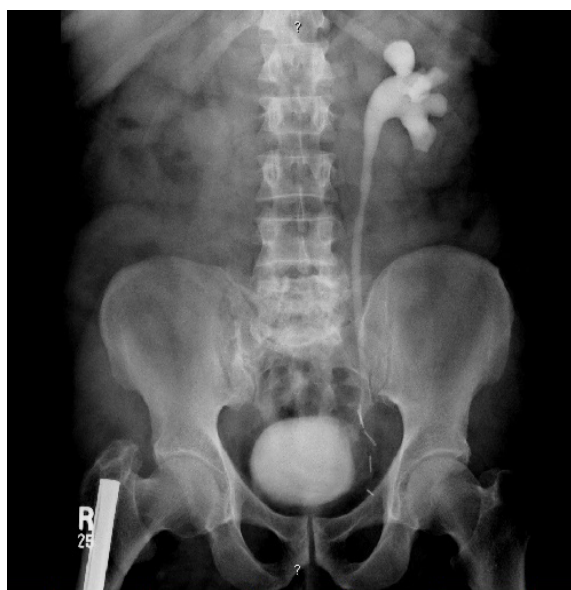patient was re-evaluated using MRI and an antegrade nephrostogram to better delineate the tumor at the lower third of the ureter. No evidence of lymphadenopathy was detected. A distal ureterectomy and stented, refluxing ureteroneocystostomy was performed. A psoas hitch was not required. Frozen section from the proximal tip was free of disease. The post-operative course was uneventful. The nephrostomy tube was removed at 2 weeks post-operatively and the closed suction drain was removed the next day. A week later, the urethral catheter was removed. The double-J stent was removed cystoscopically 4 weeks afterward.

Pathological study of the tumor revealed a moderately differentiated invasive squamous cell carcinoma invading through the ureteric wall into the periureteric fat with vascular and perineuronal invasion (pathological stage T3). Some chronic inflammatory reaction was noticed with no evidence of schistosomiasis.

The patient was on serial follow up with abdominopelvic US, Intravenous Pyelogram (IVP) and renal radionuclide studies, which revealed significant improvement of the left hydronephrosis and improvement of the renal function. (Figure 3) CT abdomen and pelvis with contrast after two years post-operatively revealed no evidence of recurrence.



**Figure 2:**



**Figure 3:**

## Discussion

The mucosa of the ureter is usually lined with transitional epithelium and is normally devoid of squamous epithelium [5]. Squamous malignant changes are usually preceded by squamous metaplasia, which usually occurs in association with chronic inflammation of the epithelium of the urinary tract [5,6]. Indeed, the current patient had elements of chronic inflammation on histological assessment.

There are several risk factors that have been suggested to play a role in the development of squamous cell carcinoma of the ureter such as chronic irritation, urinary tract infection, urolithiasis, chronic hydronephrosis, misuse of analgesics (especially phenacetin), external beam irradiation and horseshoe kidneys [5-8]. In a series of four cases of squamous cell carcinoma involving the upper urinary tract, all cases had staghorn stones (75% bilateral) and 50% underwent prior surgery for stones [5]. None of the above-mentioned risk factors could be identified in this patient. This is peculiar, as these tumors usually occur in the setting of squamous metaplasia which is usually brought on by some form of chronic irritation [6].

When symptomatic, patients with upper tract squamous cell carcinoma usually present with loin pain, hematuria or abdominal masses [5]. This type of tumor is highly infiltrative and may be associated with early local and vascular invasion [9]. Treatment of squamous cell carcinoma of the distal ureter is usually by distal ureterectomy and ureteroneocystostomy [10,11]. This approach appears to ensure better postoperative renal function [12]. Certainly this was the most appropriate for the current patient, as the affected side contained his only functioning kidney. At least with transitional cell carcinoma of the ureter, distal ureterectomy appears to offer comparable results to nephroureterectomy in terms of cancer specific survival [13].

## References

- Melamed MR, Reuter VE (1993) Pathology and staging of urothelial tumors of the kidney and ureter. *Urol Clin North Am* 20: 333-347.
- Toktas G, Ergun C, Mansuroglu B, Unluer E (1997) Primary squamous cell carcinoma of the ureter presenting with urinoma. A case report. *Int Urol Nephrol* 29: 163-165.
- Berz D, Rizack T, Weitzen S, Mega A, Renzulli J, et al. (2012) Survival of patients with squamous cell malignancies of the upper urinary tract. *Clin Med Insights Oncol* 6: 11-18.
- Rausch S, Hofmann R, von Knobloch R (2012) Nonbilharzial squamous cell carcinoma and transitional cell carcinoma with squamous differentiation of the lower and upper urinary tract. *Urol Ann* 4: 14-18.
- Raheema OA, Elmusharafa E, Caseya RG, McDermotta T (2012) A Locally Advanced Squamous Cell Carcinoma of the Ureter. *World J Nephrol Urol* 1:118-124.
- Khan MA, Kar A, Walker MM, Lloyd J, Vale JA, et al. (2012) A Case of Squamous Cell Carcinoma of the Renal Pelvis in association with Schistosoma hematobium. *Case Rep Oncol Med* 2012: 352401.
- Jain A, Mittal D, Jindal A, Solanki R, Khatri S, et al. (2011) Incidentally detected squamous cell carcinoma of renal pelvis in patients with staghorn calculi: case series with review of the literature. *ISRN Oncol* 2011: 620574.
- Bandyopadhyay R, Biswas S, Nag D, Ghosh AK (2010) Squamous cell carcinoma of the renal pelvis presenting as hydronephrosis. *J Cancer Res Ther* 6: 537-539.
- Vargas AAM, Sola P, Gómez E, Teruel J, Velayos A (1994) Squamous cell carcinoma of the renal pelvis presenting as duodenal obstruction. *European Radiology* 4: 384-386.
- Bloom NA, Vidone RA, Lytton B (1970) Primary carcinoma of the ureter: a report of 102 new cases. *J Urol* 103: 590-598.
- Messing EM CW. Urothelial tumors of the urinary tract. In: Walsh PC, (ed.) *Campbell's Urology* (7thedn.) Philadelphia: Saunders, 1998.

- 
12. Silberstein JL, Power NE, Savage C, Tarin TV, Favaretto RL, et al. (2012) Renal function and oncologic outcomes of parenchymal sparing ureteral resection versus radical nephroureterectomy for upper tract urothelial carcinoma. J Urol 187: 429-434.
  13. Jeldres C, Lughezzani G, Sun M, Isbarn H, Shariat SF, et al. (2010) Segmental ureterectomy can safely be performed in patients with transitional cell carcinoma of the ureter. J Urol 183: 1324-1329.