

Case Report

Open Access

Primary Intramedullary Melanocytoma: A Case Report

Gokmen Kahilogullari*

Ankara Universitesi Ibnî Sina Hastanesi Norosirurji ABD Sıhhiye/ANKARA, Turkey

Abstract

We report herein a case of primary intramedullary melanocytoma in a 28-year-old female. She presented with a 3-year history of back pain with paresthesia and dysesthesia of the right lower extremity. Magnetic resonance imaging showed an intramedullary mass located at the T11-12 level. The tumor was removed totally. The histopathological diagnosis was melanocytoma. Intramedullary melanocytomas are rare lesions, and this is only the 20th case described in the literature. Though known as benign tumors, local recurrence and the aggressive behavior of melanocytomas must be kept in mind, even following total resection.

Keywords: Melanocytoma; Intramedullary; Spinal

Introduction

Spinal melanocytomas are rare lesions. Localization of these tumors is usually extramedullary, but intramedullary localization can be seen rarely. To our knowledge, only 19 cases of intramedullary

melanocytomas have been reported in the literature to date [1-13]. Melanocytomas are associated with leptomeninges [7,14,15]. Despite their benign nature, the behavior of these tumors can be aggressive because of the high recurrence incidence [13,14]. Herein, we review the literature and report the 20th intramedullary melanocytoma case.

Case Report

A 28 year old female presented with a 3 year history of back pain and paresthesia and dysesthesia of the right lower extremity. These symptoms had been reported to be exacerbated with pregnancy. Her neurological examination was intact. Magnetic Resonance Imaging (MRI) showed an intramedullary mass located at the T11-12 level (Figures 1, 2). Following her preparation for surgery, she underwent T11-12 total laminectomy, and total resection of the intramedullary mass was done with microsurgical technique. The postoperative period was uneventful. The histopathological findings were consistent with melanocytoma (Figure 3).

Discussion

Melanocytomas are rare benign tumors arising from leptomeningeal melanocytes in the central neuraxis. Approximately half of the cases are in the spinal canal, especially intradural and extramedullary. They are usually localized at the lumbar and thoracic levels and sometimes at the cervical level [1-13].

The gross appearance of melanocytoma is as a circumscribed, solitary, black or dark brown pigmented lesion, as seen in our case [4,6]. Although known as benign, the tumors can be aggressive, and malignant transformation has been reported [14]. Distinction between meningeal melanocytoma and malignant meningeal melanoma is not easy. Immunohistochemical staining may be helpful for distinguishing meningeal melanocytomas from pigmented meningiomas and schwannomas [4]. Goncalves et al. [3] described a case of spinal meningeal melanocytoma mimicking neurinoma. The potential for intracranial metastases of intramedullary tumors as described in the literature has not been shown yet for intramedullary melanocytomas [16,17].

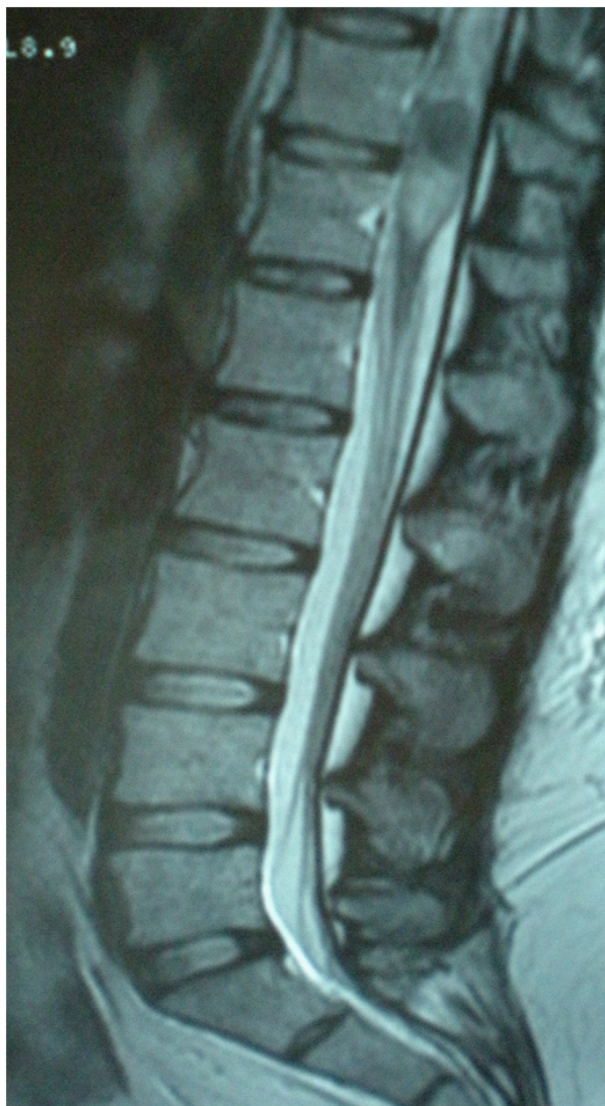

Figure 1: Preoperative magnetic resonance imaging (MRI), T1-weighted sagittal images showing an iso-hypointense lesion at level T11-12.

*Corresponding author: Gokmen Kahilogullari, Ankara Universitesi Ibnî Sina Hastanesi Norosirurji ABD Sıhhiye/ANKARA, Turkey, E-mail: gokmenkahil@hotmail.com

Received March 13, 2012; Accepted April 06, 2012; Published April 18, 2012

Citation: Kahilogullari G (2012) Primary Intramedullary Melanocytoma: A Case Report. J Clin Case Reports 2:123. doi:10.4172/2165-7920.1000123

Copyright: © 2012 Kahilogullari G. This is an open-access article distributed under the terms of the Creative Commons Attribution License, which permits unrestricted use, distribution, and reproduction in any medium, provided the original author and source are credited.

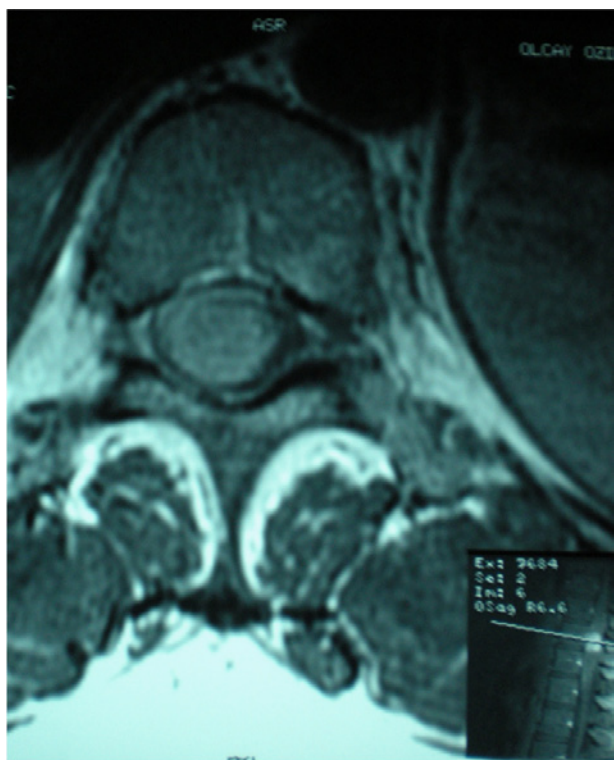


Figure 2: Preoperative MRI, T2-weighted axial images showing an iso-hyperintense lesion at the same level.

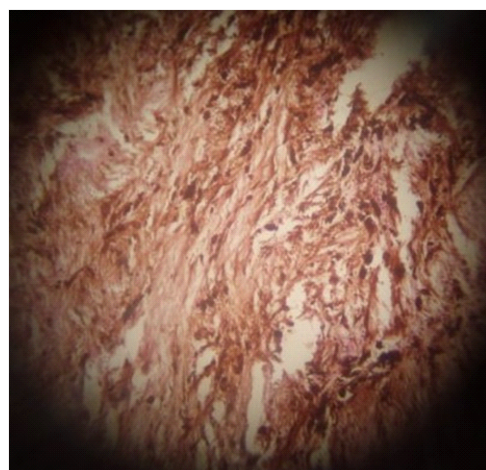


Figure 3: In the histopathological examination, consisting grossly of coal-black tissue, this tumor was seen to be composed of uniform spindle cells arrayed in fascicles. Cytoplasmic melanizations were advanced, particularly at the periphery, and obscured all cytologic detail. Tumor cell nuclei of small diameter can be seen at the less melanocytic areas.

The primary treatment for melanocytoma is surgery. The results of surgery and a review of the literature for intramedullary spinal cord melanocytomas were well documented by Horn et al. [10]. The goal of surgery is total resection, but local recurrence following total resection was reported [10,14]. In subtotal resected cases, postoperative radiotherapy is advised [15].

Conclusion

While intramedullary melanocytomas are extremely rare benign

tumors, local recurrence and the aggressive behavior of this tumor despite total resection must be kept in mind.

References

- Barth A, Pizzolato GP, Berney J (1993) Intramedullary meningeal melanocytoma. *Neurochirurgie* 39: 188-194.
- Glick R, Baker C, Husain S, Hays A, Hibshoosh H (1997) Primary melanocytomas of the spinal cord: a report of seven cases. *Clin Neuropathol* 16: 127-132.
- Goncalves J, Diaz P, Subhi-Isia I, Maillo A, Blanco A (2002) Spinal meningeal melanocytoma simulating neurinoma: case report. *Neurochirurgia (Astur)* 13: 393-396.
- Iida M, Llena JF, Suarez MA, Malik S, Weidenheim KM, et al. (2002) Two cases of spinal meningeal melanocytoma. *Brain Tumor Pathol* 19: 41-45.
- Shownkeen HN, Harmath C, Thomas C (2002) Multiform cervical melanocytoma: a case report. *Neuroradiology* 44: 1008-1010.
- Chen KT (2003) Crush cytology of melanocytoma of the spinal cord. A case report. *Acta Cytol* 47: 1091-1094.
- Turhan T, Oner K, Yurtseven T, Akalin T, Ovul I (2004) Spinal meningeal melanocytoma. Report of two cases and review of the literature. *J Neurosurg* 100 (3 Suppl Spine): 287-290.
- Karikari IO, Powers CJ, Bagley CA, Cummings TJ, Radhakrishnan S, et al. (2009) Primary intramedullary melanocytoma of the spinal cord: case report. *Neurosurgery* 64: E777-E778.
- Shanthi V, Ramakrishna BA, Bheemaraju VV, Rao NM, Athota VRM (2010) Spinal meningeal melanocytoma: a rare meningeal tumour. *Ann Indian Acad Neurol* 13: 308-310.
- Horn EM, Nakaji P, Coons SW, Dickman CA (2008) Surgical treatment for intramedullary spinal cord melanocytomas. *J Neurosurg Spine* 9: 48-54.
- Eskandari R, Schmidt MH (2010) Intramedullary spinal melanocytoma. *Rare Tumors* 2: e24.
- Brat DJ, Giannini C, Scheithauer BW, Burger PC (1999) Primary melanocytic neoplasms of the central nervous systems. *Am J Surg Pathol* 23: 745-754.
- Perrini P, Caniglia M, Pieroni M, Castagna M, Parenti GF (2010) Malignant transformation of intramedullary melanocytoma: case report. *Neurosurgery* 67: E867-E869.
- Wang F, Li X, Chen L, Pu X (2007) Malignant transformation of spinal meningeal melanocytoma. Case report and review of the literature. *J Neurosurg Spine* 6: 451-454.
- Rades D, Schild SE (2006) Dose-response relationship for fractionated irradiation in the treatment of spinal meningeal melanocytomas: a review of the literature. *J Neurooncol* 77: 311-314.
- Jang SY, Kong MH, Song KY, Frazee JG (2009) Intracranial metastases of cervical intramedullary low-grade astrocytoma without malignant transformation in adult. *J Korean Neurosurg Soc* 45: 381-385.
- Jeong SM, Chung YG, Lee JB, Shin Y (2010) Intracranial dissemination from spinal cord anaplastic astrocytoma. *J Korean Neurosurg Soc* 47: 68-70.