

## Polyposis of Terminal Ileum as an Uncommon Cause of Gastrointestinal Bleeding

Stefan Kmezic\*, Andrija Antic and Ilija Pejovic

First Surgical Clinic, Clinical Center of Serbia, Serbia

### Abstract

Gastrointestinal bleeding is not always easy to detect. Bleeding can come from any part of digestive tract, from mouth to the rectum. It can be from small amount that is only detectable by laboratory testing, to massive bleeding that can cause hemorrhagic shock. Benign small-bowel tumors may develop as a single lesion or as multiple lesions of several sub-types.

**Keywords:** Gastrointestinal; Bleeding; Anaemia; Small bowel tumors

### Background

Gastrointestinal bleeding is not always easy to detect. Bleeding can come from any part of digestive tract, from mouth to the rectum. It can be from small amount that is only detectable by laboratory testing, to massive bleeding that can cause hemorrhagic shock. Benign small-bowel tumors may develop as a single lesion or as multiple lesions of several sub-types. Polyps or tumors of any type can be a source of small bowel bleeding in about 6.5% cases [1].

### Case Report

A 39-years old male Caucasian came to our Clinic after diagnostic evaluation performed by haematologist due to anaemia and general weakness. Patient is without any co-morbidity. Since the symptoms were persistent (hemoglobin 67 g/l) and general condition of patient worsens the intensive conservative treatment started with blood transfusions. Urgent esophagogastroduodenoscopy was performed and no ulcer, neoplasm or sign of bleeding were noticed. Colonoscopy and MDCT of abdomen were also performed with no clinically relevant findings. Since the colon was elongated and cecum hasn't been visualized during colonoscopy we did CT colonography in addition. On CT colonography 2cm wide polypoid tumor of ileocecal valve was described. After this finding patient undergone surgical treatment and right hemicolectomy was performed. In specimen, in terminal ileum, there were multiple polyps that were also noticed on Bauchini valve. Pathohistological diagnosis was: Polyposis lymphoid ilea et coeco-ascendentis. After surgical treatment patient Bohemian was corrected and his overall condition got better (Figures 1-3).

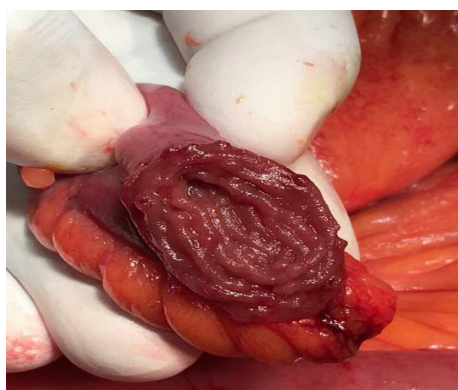


Figure 1: Bowel bleeding.

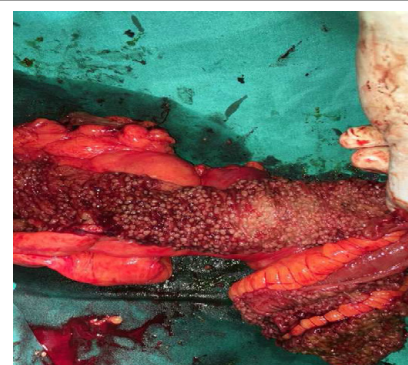


Figure 2: 2 cm wide polypoid tumor of ileocecal valve.

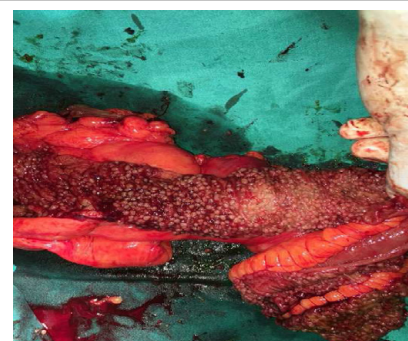

Figure 3: Polyposis lymphoid ileum and coeco-ascendentis.

### Discussion

Small bowel diagnostics should be carried out if the etiology of an anaemia is not certain [2]. As mentioned before tumors of small bowel can be a source bleeding in about 6.5% cases. This tumors often

\*Corresponding author: Stefan Kmezic, First Surgical Clinic, Clinical Center of Serbia, Serbia, Tel: +38110311212; E-mail: [kstefan1986@gmail.com](mailto:kstefan1986@gmail.com)

Received May 10, 2016; Accepted November 22, 2016; Published November 26, 2016

Citation: Kmezic S, Antic A, Pejovic I (2016) Polyposis of Terminal Ileum as an Uncommon Cause of Gastrointestinal Bleeding. J Clin Case Rep 6: 892. doi: [10.4172/2165-7920.1000892](https://doi.org/10.4172/2165-7920.1000892)

Copyright: © 2016 Kmezic S, et al. This is an open-access article distributed under the terms of the Creative Commons Attribution License, which permits unrestricted use, distribution, and reproduction in any medium, provided the original author and source are credited.

goes undiagnosed because of inaccessibility of small intestine during endoscopic procedures [3]. Video capsule endoscopy should be considered as a first choice in small bowel examination.

## References

1. Toydemir T (2010) Inflammatory fibroid polyp of the ileum presenting with small bowel obstruction in an adult patient: A Case Report. J Med Case Reports 4: 298.
2. Mukhopadhy S, Harbol T, Floyd FD (2004) Polypoid nodular lymphoid hyperplasia of the terminal ileum. Arch Pathol Lab Med 128: 23-25.
3. Williams GR, Jaffe S, Scott CA (1992) Inflammatory fibroid polyp of the terminal ileum presenting in a patient with active Crohn's disease. Histopathology 20: 465-472.