

POEMS Syndrome: A Multidisciplinary Diagnostic Challenge

Leonardo Enciso¹, Jorge Aponte^{2*}, Daniel Rodriguez², Carmenza Sandoval³ and Hernán Gomez⁴

¹Samaritan University Hospital, National Cancer Institute of Colombia, National University of Colombia, Innovation and Research Program in Acute and Chronic Leukemia (PILAC), Bogotá, Colombia

²Internal Medicine Department, Sabana University, Bogotá, Colombia

³Internal Medicine Department, National University, Bogotá, Colombia

⁴Internal Medicine Department, Cartagena University, Bogotá, Colombia

Abstract

POEMS syndrome is a paraneoplastic phenomenon associated with polyneuropathy and paraproteinemia that arises out of the clonal expansion of plasma tumor cells. Its other distinguishing features include sclerotic bone lesions, increased vascular endothelial growth factor levels, Castleman disease alterations in lymph node biopsy and association with organomegaly, endocrinopathy, cutaneous lesions, papilledema, extravascular volume overload and thrombocytosis. Although established diagnostic criteria exist, the fact that the disease is rare and shares similar clinical manifestations with non-neoplastic conditions means that in most cases patients are diagnosed at late-stage, when multiple complications have appeared and treatments for other conditions have already been given. Therefore, a high degree of suspicion combined with a multidisciplinary approach are requisites for attaining precise diagnosis and providing timely treatment. Due to the wide differential diagnosis that the syndrome's clinical features encompass as well as its subsequent favourable responses to bone marrow transplant and diverse chemotherapy treatments, clinicians from diverse fields should include the POEMS syndrome within polyneuropathy differential diagnoses that require specific diagnostic tests. Herein, we present our case study in which we emphasize diagnosis and treatment of patients treated at our institution.

Keywords: POEMS syndrome; Vascular Endothelial Growth Factor (VEGF); Peripheral neuropathy

Introduction

POEMS syndrome is a paraneoplastic phenomenon associated with polyneuropathy and paraproteinemia that arises out of the clonal expansion of plasma tumour cells. Its definitive diagnosis requires the presence of polyneuropathy and proof of clonal plasma cell proliferation that produces a monoclonal paraprotein, usually of the lambda type. POEMS syndrome is a rare entity, with an estimated prevalence of 0.3 cases per 100,000 inhabitants per year; the acronym, created by Barwick in 1980, refers to several of the syndrome's distinctive features (polyneuropathy, organomegaly, endocrinopathy, measurable monoclonal component and cutaneous alterations); additionally, patients exhibit other manifestations such as: Papilledema (usually bilateral) [1]; extravascular volume overload revealed by edemas, pleural and pericardial effusion and ascites; sclerotic bone lesions and hematological alterations such as thrombocytosis or erythrocytosis [2].

Although the disease's physiopathology is not completely understood, the persistent appearance in POEMS syndrome patients of elevated Vascular Endothelial Growth Factor (VEGF) levels, and of other cytokines, and their reduction among those who respond to treatment, has focused attention on the specific effects of VEGF levels as the source of clinical manifestations and of laboratory findings. VEGF appears to play an essential role in the genesis of microangiopathy, edema, increased capillary permeability, neovascularization, polyneuropathy, pulmonary hypertension, leukocytosis and thrombocytosis. Additionally, high levels of IL, 1 β , IL6, TNF-alpha, and reduced levels of erythropoietin have been found [3].

A requisite for POEMS syndrome diagnosis is the presence of peripheral neuropathy, which in most cases is of the demyelinating type, whereas motor compromise is usually preceded by sensitive alterations.

Although initial clinical manifestations may be indistinguishable from those found in patients with Chronic Inflammatory Demyelinating Polyneuropathy (CIDP), other researchers have found features that may be distinctive in electrodiagnostic studies [4]. However, the presence of

paraproteinemia should be ruled out in CIDP-suspect patients who do not respond to conventional treatment [5].

Case Reports

Case 1

A 42-year-old male, whose evolving clinical picture at 3 years had begun with dysesthesia and paresthesia in hands and feet, who had initially been diagnosed with Chronic Inflammatory Demyelinating Polyneuropathy (CIDP) and had consequently received 5 intravenous gamma globulin, systemic steroid and azathioprine treatment cycles, which produced no response, and which gradually led to prostration. His clinical picture further included progressive weight loss, and at one month prior to admission, symptoms interpreted as right-sided cardiac failure caused by ascites, lower limb edema and gradual functional deterioration that reached NYHA Class IV/IV. In evaluating vital systems, it was also discovered that 6 months prior to patient's admission, his vocal tone had changed and his skin pigmentation and width had increased. No other relevant antecedents, except polyneuropathy, were apparent.

Patient's physical examination revealed tachycardia, with level II jugular vein engorgement, unfolding and reinforcement of the second noise in pulmonary focus, ascites, lower limb edema, bilateral papilledema, severe interosseous muscle atrophy with glove and long boot hypoesthesia, proximal upper limb muscular strength at 4/5, distal

***Corresponding author:** Jorge Enrique Aponte Monsalve, Internal Medicine Department, Sabana University, Bogotá, Colombia, Tel: +57 1 3165000; E-mail: jorapon3777@hotmail.com

Received May 31, 2017; **Accepted** June 12, 2017; **Published** June 16, 2017

Citation: Enciso L, Aponte J, Rodriguez D, Sandoval C, Gomez H (2017) POEMS Syndrome: A Multidisciplinary Diagnostic Challenge. J Clin Case Rep 7: 979. doi: [10.4172/2165-7920.1000979](https://doi.org/10.4172/2165-7920.1000979)

Copyright: © 2017 Enciso L, et al. This is an open-access article distributed under the terms of the Creative Commons Attribution License, which permits unrestricted use, distribution, and reproduction in any medium, provided the original author and source are credited.

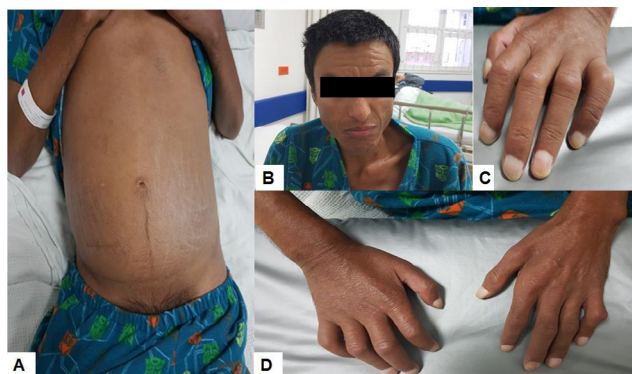

Figure 1: A. Ascites. B. Hyperpigmentation. C. Nail clubbing and leukonychia. D. Hyperkeratosis and sclerodermiform alterations.

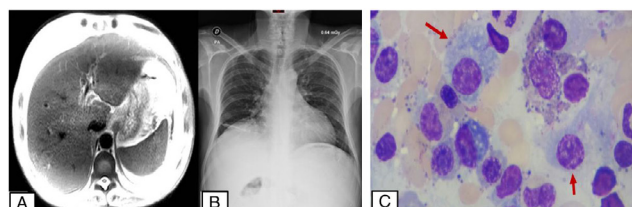


Figure 2: A. MRI abdomen scan with abundant ascites liquid, enlarged liver (18 cm and 19 cm). Spleen enlargement (14 cm), without focal lesions. B. Right basal fibrous thoracic tract, left ventricle growth. C. Bone marrow aspiration with 11.3% large atypical plasmacytes (arrows), eccentric nucleus, irregular cytoplasm, vacuole, basophil.

dorsiflexion at 1/5 and plantar flexion at 3/5; in lower limbs, both distal and proximal were at 5/5; general muscle tendon reflexes at +/++++. Limb examination revealed nail clubbing, leukonychia, acrocyanosis, areas of hyperpigmentation, hyperkeratosis and sclerodermiform alterations on skin of hands (Figure 1).

Clinical picture was initially interpreted as decompensated heart failure. Imaging studies (Figure 2) showed hepatosplenomegaly, ascites and bilateral pleural diffusion; radiologic findings revealed pulmonary hypertension, later confirmed by echocardiography. Laboratory exam results appear in (Table 1). Treatment began with diuretics and evacuatory paracentesis, which revealed a transudative fluid with a non-suggestive albumin gradient of portal hypertension; subsequently, patient's condition did not improve.

In our institutional patient evaluation, we encountered hypogonadism, polyneuropathy, organomegaly, papilledema, skin alterations and extravascular volume overload; all of which created suspicion of POEMS syndrome. Diagnostic verification studies confirmed presence of monoclonal IgA lambda type paraproteinemia and extremely elevated VEGF levels. Bone marrow (Figure 2) presented an abnormal plasma cell population whose total made up 11.3% of the cells. POEMS syndrome diagnosis was made under fulfillment of two mandatory criteria (chronic inflammatory demyelinating polyneuropathy confirmed by electromyography and monoclonal gammopathy with increase in plasmacytes in bone marrow), added to major supporting diagnostic criteria provided by elevated VEGF serum levels and minor criteria supported by the presence of endocrinopathy (hypogonadism), organomegaly (hepatosplenomegaly), skin alterations, nail clubbing, leukonychia and hyperpigmentation, extravascular

Laboratory study		Case 1	Case 2	Case 3
Hemogram	leukocytes 4.8-10 ³ UI	9700 UI	4.050 UI	7300 uL
	Hemoglobin 14-18 g/dL	12.4 g/dL	10.2 g/dL	14 g/dL
	Hematocrit 45-54%	39%	29.80%	41%
	Platelets 150-450 µL	250000 µL	364000 µL	314000 µL
Kidney function	Creatinine 0.6-1.24 mg/dL	1.67 mg/dL	0.9 mg/dL	1 mg/dL
	BUN 6.20 mg/dL	47.7 mg/dL	18.3 mg/dL	14 mg/dL
Transaminases	SGOT 15-41 µ/L	18.73 µ/L	4.4 µ/L	N/A
	SGPT 17-63 µ/L	10.41 µ/L	6 µ/L	N/A
	Total 0.3-1.2	0.59 mg/dL	0.17 mg/dL	N/A
	Direct 0.1-0.5	0.06 mg/dL	0.13 mg/dL	N/A
Lactate dehydrogenase	105-300 µ/l	130 µ/L	120.6 µ/L	91 µ/L
Electrolytes	Potassium 3.5-5.1 mEq/L	7.31 mEq/L	3.53 mEq/L	4.2 mEq/L
	Calcium 8.5-10.2 mg/dL	8.04 mg/dL	8 mg/dL	8.9 mg/dL
	Sodium 135-145 mEq/L	137 mEq/L	142 mEq/L	139 mEq/L
Total proteins	6.1-7.9 g/dL	6.72 g/dL	8.6 g/dL	7.65 g/dL
Albumin	3.5-4.8 g/dL	3.15 g/dL	3 g/dL	3.5 g/dL
Protein electrophoresis and immunofixation		Monoclonal type IgA-lambda gammopathy	Monoclonal type IgA-lambda gammopathy	Monoclonal type IgA-lambda gammopathy
VEGF levels		>1000 pg/mL	1100 pg/mL	580 pg/mL
Hormone tests	TSH 0.4-10	4.41 uIU/mL	6.617 uIU/mL	14.34 uIU/mL
	FSH 1.7-19	8.17 uIU/mL	9.5 mIU/mL	N/A
	LH 1.2-8.6	5.88 mIU/mL	5 mIU/mL	N/A
	Prolactin*	12.77 ng/mL	48.84 ng/mL	N/A
	Testosterone	0.84 ng/mL	N/A	N/A
	Cortisol AM	5.86 µg/dL	12.5 µg/dL	8.8 µg/dL
	Cortisol PM	7.69 µg/dL	6.2 µg/dL	N/A
	ACTH	68.4 mcg/dL	2.6 mcg/dL	74.1 mcg/dL
Electromyography		Peripheral, motor sensitive, demyelinating polyneuropathy	Peripheral, motor sensitive, demyelinating polyneuropathy	Peripheral myelinated axon polyneuropathy

Bone series	Normal	Normal	Normal
Transthoracic echocardiogram	LVEF 55%	LVEF 65%	LVEF 60%
	PASP 70 mmHg	PASP 58 mmHg	PASP 45mm Hg

*Prolactin reference values: Men: 2.64-13.3 ng/mL; Women: Pre-menopause: 3.34-26.7 ng/mL; Women: Post-menopause: 2.74-19.6 ng/mL/A: Not available

Table 1: Laboratory exam results.

volume overload (ascites, edema), papilledema in absence of endocranial hypertension, pulmonary hypertension and weight loss. Treatment began with high doses of dexamethasone, followed by oral cyclophosphamide and dexamethasone chemotherapy (cyclophosphamide 300 mg/2 days 1, 8, 15; dexamethasone 40 mg IV days 1 to 4 and 9 to 12); edemas and ascites underwent rapid resolution, vocal tone changed, and progressive recuperation of strength led to progressive improvement in functional state. Patient is currently in third treatment cycle and has undergone autologous transplant with high doses of melphalan as a conditioner, without complications. At the moment, patient is in follow-up and waiting for response evaluation at third month after autologous transplant.

Case 2

A 51-year-old female patient whose evolving 3-year clinical picture included progressive dyspnea, boot hypoesthesia, xeroderma and generalized scaling. Upon admission, patient suffered from progressive functional state deterioration that had reached NYHA IV/IV, generalized edema, adynamia, weight loss during past two months (approximately 20 kg) and adenopathy. Abdominal/pelvic and thoracic CT results revealed retroperitoneal and mediastinal adenomegaly with hepatosplenomegaly; hence, medical referral indicated suspicion of lymphoproliferative syndrome. Antecedents included hypothyroidism under treatment since 2 years ago, mitral valve prolapse, pulmonary thromboembolism, warfarin anticoagulant use from 3 years prior to admission, moderate pulmonary hypertension and infertility.

Physical examination revealed cachectic facies and evidence of central and peripheral cyanosis. Additional conditions observed included cervical adenopathy and level I jugular engorgement, systolic grade III/VI murmur in mitral focus, diminished respiratory sounds in both pulmonary fields, non-painful hepatosplenomegaly and bilateral inguinal adenopathy, symmetric limbs with lower limb edema, nail clubbing, leukonychia and generalized scaling. Neurological exam showed bilateral papilledema and boot and glove sensitivity deficit, symmetric upper limb strength at 4/5, bilateral lower limb strength at 3/5, muscle tendon reflexes at ++/++++, and altered walking pattern.

Upon discovery of patient's anemia, our institutional evaluation was requested; during which suggestive POEMS syndrome indicators were encountered, and subsequent confirmation studies were carried out. Brain scan was normal. Cerebrospinal fluid (CSF) revealed hyperparaproteinemia (103 mg/dl) without pleocytosis. Fluorescein angiography confirmed suspicion of cystoid macular edema. Periumbilical fat biopsy tested negative for vasculitis, granuloma or deposits of amyloid, and inguinal lymph node biopsy revealed a malignancy-negative mixed inflammatory infiltrate. These histological findings were interpreted as pertaining to multicentric Castleman disease. The remaining studies are shown in Table 1. Elevated VEGF levels were found and tests revealed presence of IgA lambda type paraproteinemia. POEMS syndrome diagnosis was made under fulfillment of mandatory criteria: sensorimotor polyneuropathy, monoclonal component (lambda light chains); as well as under major diagnostic criteria: Multicentric Castleman disease in lymph node biopsy and elevated VEGF serum levels; in addition to minor criteria: endocrinopathy (hypothyroidism, hypogonadism, and

hyperprolactinemia), organomegaly (splenomegaly, hepatomegaly and adenopathy, skin alterations (nail clubbing, leukonychia and hyperpigmentation in absence of pleocytosis, papilledema in absence of endocranial hypertension, cystoid macular edema, moderate pulmonary hypertension and weight loss).

Treatment began with combined cyclophosphamide and dexamethasone chemotherapy (cyclophosphamide 1500 mg/m² day 1 of each cycle; dexamethasone 40 mg day 1 to 4 and 9 to 12 in 21-day cycles) that lasted for 3 cycles without complications, and rapid clinical improvement. Initial impact brought about normalization of extravascular volume overload, organomegaly, adenomegaly, monoclonal gammopathy, VEGF levels, prolactin and hemoglobin. Patient underwent peripheral progenitor blood cell autologous transplant with high doses of melphalan used as a conditioner; a complication arose in the form of a type-2 acute myocardial infarction. Following transplant, treatment continued with 5 mg/day of prednisolone and levothyroxine. One year after transplant, right-side cardiac catheterization showed normal pulmonary systolic pressure. Physical exam revealed neuropathic recovery and complete hyperpigmentation resolution. Eight years after transplant, patient's condition continues in clinical and paraclinical remission.

Case 3

Review was performed on a 40-year-old male patient's case whose 1-year evolving clinical picture included initial lower limb edema and ascites; later, paresthesia and dysesthesia; and finally, paraparesis without upper limb compromise. Primary hypothyroidism had been diagnosed two weeks prior to admission. Physical exam revealed paraparesis at 4/5 in upper limbs, boot hypoesthesia and patellar and aquilianan symmetrical hyporeflexia, acral pigmentation with pigmentation in folds, hypertrichosis, leukonychia and level 1 digital clubbing. A sural nerve biopsy was performed that revealed non-specific mild demyelinating neuropathy, thus leading to initial CIDP diagnosis. Disease evolved rapidly accompanied by progressive functional limitations (Barthel Index <60 at admission) associated with weight loss, fluid overload (edemas and ascites) and increased skin hyperpigmentation. Seeking medical evaluation, patient was admitted to our institution. Requested diagnostic-confirmation paraclinical exams revealed CSF with slightly elevated protein count (100.9 mg/dl) without pleocytosis; abdominal-pelvic CT showed hepatosplenomegaly, lytic lesions characteristic of osteosclerotic myeloma on right-side ilium and on acetabular roof. IgA lambda type paraproteinemia and elevated VEGF levels were found, both considered requisite POEMS syndrome criteria.

Patient received cyclophosphamide plus dexamethasone chemotherapy (as did Case 2 patient) that resulted in rapid clinical response and overall physical improvement; this was followed by autologous transplant of peripheral progenitor blood cells with high doses of melphalan as conditioner, which brought about complete disease remission. At 8 years post-transplant, patient's disease continues in remission and no new symptoms have developed.

Discussion

POEMS syndrome is a rare disorder whose exact incidence is unknown. In general, it affects patients during fifth and sixth

decade of lifespan, with median age at 51 years [6]. Although the POEMS acronym summarizes the disease's major features, other frequent clinical features, whose identification may serve to reach earlier diagnosis, should be kept in mind; these include: Papilledema in absence of endocranial hypertension, extravascular volume overload, osteosclerotic lesions, elevated protein count in absence of pleocytosis and hematological alterations such as thrombocytosis and erythrocytosis [7]. In the three cases presented, bilateral papilledema in absence of endocranial hypertension and elevated protein count in absence of pleocytosis were identified, thus highlighting the need for adequate, in-depth, visual examination as well as for specialized studies based on optical coherence tomography and cerebrospinal fluid.

POEMS syndrome is a condition whose diagnosis can only be attained by means of a systematic semiological approach. Fundamental to timely diagnosis is an adequate patient interrogation that seeks out signs and symptoms produced by endocrinological alterations or those related to extravascular volume overload; this, in turn, should be combined, whenever possible, with in-depth electromyography studies.

Polyneuropathy is the major clinical manifestation of POEMS syndrome. Peripheral nerve damage may be subacute or chronic and is generally symmetric with features similar to those in CIDP patients [4]. Regarding electrodiagnostic test results, a retrospective study among 20 patients with POEMS syndrome criteria and 30 patients with CIDP criteria evaluated whether differences existed in parameters such as Distal Motor Latency (DML), Motor Nerve Conduction Velocity (MNCV), Compound Muscle Action Potential (CMAP), sensory nerve conduction velocity and Sensory Nerve Action Potential (SNAP). Significant differences were encountered between the two groups of patients, including: lower DML prolongation in POEMS patients as well as less reduced conduction velocity of motor or sensory nerves, greater CMAP reduction in distal stimulation in POEMS patients compared to CIDP patients, greater temporal dispersion and lower conduction blockage frequency with similar abnormalities in F waves and H-reflexes, among other abnormalities.

The finding of polyneuropathy is a requisite criterion. In all of our cases, polyneuropathy was the predominant clinical feature, one that arose out of progressive functional deterioration resulting in the prostration of all three patients, before definitive diagnosis was reached. All of our patients exhibited signs of demyelinating polyneuropathy accompanied by progressive functional deterioration, and one of them had been treated for CIDP, with no response. The foregoing highlights the need to carry out systematic physical examinations in patients with polyneuropathy clinical pictures as well as studies to detect the monoclonal component.

POEMS syndrome patients' peripheral nerve biopsies revealed high axonal degenerative rates and diffuse-form loss of myelinated fibers. In contrast, CIDP patients generally exhibit higher rates of endoneurial inflammation. However, no histological finding exists that is pathognomonic with either of the two entities, and a definitive correlation between clinical findings and electrodiagnostic studies has yet to be reached [8]. The difficulties in differential diagnosis means that 60% of POEMS syndrome patients are initially diagnosed for CIDP. No CIDP treatments are effective in POEMS syndrome patients; therefore, their lack of response should alert clinicians to search for alternative diagnoses.

Mandatory POEMS syndrome diagnostic criteria are: 1. Polyneuropathy (typically demyelinating); 2. Proliferative monoclonal plasma cell disorder (frequently gamma-type). Major criteria, of which one must be present to determine diagnosis, are: 1. Multicentric

Castleman disease; 2. Osteosclerotic lesions; 3. Elevated vascular endothelial growth factor. Among the minor criteria, we find: 1. Organomegaly (splenomegaly, hepatomegaly and lymphadenopathy); 2. Extravascular volume overload (pleural diffusion or ascites); 3. Endocrinopathy (adrenal, pituitary, gonadal, parathyroid or pancreatic); 4. Cutaneous alterations (hyperpigmentation, hypertrichosis, glomeruloid hemangioma, plethoric facies, acrocyanosis and leukonychia); 5. Papilledema; 6. Polycythemia/thrombocytosis, it is uncommon to find thrombocytopenia except in some cases of Castleman disease.

Other symptoms or characteristic signs are: nail clubbing, weight loss, pulmonary hypertension, restrictive lung disease, diarrhea and low vitamin B12 levels. The aforementioned cases fulfilled POEMS syndrome diagnostic criteria in which two had major criteria of elevated VEGF and one had Castleman disease, as well as the presence of a wide variety of minor criteria.

Cutaneous manifestations are present in 68% of patients, the most frequent are diffuse hyperpigmentation, plethora and acrocyanosis. Other manifestations include hyperhidrosis, leukonychia, necrotizing vasculitis, hypertrichosis and calciphylaxis. Cutaneous thickening and sclerodermiform conditions have also been reported, similar to those that appear in Case 1. [9-11].

Cytokine production is related to patients' clinical manifestations. TNF-alpha is associated with peripheral neuropathy, demyelination, hepatomegaly, splenomegaly and endocrine malfunction. Interleukin-1B is correlated with cachexia, anorexia and cutaneous pigmentation caused by activation of the proopiomelanocortin gene. The IL-6 gene is related to plasmocyte proliferation, monoclonal gammopathy, thrombocytosis, Castleman disease, hemangiomas and microangiopathic glomerulopathy. VEGF induces an increase in capillary permeability and angiogenesis; it is implicated in the development of hydric overload, pulmonary hypertension, macular compromise, papilledema, glomeruloid hemangiomas and nail clubbing [12].

The vast majority of patients exhibit more diffuse bone marrow compromise and require systemic treatment. Adequate bone evaluation should seek out osteosclerotic lesions, which when appearing alone or grouped together can be treated in a single radiotherapy field. This treatment alternative may be adequate and may lead to the resolution of clinical manifestations [13]. Lesion detection may turn out to be a complex process when clinical suspicion is low and different imaging methods are being considered for their detection.

Positron Emission Tomography (PET-CT) has proven to be the most sensitive imaging method in detecting bone lesions in multiple myeloma patients and its use in POEMS syndrome has been described. One study with 90 confirmed POEMS syndrome patients found that the total number of flurodeoxyglucose (FDG)-avid sclerotic bone lesions were commonly found in the pelvis, thoracic vertebrae, ribs and lumbar spine. Interestingly enough, lesions' appearance in fifteen patients at three months following treatment showed lesion captation reduction but tomographic images identified no changes. This imaging mode further allows for follow up of adenomegaly that are identified at diagnosis, as well as that for hepatomegaly and splenomegaly, which tend to have abnormal captation [14].

Most patients require systemic treatment [15]. Given the disease's low prevalence, carrying out clinical trials has been difficult since recruitment rates are low and no therapy exists which could be considered standard treatment for this entity. However, treatment schemes derived from other forms of multiple myeloma therapy have

served as the most common approach. Initial therapy is oriented toward the eradication of clonal tumour plasma cells.

Most treatment schemes recommend a combination of aliquant agents (melphalan and cyclophosphamide) with a systemic steroid and with or without additional immunomodulatory agents or inhibitors, followed by autologous transplant in patients whose functional condition and response allow for it. The only randomized clinical trial published to date on this condition included 25 patients who were assigned to treatment with dexamethasone and thalidomide or dexamethasone with a placebo. The primary objective was to reduce VEGF levels by post-treatment week 24; a greater reduction was observed in the thalidomide treatment group. However, this study has been criticized for not having a clinical outcome and for the low number of patients included therein, and it is not possible to consider thalidomide-based treatment as appropriate standard treatment for this condition [16].

Autologous progenitor cell transplant has proven to be the treatment related to greatest survival rates. A study that included 127 POEMS syndrome patients who were treated with autologous transplant between 1997 and 2010 showed that average time from diagnosis to transplant was 7.5 months. In thirteen patients (12.6%), transplant was used as first line treatment. Conditioning was carried out with melphalan (200 mg/m²) in all but one patient who underwent Total Body Irradiation (TBI). Average infused CD34 cell dose was 4.3×10^6 /kg. In total, 123 patients achieved successful graft at an average of 13 days post-myeloid grafting and of 16 days post-platelet grafting. Surprisingly, 29 patients exhibited graft-versus-host disease that responded to steroid treatment. A total of 114 patients (90%) were alive at a median of 48 follow-up months (CI 95%: 38.3, 58.6); of the thirteen who died, cause of death was disease progression [17].

Other studies have confirmed high long-term overall survival rates in patients who received autologous transplant [18]. Two of our three patients successfully underwent autologous transplant, with no evidence of disease progression at 8 years follow-up, and the latter suffered no complication and had favorable evolution during the first post-procedure months. In one case, patient suffered acute myocardial infarction during transplant process, however angiography study resulted normal with no signs of coronary vascular lesions present. Although an association has been described of ischemic cerebrovascular events in POEMS syndrome patients, to date the association with coronary events has not been clearly identified, and it is not known if modification and aggressive treatment of described preventive vascular risk factors for cerebral events may be extrapolated to coronary events [19].

The use of immunomodulatory agents such as lenalidomide and treatment with proteasome inhibitors such as bortezomib have been reported in patient series with good results and adequate tolerance. A systematic study revision included eleven studies where, regardless of sample size, design or treatment phase, lenalidomide was used in a total of 51 POEMS syndrome patients. Median patient age was 54.5 years. The medication was used in first line as well as second line and reported hematologic response rates were greater than 60%, and progression-free survival was at 93.9% at 12 months. This is, therefore, a treatment option that appears to be safe and efficient; however, clinical trials that validate its utility need to be carried out [20].

Conclusion

POEMS syndrome is a rare paraneoplastic syndrome with diverse clinical manifestations that can be easily attributed to other diagnoses. To reach proper POEMS syndrome diagnosis, it is necessary to

combine a high level of clinical suspicion with a systematic physical examination approach and appropriate diagnostic test evaluations. Patient prognosis is favourable with the treatment options currently available, thus highlighting even more so the need for timely diagnosis. Research on patients with unexplained cause of polyneuropathy should include, beyond the carrying out of electrodiagnostic studies, patient interrogation and physical examination focused on this condition, as well as electrophoresis and serum immunofixation studies in order to detect monoclonal proteins.

References

1. Birkenbach A, Kühlhorn F, Grube M, Helbig H, Gamulescu MA (2016) POEMS-Syndrom als seltene Ursache eines bilateralen Papillenödems. *Der Ophthalmol* 2-5.
2. Dispenzieri A (2015) POEMS syndrome: Update on diagnosis, risk-stratification, and management. *Am J Hematol* 90: 951-962.
3. Gherardi RK, Bélec L, Soubrier M, Malapert D, Zuber M, et al. (1996) Overproduction of proinflammatory cytokines imbalanced by their antagonists in POEMS syndrome. *Blood* 87: 1458-1465.
4. Guo X, Qin X, Zhang Y, Huang C, Yu G (2014) Electrophysiological features of POEMS syndrome and chronic inflammatory demyelinating polyneuropathy. *J Clin Neurosci*. Elsevier Ltd 21: 587-590.
5. Latov N (2014) Diagnosis and treatment of chronic acquired demyelinating polyneuropathies. *Nat Rev Neurol*. Nature Publishing Group 10: 435-446.
6. Dispenzieri A, Kyle RA, Lacy MQ, Rajkumar SV, Therneau TM, et al. (2003) POEMS syndrome: Definitions and long-term outcome. *Blood* 101: 2496-2506.
7. Kourelis TV, Buadi FK, Kumar SK, Gertz MA, Lacy MQ, et al. (2016) Long-term outcome of patients with POEMS syndrome: An update of the Mayo Clinic experience. *Am J Hematol* 91: 585-589.
8. Piccione EA, Engelstad J, Dyck PJ, Mauermann ML, Dispenzieri A, et al. (2016) Nerve pathologic features differentiate POEMS syndrome from CIDP. *Acta Neuropathol Commun*. Acta Neuropathologica Communications 4: 116.
9. Lo Presti S, Kanagarajah P, Pirella D, Morlote D, Cusnir M (2016) An occult malignancy behind a demyelinating disease. *J Investig Med High Impact Case Reports* 4: 232-247.
10. Information CME. (2015) 90: 951- 962.
11. Marinho FS, Pirmez R, Nogueira R, Cuzzi T, Sodré CT, et al. (2015) Cutaneous manifestations in POEMS syndrome: Case report and review. *Case Rep Dermatol* 7: 61-69.
12. Miest RYN, Comfere NI, Dispenzieri A, Lohse CM, El-Azhary RA (2013) Cutaneous manifestations in patients with POEMS syndrome. *Int J Dermatol* 52: 1349-1356.
13. Suh YG, Kim YS, Suh CO, Cheong JW (2014) The role of radiotherapy in the management of penile cancer. *Radiat Oncol* 9: 1-9.
14. Pan Q, Li J, Li F, Zhou D, Zhu Z (2015) Characterizing POEMS Syndrome with 18F-FDG PET/CT. *J Nucl Med* 56: 1334-1337.
15. Dispenzieri A (2012) How I treat POEMS syndrome. *Blood* 119: 5650-5658.
16. Misawa S, Sato Y, Katayama K, Nagashima K, Aoyagi R, et al. (2016) Safety and efficacy of thalidomide in patients with POEMS syndrome: A multicentre, randomised, double-blind, placebo-controlled trial. *Lancet Neurol* 15: 1129-1137.
17. Cook G, Iacobelli S, Van Biezen A, Ziagkos D, LeBlond V, et al. (2017) High dose therapy and autologous stem cell transplantation in patients with POEMS syndrome: A retrospective study of the plasma cell disorder sub-committee of the chronic malignancy working party of the European Society for blood and amp marrow transplant. *Haematologica* 102: 1.
18. D'Souza A, Lacy M, Gertz M, Kumar S, Buadi F, et al. (2012) Long-term outcomes after autologous stem cell transplantation for patients with POEMS syndrome (osteosclerotic myeloma): A single-center experience 120: 56-62.
19. Dupont SA, Dispenzieri A, Mauermann ML, Rabinstein AA, Brown RD (2009) Cerebral infarction in POEMS syndrome incidence, risk factors and imaging characteristics. *Neurology* 73: 1308-1312
20. Zagouri F, Kastiris E, Gavriatopoulou M, Sergentanis TN, Psaltopoulou T, et al. (2014) Lenalidomide in patients with POEMS syndrome: A systematic review and pooled analysis. *Leuk Lymphoma* 55: 2018-2023.