

Pleomorphic Liposarcoma of Sigmoid Mesocolon: A Case Report and Literature Review

Zhang Xinhuai^{1*}, Wang Xiaoqun¹, Miao Jinchao², Liu Zanwei², Lin Xiaofeng², Huang Jiarong², Shi Shange² and Wu Hui¹

¹Department of Gastrointestinal Surgery, The First Affiliated Hospital of Sun Yat-Sen University, Yuexiu Qu, Guangzhou Shi, Guangdong Sheng, P. R. China

²Department of General Surgery, The First Affiliated Hospital of Sun Yat-Sen University, Yuexiu Qu, Guangzhou Shi, Guangdong Sheng, P. R. China

*Corresponding author: Zhang Xinhuai, Department of Gastrointestinal Surgery, The First Affiliated Hospital of Sun Yat-Sen University, 58 Zhongshan 2nd Rd, Yuexiu Qu, Guangzhou Shi, Guangdong Sheng, P. R. China, Tel: +86 15626447224; E-mail: cc_xh@hotmail.com

Received date: February 17, 2019; Accepted date: February 26, 2019; Published date: March 5, 2019

Copyright: © 2019 Xinhuai Z, et al. This is an open-access article distributed under the terms of the Creative Commons Attribution License, which permits unrestricted use, distribution, and reproduction in any medium, provided the original author and source are credited.

Abstract

Background and objective: Liposarcoma arising from colonic mesentery was rare and its biological behavior and clinical management is not well known. We aimed to explore the clinicopathological features and management of liposarcoma in colonic mesentery by presenting a case of pleomorphic liposarcoma of sigmoid mesentery with literature review.

Methods: A patient of sigmoid mesentery pleomorphic liposarcoma was successfully treated in Pengpai Commemorative Hospital. With this case included, there were total of 10 cases of colonic mesentery liposarcoma reported by reviewing literature from English database. Clinical and pathological features, treatment and prognosis were analyzed.

Results: The patient underwent complete tumor resection successfully, and had an uneventful recovery after surgery. Of total 10 patients, the median age was 49years, with tumor size from 2 cm to 50 cm. In pathology, 4 (40%) were of well-differentiated, 3 (30%) of mucinous, 1 dedifferentiated, 1 pleomorphic, and 1 case of primary mucinous liposarcoma from the sigmoid mesocolon accompanied with well-differentiated liposarcomas in the pelvis. Eight of 10 patients had follow-up data. The median follow-up period was 21 months. Recurrence was recorded in 2 cases (25%), of which 2 cases were mucinous liposarcoma.

Conclusion: Sigmoid mesocolic pleomorphic liposarcoma is rare and of unfavorable prognosis. Complete resection is the mainstay of treatment. Tumor size and complete resection with clear margin are the main prognostic factors.

Keywords: Liposarcoma; Mesentery of sigmoid colon; Surgery

Introduction

Liposarcoma is a common malignancy accounting for nearly 20% of all kinds of soft tissue sarcoma in adults [1]. It usually occurs between the age of 40 and 60 years, in which men are slightly predominant. This tumor derives from primary interstitial cell and is seen 70% in deep soft tissue, 20% in retroperitoneum, then head, neck and trunk [2]. However, it is not common for liposarcoma arising from mesentery of small intestine and rare from mesocolon,

Because of limited literature, less is known about its clinical and pathological features. Hence we report a case of pleomorphic liposarcoma involved sigmoid mesocolon that was treated successfully with surgery and retrospectively analyzed similar cases by reviewing literatures.

Case Report

A 49-year-old man complained of left lower abdominal mass for 2 days was admitted on August 20, 2015. By physical examination, a fixed, oval hard 10 cm × 7 cm mass in the left lower quadrants was found. Neither abdominal dullness and nor enlarged liver or spleen were palpated. Per rectal examination was normal. Laboratory findings

of complete blood cell count, blood chemistry and common tumor markers were all in normal range, including AFP, CEA and CA-199 (0.80 ng/ml, 1.80 ng/ml and 23.20 U/ml, respectively). Abdominal CT showed extensively thickening intestinal wall of sigmoid colon surrounded by enhanced mesenteric fat, which was probably caused by pelvic mesenchymal tumor (Figure 1).

Colonoscopy indicated extra-luminal compressive change in the segment of sigmoid colon, with intact mucosa. After multi-disciplinary discussion, on August 25, 2015 the patient underwent a laparotomy. During surgical exploration, there was small amount of yellowish ascites. Extensively thickening sigmoid colonic mesentery and proliferative epiploic appendages were found. A 12 cm × 10 cm × 8 cm oval-shaped, solid, red-yellowish mass was detected in the mesentery of sigmoid colon with intact, smooth capsule (Figure 2). It invaded the serosa of sigmoid colon, fixed to the retroperitoneum with psaos major suspiciously involved. Neither enlarged lymph node was detected around the root of inferior mesenteric artery nor further metastasis in the peritoneal cavity. The mass was considered to be liposarcoma and was removed en-bloc with sigmoid colon followed by an end-to-side anastomosis of descending colon and rectum (Figure 2).

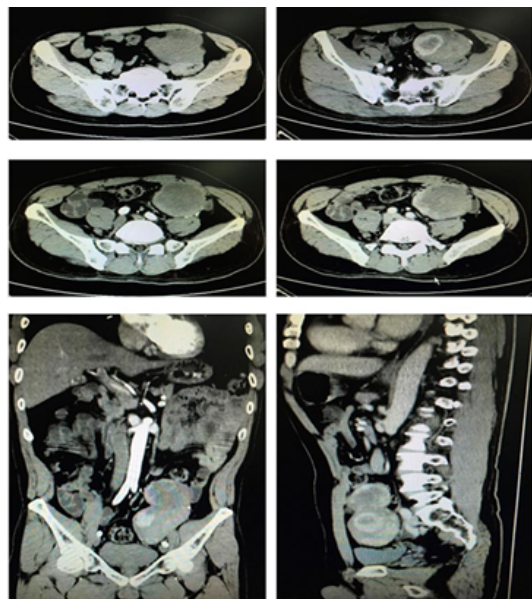


Figure 1: Abdominal CT.

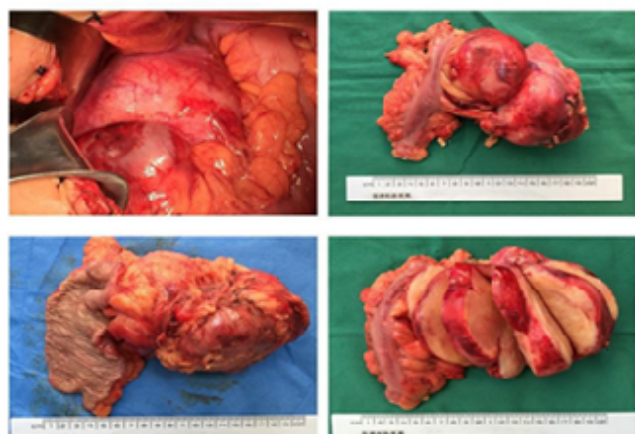


Figure 2: Pictures taken in the surgery and dissection after the surgery.

The patient recovered uneventfully after surgery and was discharged on post-operative day of 10. Pathology was sent to the First Affiliated

Hospital of Sun Yat-sen University for consultation, which ascertained that it was pleomorphic liposarcoma of sigmoid mesentery (Figure 3). Recurrence or distant metastasis did not come up till May 2017 (21 months post-operatively).

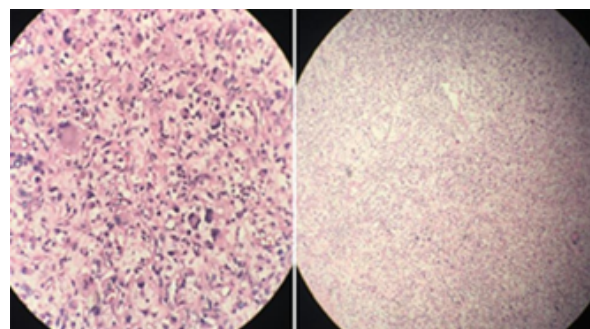


Figure 3: Microscopic evidence of pleomorphic liposarcoma (left 400x, right 100x).

Literature Review

We searched Pubmed for English literature and found only 9 cases of liposarcoma of colonic mesentery had received surgery with definite diagnosis (Table 1) [3-13]. Taking our case into account, statistics show median age of incidence is 49 years old, male in 6 and female in 4 cases. Tumor size varies from 2 cm to 50 cm.

Five cases were located in mesentery of sigmoid colon or rectosigmoid junction. Three cases were found in the mesentery of ascending colon, 1 of transverse colon and 1 of descending colon. From the 10 cases above, there were 2 cases of multiple origins or local-regional metastasis, of which one was multiple primary liposarcomas in sigmoid mesocolon and pelvic cavity and the other, was multiple liposarcomas of mesentery of transverse colon.

Pathological study consists of 4 cases of well-differentiated liposarcoma, 3 cases of myxoid liposarcoma, 1 case of dedifferentiated, 1 case of pleomorphic, and the patient with concurrent lesions from sigmoid mesocolon and pelvis being found that it was myxoid liposarcoma and well-differentiated types in either location, respectively. Follow-up data was available in 8 out of 10 cases, with the median follow-up of 21 months. Recurrence was found in 2 cases (25%) 26 months and 7 years after the surgery respectively. Both cases were of myxoid liposarcoma.

Author/Year/Reference	Age (years)/Gender	Clinical presentation	Location	Local/Recurrent metastasis	Tumor size (cm)	Histological type	Follow up	Recurrence
Ishiguro/2006 [3]	30/Male	Abdominal distention	Distal ileum and mesentery of the ascending colon	Primary, limited	30 cm	Myxoid	26 m	Yes
Zhianpour and Sirous/2010 [4]	35/Male	Constipation, vomiting, abdominal distention	Mesentery of sigmoid colon	Primary, limited	50 × 40 × 10 cm	Well differentiated	24 m	No

Goel/1994 [5]	48/Male	Abdominal pain, nausea	Mesentery of rectosigmoid junction	Primary, limited	-	Well differentiated	-	-
Amato/1998 [6]	75/Female	Constipation, Abdominal pain, change in bowel habits	Mesentery of sigmoid colon	Primary, limited	2 cm	Well differentiated	24 m	No
Takeda/2012 [7]	71/Male	Abdominal distention	Mesentery of right colon	Primary, limited	11 × 9 cm	Differentiated	6 m	No
Eltweri/2013 [8]	34/Female	-	Mesentery of right colon	Primary, limited	25 × 22 × 11 cm	Myxoid	7 y	Yes (3 m after second operation)
Sachidananda/2013 [9]	63/Female	Abdominal distention, poor appetite	Mesentery of transverse colon	Differentiated between multiple primary and satellite deposits	Main body of the tumor: 16 × 16 × 10 cm, satellite deposits: 4-7 cm	Well differentiated	-	-
Shen/2014 [10]	49/Female	Abdominal discomfort, abdominal mass	Mesentery of sigmoid colon/pelvis	Multiple primary	20 × 21 × 6 cm and 8 × 7 × 5.4 cm	Myxoid (Mesentery of sigmoid colon), Well differentiated (pelvis)	17 m	No
Uslukaya/2014 [11]	47/Male	Epigastric pain, abdominal distention	Mesentery of descending colon	Multiple	36 × 37 × 27 cm	Myxoid	12 m	No
Our case	49/Male	Abdominal mass in the left lower quadrant	Mesentery of sigmoid colon	Multiple	13 × 10 cm	Pleomorphic	18 m	No

Table 1: Clinico-pathological data of mesocolic liposarcoma.

Discussion

Liposarcoma is most common seen in extremities, trunk and retroperitoneum. The tumor size ranges from 3 to 10 cm in diameter, sometimes larger than 20 cm [2]. As far as our concern, this is the first reported primary pleomorphic liposarcoma in mesocolon. According to 2013 WHO classification of soft tissue sarcoma, the pathological type of liposarcoma is classified into atypical lipomatous tumor/well-differentiated liposarcoma (ALT/WDLs), dedifferentiated liposarcoma (DLS), myxoidMLSand pleomorphic liposarcoma (PLS) [14]. Well-differentiated~50% and myxoid liposarcoma ~30%are the most common type, while pleomorphic liposarcoma accounts for about 5%. The biological behavior varies among these pathological types. Well-differentiated liposarcoma is a low grade tumor that is prone to local recurrence but rarely metastasizes. Dedifferentiated and pleomorphic, on the other side, are high-grade tumors often accompanied with distant metastasis. The behavior of myxoid type is considered in between, with almost 1/3 of patients show metastasis. With the development of molecular analysis technology, PLS is detected to carry no *MDM2* gene amplification as ALT/WDLs/DLS [15] or [t (12;16) (q13;p11)], corresponding FUS-DDIT3 or EWSR1-DDIT3 fused gene [16,17] to [t (12;22) (q13;q12)] as MLS. Therefore PLS is defined as a special subtype of liposarcoma. Limited studies concerning this subtype demonstrated that local recurrence rate was as high as 45% and distant metastatic rate was 44% [18,19]. Another respective study concluding 24 cases of PLS with median follow-up time of 16 months stated recurrence rate was 42% and mortality reached 16.7%. Moreover, tumor size larger than 10 cm was an independent poor prognostic indicator [20].

Moreover, primary mesenteric tumor is not common. The ratio of benign to malignant is approximately 2:1 [21]. They are derived from peritoneum, lymph node, fat and connective tissue. The most common cystic tumor of the mesentery is benign lymphangioma, accounting for more than 50% [22]. Lymphoma, however, is the most common solid tumor in the mesentery. Others might be desmoid tumor (aggressive fibromatosis), Castleman's disease and metastatic lymph nodes from neuroendocrine tumor [23,24]. Clinical manifestation varies due to age, pathology and tumor size. Undoubtedly it remains rather a challenge for early diagnosis due to insidious biological nature.

Primary mesentery liposarcoma is rare, especially those arising from colonic mesentery. We searched for English literature including only 9 cases of which 8 came to a specific pathological type. Lack of typical symptoms often hampers early diagnosis. Surgery is reckoned as the only curative modality for local mesenteric tumor. As suggested, en-bloc complete excision with safe resection margin at least 1 cm to tumor or the reaction zone on MRI is recommended [24]. Different from extremities and trunk, tumor located in mesentery and retroperitoneum is usually larger, squeezing vital vessels and organs and making it difficult to accomplish complete resection reserving organ as well as important vessels/nerves function with intact tumor capsule, not to mention more than 1 cm negative margin. Most researches declare that prognosis of mesenteric liposarcoma was associated with pathological grading and safe surgical margin [1]. Liposarcomas from extremities and trunk have more favorable prognosis than those from mesentery and retroperitoneum, which may be attributed that it is easier to reach safe margin in extremities and trunk [25]. In our case of PLS, recurrence has not occurred yet. As for the other 7 cases with follow-up data and specific pathological type, two recurrent cases were both MLS, classified as moderate grade.

Concerning the effect of adjuvant chemotherapy is uncertain [25], we did not advise further treatment. Although we sought to perform complete resection for our case, considering the tumor was as huge as 12 cm and high grade in biological behavior pattern, we will keep close follow-up.

Conclusion

In conclusion, pleomorphic liposarcoma belongs to a high grade malignancy and is rarely seen in colonic mesentery. It is difficult to detect the tumor in early phase due to its insidious biological course. En-bloc resection with clear margin is crucial yet sometimes challenged in treating mesenteric liposarcoma. Tumor size and complete resection with clear margin are the main factors for predicting prognosis. Close follow-up is suggested because it is prone to recurrence and metastasis.

Conflict of Interest

We have no conflicts of interest to declare.

Informed Consent

We have obtained the patient's informed consent allowing us to print and electronically publish this case report.

References

- Lucas DR, Nascimento AG, Sanjay BK, Rock MG (1994) Well-differentiated liposarcoma. The mayo clinic experience with 58 cases. *Am J Clin Pathol* 102: 677-683.
- Ferrario T, Karakousis CP (2003) Retroperitoneal sarcomas: Grade and survival. *Arch Surg* 138: 248-251.
- Ishiguro S, Yamamoto S, Chuman H, Yoshihiro Moriya (2006) A case of resected huge ileocolonic mesenteric liposarcoma which responded to pre-operative chemotherapy using doxorubicin, cisplatin and ifosfamide. *Jap J of Clin Oncol* 36: 735-738.
- Zhianpour M, Sirous M (2010) Abdominal imaging huge liposarcoma of the sigmoid mesocolon: A case report. *Irj of Radiol* 7: 251-253.
- Goel AK, Sinha S, Kumar A, Karak AK, Chattopadhyay TK (1994) Liposarcoma of the mesocolon-case report of a rare lesion. *Surg Today* 24: 1003-1006.
- Amato G, Martella A, Ferraraccio F, Di Martino N, Maffettone V, et al. (1998) Well differentiated 'lipoma-like' liposarcoma of the sigmoid mesocolon and multiple lipomatosis of the rectosigmoid colon. *Report of a case. Hepatogastroentero*, 45: 2151-2156.
- Takeda K, Aimoto T, Yoshioka M, Nakamura Y, Yamahatsu K, et al. (2012) Dedifferentiated liposarcoma arising from the mesocolon ascendens: Report of a case. *J Nippon Med Sch* 79: 385-390.
- Eltweri AM, Gravante G, Read-Jones SL, Rai S, Bowrey DJ, et al. (2013) A case of recurrent mesocolon myxoid liposarcoma and review of the literature. *Case Rep Oncol Med* 2013: 692754.
- Sachidananda S, Krishnan A, Ramesh R, Kuppurao S (2013) Primary multiple mesenteric liposarcoma of the transverse mesocolon. *Ann Coloproctol*. 29: 123-125.
- Shen Z, Wang S, Fu L, Fu L, Shi J, Yin M et al. (2014) Therapeutic experience with primary liposarcoma from the sigmoid mesocolon accompanied with well-differentiated liposarcomas in the pelvis. *Surg Today*.44: 1863-1868.
- Uslukaya O, Taskesen F, Aliosmanoglu I, Arikanoglu Z, Gul M et al. (2014) Giant myxoid liposarcoma of descending mesocolon origin. *PrzGastroenterol*.9: 361-364.
- Fletcher CDM, Bridge JA, Hogendoorn PCW, Mertens F (2013) WHO Classification of Tumours of Soft Tissue and Bone. 4th edition Lyon: 33-42.
- Sirvent N, Coindre JM, Maire G, Hostein I, Keslair F, et al. (2007) Detection of MDM2-CDK4 amplification by fluorescence in situ hybridization in 200paraffin-embedded tumor samples: Utility in diagnosing a dipocytic lesions and comparison with immunohistochemistry and real-time PCR. *Am J SurgPathol* 31: 1476-1489.
- Antonescu CR, Elahi A, Humphrey M, Lui MY, Healey JH et al. (2000) Specificity of TLSCHOP rearrangement for classic myxoid/round cell liposarcoma: Absence in predominantly myxoid well-differentiated liposarcomas. *J Mol Diagn* 2: 132-138.
- Hosaka T, Nakashima Y, Kusuzaki K, Murata H, Nakayama T et al. (2002) A novel type of EWS-CHOP fusion gene in two cases of myxoid liposarcoma. *J Mol Diagn* 4: 164-171.
- Gebhard S, Coindre JM, Michels JJ, Terrier P, Bertrand G et al. (2002) Pleomorphic liposarcoma: Clinicopathologic, immunohistochemical, and follow-up analysis of 63 cases: A study from the French Federation of cancer Centers Sarcoma Group. *Am J SurgPathol* 26: 601-666.
- Hornick JL, Bosenberg MW, Mentzel T, McMenamin ME, Oliveira AM, et al. (2004) Pleomorphic liposarcoma: Clinicopathologic analysis of 57 cases. *Am J Surg Pathol* 28:1257-1267.
- Wang L, Ren W, Zhou X, Sheng W, Wang J (2013) Pleomorphic liposarcoma: A clinicopathological, immunohistochemical and molecular cytogenetic study of 32 additional cases. *Pathol Int*.63: 523-531.
- Fotiadis C, Zografos GN, Karutzas G (2000) Recurrent liposarcomas of the abdomen and retroperitoneum: Three case reports. *Anticancer Res* 20: 579-583.
- de Perrot M, Brundler M, Totsch M, Mentha G, Morel P (2000) Mesenteric cysts. Toward less confusion? *Dig Surg* 17: 323-328.
- Sheth S, Horton KM, Garland MR, Fishman EK (2003) Mesenteric neoplasms: CT appearances of primary and secondary tumors and differential diagnosis. *Radiographics* 23: 457-473.
- Dufay C, Abdelli A, Le Pennec V, Chiche L (2012) Mesenteric tumors: Diagnosis and treatment. *J Visc Surg* 149: 239-251
- Lu J, Qin Q, Zhan LL, Yang X, Xu Q, et al. (2014) Computed tomography manifestations of histologic subtypes of retroperitoneal liposarcoma. *Asian Pac J Cancer Prev*. 15: 6041-6046.
- The NCCN soft tissue sarcoma clinical practice guidelines in oncology (2017) (version 2.2017) [EB/OL]. Fort Washington: NCCN
- Tan MC, Brennan MF, Kuk D, Agaram NP, Antonescu CR, et al. (2016) Histology-based classification predicts pattern of recurrence and improves risk stratification in primary retroperitoneal sarcoma. *Ann Surg*. 263: 593-600