

Case Report

Open Access

Pityriasis Lichenoides Et Varioliformis Acuta; Association with Tetanus Vaccination

Leyla Baykal*, Deniz Aksu Arica, Savaş Yaylı, Ece Altun and Sevgi Bahadı

Artvin State Hospital, Artvin, Turkey

Abstract

Pityriasis lichenoides (PL) is an uncommon acquired skin disease of unknown etiology. The disease is speculated to be an inflammatory disease triggered by infectious agents, an inflammatory response to T-cell dyscrasia, or an immune complex mediated hypersensitivity. We report the first case of PL et varioliformis acuta (PLEVA) occurring after tetanus vaccination.

Keywords: Pityriasis lichenoides; Vaccination; Tetanus

Introduction

Pityriasis lichenoides is an uncommon acquired skin disease of unknown etiology [1]. Since it is rare it may be overlooked, but it is important as it bears a significant risk of morbidity with potential progression to cutaneous lymphoma or an ulceronecrotic appearance [2]. There are two clinical forms, pityriasis lichenoides et varioliformis acuta (PLEVA) and pityriasis lichenoides chronica. PLEVA is characterized by erythematous macules, papules and papulovesicles. Reddish-brown crusted areas gradually develop and result in varioliform scarring [1]. Side-effects associated with tetanus vaccination are uncommon and generally mild. Temporary viral exanthem and urticarial lesions may occur as a side-effect of vaccination in some individuals. To the best of our knowledge, PLEVA following vaccination has only been described in two cases, and none of them was seen to be triggered by tetanus vaccination.

Case Report

A 30-year-old male patient presented to our dermatology clinic with mildly itching eruptions on the body over the previous 2 weeks. At the time of presentation the lesions had spread to the entire body and extremities. We learned from his history that he had received a tetanus vaccination 10 days before onset of the lesions. No additional history of systemic infection fever or drug use before the lesions was determined.

No pathological finding was observed at general examination, and there was no fever. Dermatological examination revealed widespread erythematous crusted lesions, on the trunk and extremities, some of them were squamous and hemorrhagic (Figures 1a and 1b). There was no involvement on feet or hairy skin. There was no pathologic

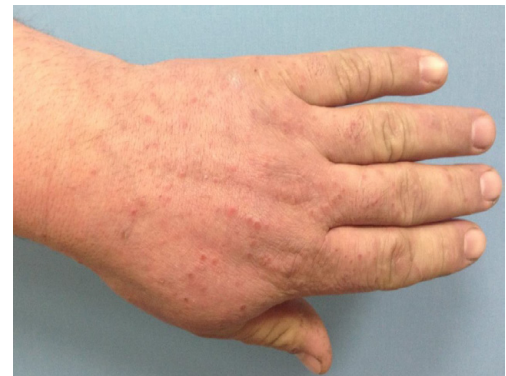

Figure 1b: Erythematous papules on hands.

lymphadenopathy at the examination. Routine laboratory findings were normal except mild leucocytosis, VDRL, Hepatitis B and C serology, HIV were negative. Liver and kidney function tests were normal. A 4mm punch skin biopsy was performed. The histopathologic examination revealed surface crust formation, liquefactive degeneration and parakeratosis in the epidermis, reactive proliferation, granular layer thinning. Basal layer vacuolar interface dermatitis and active chronic cell infection around the vessels and skin annexes and cellular infiltration, erythrocyte extravasation and PLEVA was diagnosed on the basis of the existing findings (Figures 2a and 2b).

The patient was started on doxycycline 100 mg, and the lesions resolved in 8 weeks.

Discussion

Pityriasis lichenoides was first described by Neisser and Jadassohn. There are two separate clinical forms, PLEVA and PLC. The terms acute and chronic refer, not to duration of the disease, but to the characteristic features of the lesions [3,4]. The two clinical

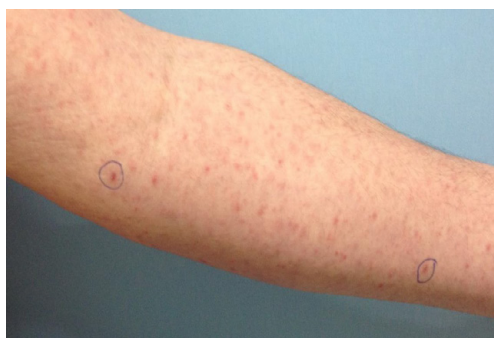

Figure 1a: Erythematous crusted lesions on extremities, some are hemorrhagic (in boxes).

*Corresponding author: Leyla Baykal, Artvin State Hospital, Artvin, Turkey, Tel: +90 466 212 1040; E-mail: lb_leyla@hotmail.com

Received January 08, 2015; Accepted April 18, 2015; Published April 20, 2015

Citation: Baykal L, Arica DA, Yaylı S, Altun E, Bahadı S (2015) Pityriasis Lichenoides Et Varioliformis Acuta; Association with Tetanus Vaccination. J Clin Case Rep 5: 518. doi:10.4172/2165-7920.1000518

Copyright: © 2015 Baykal L, et al. This is an open-access article distributed under the terms of the Creative Commons Attribution License, which permits unrestricted use, distribution, and reproduction in any medium, provided the original author and source are credited.

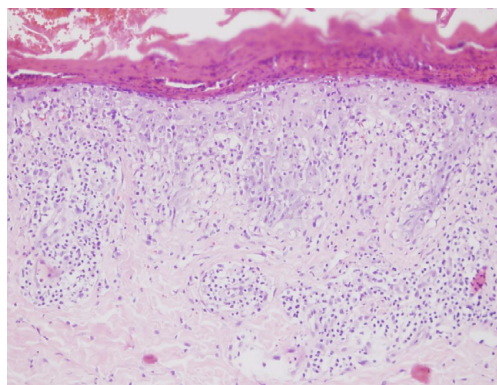


Figure 2a: Histologic features of pityriasis lichenoides acuta. Parakeratosis, superficial dermal lymphohistiocytic infiltrate, basal layer vacuolization (hematoxylin-eosin 100×).

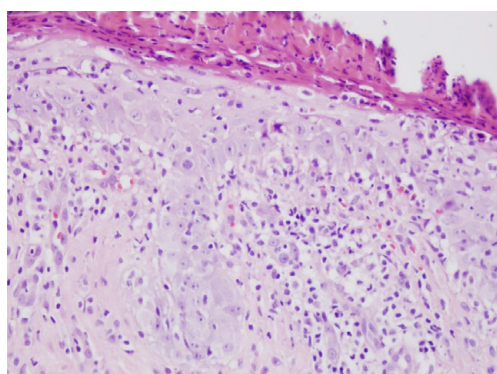


Figure 2b: Confluent parakeratosis, Erythrocyte extravasation, Basal layer vacuolization (hematoxylin-eosin 200×).

and histopathological characteristics may be seen concomitantly in some patients. The underlying pathogenic mechanism in pityriasis lichenoides is unknown. However, it has been suggested that it may develop secondary to infectious or lymphoproliferative diseases or may be a hypersensitivity reaction associated with a type of drug [5,6]. High antibody titers to various infectious agents such as human immunodeficiency virus, hepatitis C virus, cytomegalovirus, Epstein Barr virus, toxoplasma gondii and herpes simplex virus have been observed concurrently with the disease, but no definitive relation has been established [7,8]. Recent studies agree that PLEVA is a benign disease associated with activated T lymphocytes. Pityriasis lichenoides can affect children and adults. The prevalence is trimodal, peaking in the 3rd decade of life [1]. Hemorrhagic pustules and potentially necrotic erythematous macules and papules are seen in PLEVA. Lesions at different stages being observed concurrently is a significant finding. Lesions are generally seen on the trunk and in the flexural areas of the extremities, although generalized eruption can also occur [9]. It is rare for systemic findings to be observed in the disease period. Lesions are generally asymptomatic, but may be accompanied by mild itching [1].

Administration of the diphtheria-tetanus-acellular pertussis vaccine is routinely recommended in children, with a single booster dose of a vaccine containing tetanus toxoid, reduced diphtheria toxoid, and acellular pertussis (Tdap) recommended for 11- to 12-year-olds, followed by tetanus toxoid and the reduced diphtheria toxoid in the form of Td recommended at 10-year intervals throughout life. There

are a few reports consistent with anaphylaxis (including fatalities) to tetanus vaccines, some of which were supported by positive skin tests and elevated levels of allergen-specific IgE directed against tetanus and diphtheria (Td) toxoids [10].

PLEVA following vaccination has been determined in two cases. One of these was a 2.5-year-old boy, with PLEVA lesions developing 5 days after measles vaccination. Infectious serology was investigated and proved negative. In 2011, Gunatheesan et al. described PLEVA on the trunk of an 8-year-old girl developing 10 days after measles-mumps-rubella (MMR) live vaccination. The vaccinations thought to trigger PLEVA in both cases are live vaccination. Lesions were occurred in only a few days after vaccination, and no fever or general status compromised was observed in either these cases or in our patient [1]. To the best of our knowledge, PLC has been previously associated with vaccination in only one patient. Deborah et al. described widespread PLC lesions developing within 10 days after measles vaccination [11].

Cases of drug-induced PLEVA are rare in the literature. These drugs include tegafur, astemizole, estrogen-progesterone therapy and radiocontrast agents. Machan et al. reported PLEVA developing after intravenous immunoglobulin in a patient with combined immune deficiency and a history of Burkitt lymphoma [12].

In 1981 Naranjo et al. described a method for estimating the probability of adverse drug reactions. This scale provides a better evaluation of a causal correlation between the vaccination and the adverse event. With using this method; our case score was eight and this score means there is a probably correlation between vaccination and adverse event [13].

Tetanus vaccination has previously been associated with development of mucous membrane pemphigoid. Sezin et al. reported mucous membrane pemphigoid (MMP) with erosions and oral and cutaneous blisters developing 2 days after diphtheria-tetanus vaccination in a 29-year-old patient. The relation with MMP and tetanus vaccination was thought to be coincidental. It was attributed to non-specific activation in the immune system or to structural similarity between the tetanus toxoid molecule and the laminin 332 subunit [14].

The relation between measles vaccination and PLEVA was attributed to antigenic stimulation and lymphoproliferative reaction stimulated in the skin. Viruses make the epidermis an antigenic target, and this cytotoxic reaction results in PLEVA. In contrast to measles vaccination, tetanus vaccination is not a live vaccination. Diphtheria-tetanus vaccination is a toxoid vaccination prepared by purifying inactive tetanus and diphtheria toxins. This is the first description of the tetanus vaccination PLEVA association. We think that this reaction can probably be added to the potential benign side-effects of the vaccination.

References

1. Gunatheesan S, Ferguson J, Moosa Y (2012) Pityriasis lichenoides et varioliformis acuta: a rare association with the measles, mumps and rubella vaccine. *Australas J Dermatol* 53: 76-78.
2. Khachemoune A, Blyumin ML (2007) Pityriasis lichenoides: pathophysiology, classification, and treatment. *Am J Clin Dermatol* 8: 29-36.
3. Neisser A (1984) Zur Frage der lichenoiden Eruptionen. *Verh. Dtsch. Dermatol* 4: 495-499.
4. Jadassohn J (1894) Ube rein eigenartiges psoriasisiformes und lichenoides Exanthem. *Verh. Dtsch. Dermatol* 4: 524-529.
5. Klein PA, Jones EC, Nelson JL, Clark RA (2003) Infectious causes of pityriasis lichenoides: a case of fulminant infectious mononucleosis. *J Am Acad Dermatol* 49: 151-153.

6. Zechini B, Teggi A, Antonelli M, Persechino S, Pranteda G, et al. (2005) A case report of pityriasis lichenoides in a patient with chronic hepatitis C. J Infect 51: 23-25.
7. Tomasini D, Tomasini CF, Cerri A, Sangalli G, Palmedo G, et al. (2004) Pityriasis lichenoides: a cytotoxic T-cell-mediated skin disorder. Evidence of human parvovirus B19 DNA in nine cases. J Cutan Pathol 31: 531-538.
8. González Rodríguez AJ, Montesinos Villaescusa E, Jordá Cuevas E (2012) Pityriasis lichenoides chronica associated with herpes simplex virus type 2. Case Rep Dermatol 2012: 1-2.
9. Fernandes NF, Rozdeba PJ, Schwartz RA, Kihiczak G, Lambert WC (2010) Pityriasis lichenoides et varioliformis acuta: a disease spectrum. Int J Dermatol 49: 257-261.
10. <http://www.uptodate.com/contents/tetanus-diphtheria-toxoid-vaccination-in-adults>.
11. Gil-Bistes D, Kluger N, Bessis D, Guillot B, Raison-Peyron N (2012) Pityriasis lichenoides chronic after measles-mumps-rubella vaccination. J Dermatol 39: 492-493.
12. Machan M, Loren R, Fraga G, Liu D (2012) Pityriasis lichenoides et varioliformis acuta associated with subcutaneous immunoglobulin administration. J Am Acad Dermatol 67: 151-152.
13. Naranjo CA, Busto U, Sellers EM, Sandor P, Ruiz I, et al. (1981) A method for estimating the probability of adverse drug reactions. Clin Pharmacol Ther 30: 239-245.
14. Sezin T, Egozi E, Hillou W, Avitan-Hersh E, Bergman R (2013) Anti-laminin-332 mucous membrane pemphigoid developing after a diphtheria tetanus vaccination. JAMA Dermatol 149: 858-862.