

Pigtail in Bronchus

Rajany V. Dy, MD

Department of Medicine: Division of Pulmonary, Critical Care and Sleep Medicine, University at Buffalo, USA

A 55-year-old male was admitted to the Intensive Care Unit for hypoxemic respiratory failure secondary to healthcare associated pneumonia. The patient had diffuse bilateral interstitial infiltrates on initial chest radiograph. Sputum cultures have been persistently negative and he remained ventilator dependent with high oxygen requirements despite treatment with broad-spectrum IV antibiotics for 2 weeks. He underwent an open lung biopsy of the right middle and lower lobe. Day 4 post-operatively, his pneumothorax has not resolved. A pigtail catheter was inserted into the anterior 2nd intercostal space without difficulty. Post procedure imaging showed the catheter crossing the lung parenchyma and extending into the right main bronchus. The pigtail catheter was immediately removed and a new chest tube was placed. Follow up imaging showed re-expansion of the right lung and his chest tubes were eventually removed. The lung biopsy results revealed acute and organizing diffuse alveolar damage. Supportive management was continued and he was eventually weaned to minimal ventilator settings (Figures 1-6).

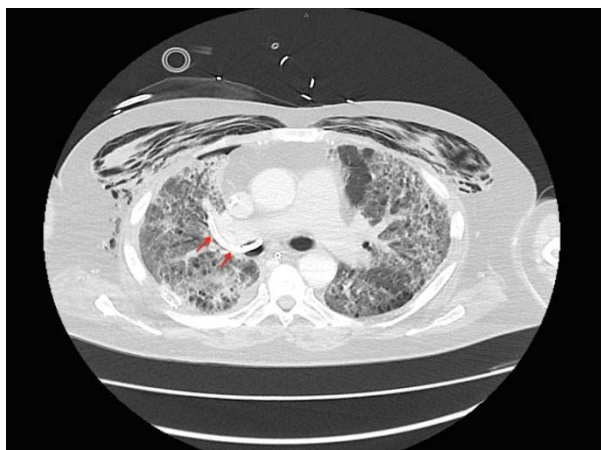


Figure 1: Chest CT (transverse view) showing pigtail in the right mainstem bronchus - with arrows.

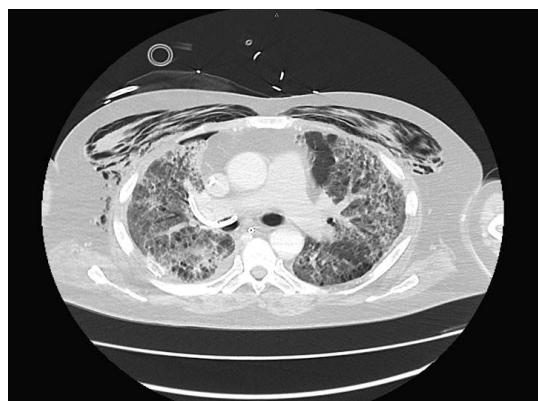


Figure 2: Chest CT (transverse view) showing pigtail in the right mainstem bronchus - without arrows.

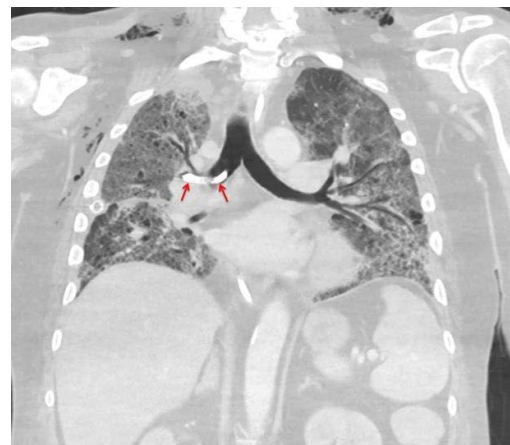

Figure 3: Chest CT (coronal view) showing pigtail in the right mainstem bronchus - with arrows.

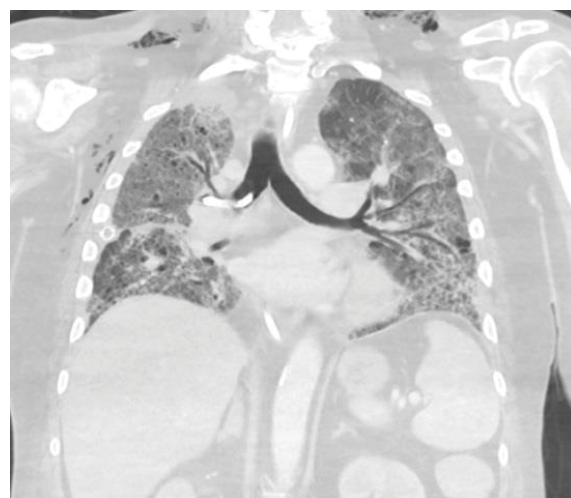

Figure 4: Chest CT (coronal view) showing pigtail in the right mainstem bronchus - without arrows.

***Corresponding author:** Rajany V. Dy, Pulmonary/Critical Care Medicine Fellow, State University of New York, Buffalo, USA, Tel: 203-802-8914; E-mail: rajanydy@buffalo.edu; rajany08@yahoo.com

Received August 11, 2015; **Accepted** August 14, 2015; **Published** August 18, 2015

Citation: Rajany VD (2015) Pigtail in Bronchus. J Pulm Respir Med 5: i09. doi:[10.4172/2161-105X.1000i020](https://doi.org/10.4172/2161-105X.1000i020)

Copyright: © 2015 Rajany VD. This is an open-access article distributed under the terms of the Creative Commons Attribution License, which permits unrestricted use, distribution, and reproduction in any medium, provided the original author and source are credited.

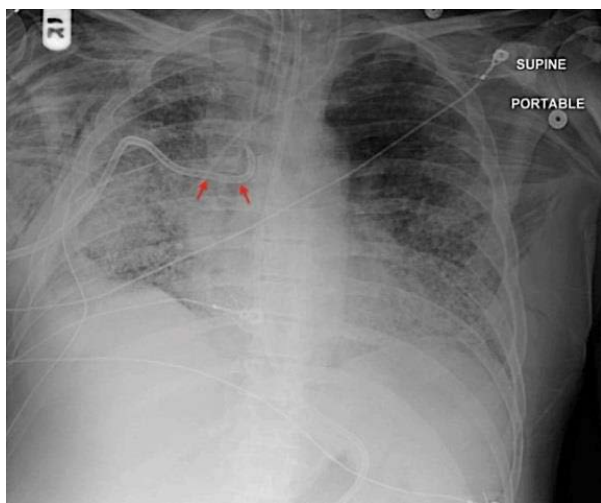


Figure 5: Chest X-ray showing pigtail in the right mainstem bronchus - with arrows.

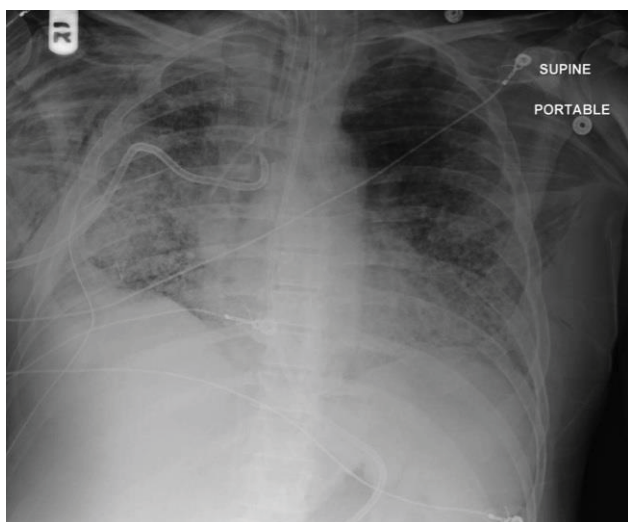


Figure 6: Chest X-ray showing pigtail in the right mainstem bronchus - without arrows.