

Pigmentary Disorders of Oral Mucosa

Patil S¹, Raj T¹, Rao RS¹ and Warnakulasuriya S^{2*}

¹Department of Oral Pathology and Microbiology, Faculty of Dental Sciences, M.S. Ramaiah University of Applied Sciences, Bangalore, India

²Department of Oral Medicine, Kings College London Dental Institute, WHO Collaborating Centre for Oral Cancer, London, UK

Abstract

Oral mucosa under physiological condition contains a certain degree of chromic variation. Differentiating such physiological variations from pigmented lesions appears challenging without a histopathological confirmation. In several oral lesions, pigmentation is a part of the primary pathology or a secondary change to an existing entity. The pigments involved in both physiological and pathological conditions can be broadly categorised as exogenous or endogenous. Among these, melanin accounts for the majority of black to brown pigmentation including malignant melanoma. Clinically, their biological behaviour shows an ambiguity which makes it challenging to arrive at diagnosis for even the experienced practitioner. Although biopsy confirms and reassures the patient, it is impractical to biopsy all pigmented lesions. The standard diagnostic algorithm given below is to aid the clinician to diagnose and treat this diverse group of lesions.

Keywords: Oral mucosa; Pigmented lesions; Diagnosis

Introduction

Intra oral pigmentations range from innocuous physiological pigmentations to life threatening lesions like malignant melanoma as illustrated in the flow chart 1. Oral pigmented lesions are often clinically deceptive in nature. It makes the provisional diagnosis quite challenging, mandating histopathological confirmation. But it is impractical to biopsy all pigmented lesions. It is at the clinician's discretion to note the subtle changes towards malignancy like sudden increase in size, colour change and any reported associated pain [1,2].

Controversies pertaining to its etiology, malignant potential and treatment protocol remain unaddressed. The following examples portray such controversies: Certain pigmented lesions tend to darken on exposure to sunlight, revealing that UV radiation plays a role in its pathogenesis. But intraoral pigmented lesions are not exposed to direct sunlight (exception: vermillion border of the lip) further complicating the debate as to its etiology. In most pigmented lesions the treatment is periodic observation until the vital structures get involved or raises an alarm to cosmetic concerns. Malignant melanoma is a lesion that often causes anxiety to patient and clinician alike due to its aggressive clinical course. Its clinical resemblance to benign pigmented lesions mandates a histopathological confirmation [3,4] (Figures 1-4).

The causative agents of pigmented lesions can be broadly classified as exogenous or endogenous based upon their origin as illustrated in Tables 1 and 2.

The endogenous agents comprise primarily of bodily pigments, of which melanin is focal to most black/brown pigmentations. Normally melanin is secreted by the melanocytes which reside in the basal layer of the epithelium among the keratinocytes. After its biosynthesis in melanocytes, melanin is transported to the keratinocytes through dendritic processes. The melanin is transported in membrane bound vesicles called melanosomes in a process called apocoptation [5-7]. The pathogenesis of oral melanocytic lesions can be broadly divided into three categories.

Melanotic lesions follow one of the following mechanisms

- Excessive production of melanin. Eg: Melanotic macule
- Abnormal distribution of melanin. Eg: pigmented basal cell carcinoma,
- Hyperplasia or neoplasia of melanocytes. Eg: Melanotic nevi

Apart from melanin, haematogenous pigments (haemosiderin) play a role in the pathogenesis of a number of red-blue lesions of the oral cavity. Among the exogenous lesions, amalgam tattoo represents the most common entity, leaving behind an imprint of amalgam in the attached gingiva or the buccal mucosa in relation to the restored tooth.

Physiological Pigmentation (racial pigmentation)

Physiologic pigmentation has no gender predilection and presents within the second decade of life. A predilection towards people of African, Asian and Mediterranean origin is often noted. Attached gingiva represents the most common intraoral pigmented site.

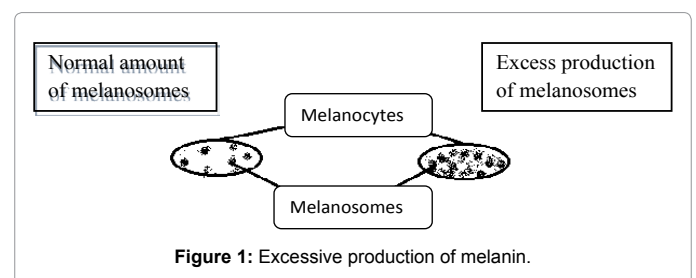


Figure 1: Excessive production of melanin.

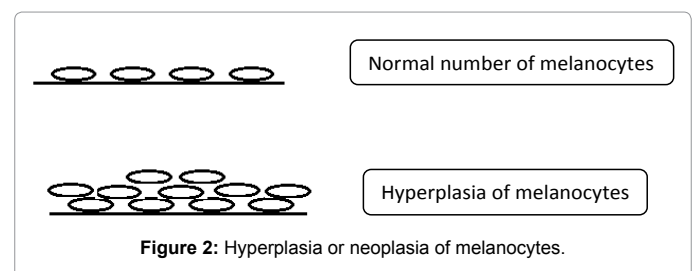


Figure 2: Hyperplasia or neoplasia of melanocytes.

***Corresponding author:** Warnakulasuriya S, Department of Oral Medicine, Kings College London Dental Institute, WHO Collaborating Centre for Oral Cancer, London, UK, Tel: +4402071887188; E-mail: saman.warne@kcl.ac.uk

Received October 02, 2015; Accepted November 13, 2015; Published November 20, 2015

Citation: Patil S, Raj T, Rao RS, Warnakulasuriya S (2015) Pigmentary Disorders of Oral Mucosa. Pigmentary Disorders 2: 225. doi:10.4172/2376-0427.1000225

Copyright: © 2015 Patil S, et al. This is an open-access article distributed under the terms of the Creative Commons Attribution License, which permits unrestricted use, distribution, and reproduction in any medium, provided the original author and source are credited.

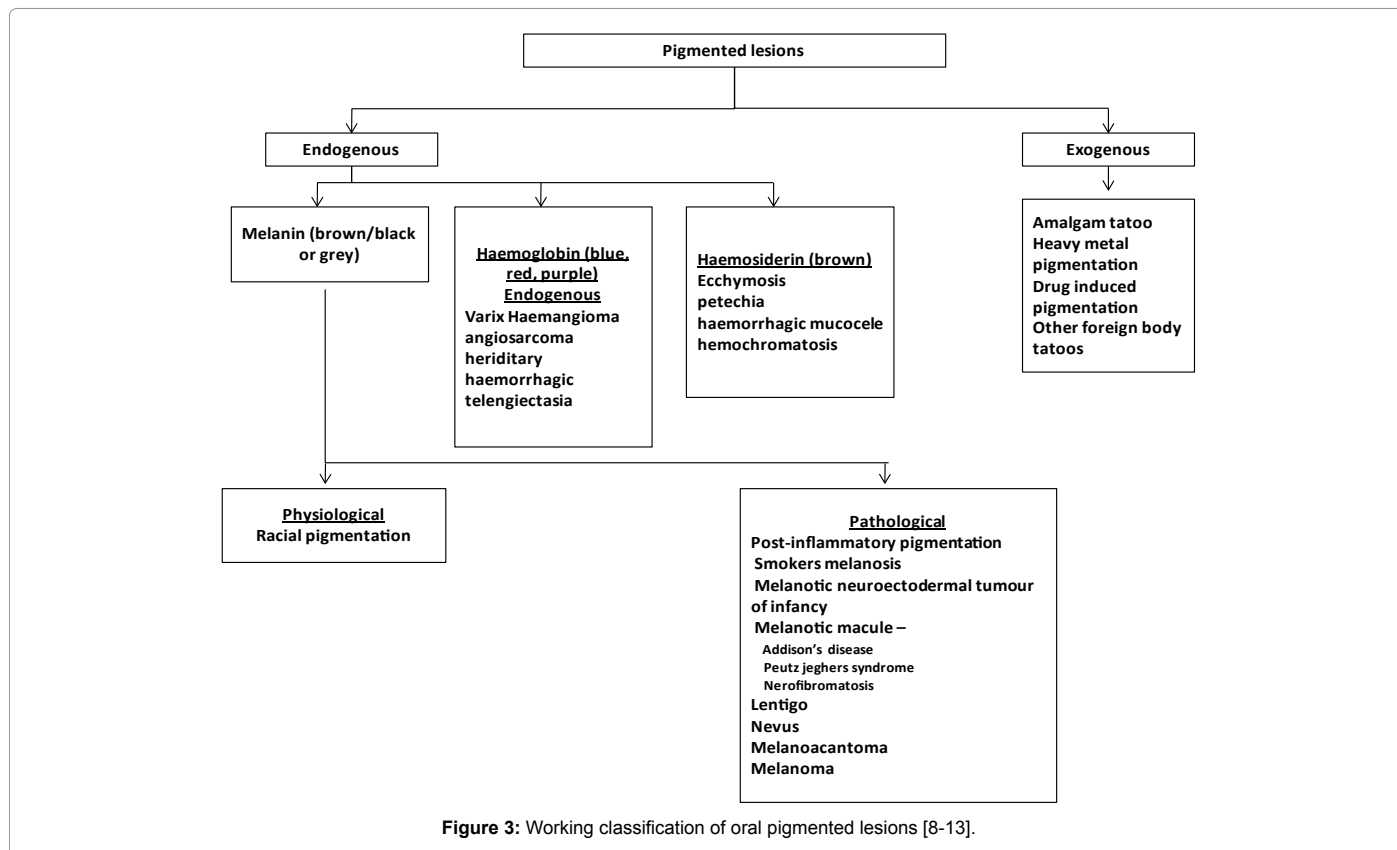
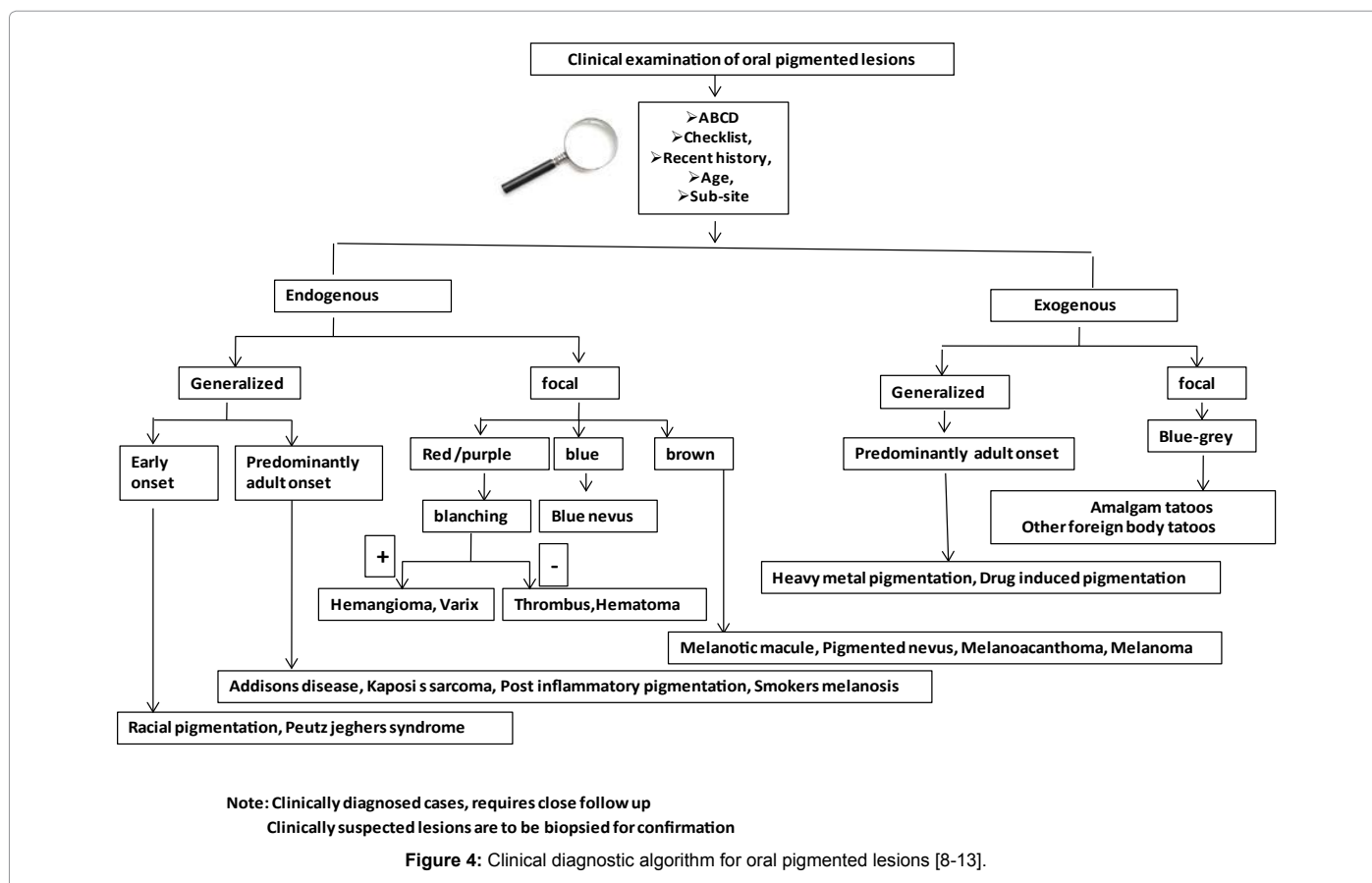


Figure 3: Working classification of oral pigmented lesions [8-13].



Note: Clinically diagnosed cases, requires close follow up
Clinically suspected lesions are to be biopsied for confirmation

Figure 4: Clinical diagnostic algorithm for oral pigmented lesions [8-13].

Pigment	Colour	Pigmented lesions
Haemoglobin	Blue, red, purple	Varix, Haemangioma, angiosarcoma, hereditary haemorrhagic telangiectasia
Haemosiderin	Brown	Ecchymosis, petechia, haemorrhagic mucocele, hemochromatosis
Melanin	Brown, black or grey	Melanotic macule, nevus, melanoma, basilar melanosis with incontinence

Table 1: The endogenous agents for pigmentation.

Source	Colour	Clinical presentation/etiology
Silver amalgam	Grey, black	Tattoo/ iatrogenic trauma
Graphite	Grey, black	Tattoo/ trauma
Lead, mercury, bismuth	Grey	Ingestion of paint or medicine

Table 2: The exogenous agents.

Other less common sites include hard palate, lips and tongue. There is no change in the architectural features (eg:gingival stippling). Pigmentation is due to an increased production of melanin. Racial pigmentations are predominantly symmetrical and are prevalent throughout life. Addison's disease, Peutz-Jeghers syndrome, smoker's melanosis and melanoma are lesions to be differentiated. A biopsy usually confirms atypical clinical presentation. No treatment is required unless the patient has cosmetic concerns, in which case depigmentation procedures are carried out [8-14].

Key features facilitating diagnosis of benign pigmentary disorders

- Symmetrical presentation
- Prevalent throughout life
- Predominantly sited in the attached gingiva

Pathological Pigmentation

These include both benign and malignant pigmented lesions:

Post inflammatory pigmentation

This type of pigmentation is commonly seen in chronic inflammatory lesions of oral mucosa like lichen planus, pemphigus and pemphigoid. Characteristic features of these lesions include, white stria seen overlapping the pigmented areas or *vice versa* (pigmented reticular lichen planus). The pathogenesis involves increased melanin production, with subepithelial lymphocytic infiltration. Microscopically, characteristic features of lichen planus (lichen planus nigricans) along with basal melanosis, melanin drop-out, and melanophages in the subepithelial connective tissue are noted. As the underlying inflammatory process resolves, so does the pigmentation [15-21].

Key features facilitating diagnosis

- Predominantly associated with chronic oral inflammatory lesions
- Microscopically lichen planus nigricans shows basal melanosis with lymphocyte infiltration

Smoker's melanosis / Smoking associated melanosis

Oral melanosis is seen associated with about 21.5% of smokers. The lesions vary from light to dark brownish macules, often noted in the anterior labial gingiva. Hard Palate and buccal mucosa are affected in pipe smokers. Smokeless tobacco alone is not associated with oral melanosis, but cases have been reported where both tobacco and alcohol were used. It has a female predilection, especially in pre-menopausal

women, users of oral contraceptives and smokers, indicating a possible relation between female sex hormone, smoking and melanosis. Although the source is unknown, tobacco and the heat generated during smoking are associated with the increased production of melanin. Melanophages are noted in the sub-epithelial connective tissue. The lesion is benign with no reported case of malignant transformation. No treatment is advised unless there is a cosmetic concern. In most cases cessation of smoking reverses the lesion [22].

Key features facilitating diagnosis:

- History of smoking
- Pre-menopausal women, women on contraceptives with smoking habit
- Cessation of smoking may resolve the lesion.

Melanotic neuroectodermal tumour of infancy (MNTI)

Melanotic neuroectodermal tumour arises in infants less than 6 months of age but is not congenital. The tumour is benign and is of neuroectodermal origin. The pathogenesis involves failure of the neuroectodermal cells to involute. Anterior maxilla is the most common site, followed by anterior mandible, skull, scapula and epididymis. The lesion appears as an ill defined bluish gingival mass, often mistaken to be an eruption cyst. The tumour is often associated with either of the central incisor (strictly unilateral). "Candle in a cupcake" is a term used to describe the appearance of the central incisor within the tumour. There is no radioopacity other than the embedded tooth. The typical radiological feature involves gross destruction of the involved bone with peripherally displaced tooth. Histological diagnosis is mandatory to rule out malignant lesions like neuroblastoma. There are numerous tumour islands lined peripherally by large cuboidal cells with pale nucleus and abundant cytoplasm containing melanin. Centrally located cells are smaller, with darker nucleus and scanty cytoplasm resembling neuroblast. Both types of cells are positive for neuron specific enolase and synaptophysin but negative for S-100. The larger cells are positive to HMB-45 (Huma melanocyte black) and to cytokeratin. There have been reports of malignant MNTI's, but they are more likely misdiagnosed cases of neuroblastomas. Neuroblastoma, hemangioma, lymphangioma and granular cell tumour, of which the latter is strictly congenital, should be considered in the differential diagnosis. A clear history (onset) would aid in the final diagnosis. Peripheral resection with 2 to 5 mm margins is the standard treatment protocol. If any MNTIs show recurrence or malignant transformation, an interim diagnosis of unrecognized malignancy should be considered, and further investigation should be carried out. Prognosis is good if resection is carried out early, avoiding gross resorption of the involved site. Orthodontic treatment or surgery may be required with speech therapy to aid in recovery [9-13].

Key features facilitating diagnosis

- Commonly seen in infants less than 6 months of age (not congenital)
- Presents as ill defined bluish gingival mass
- Candle in a cupcake appearance is pathognomonic
- Histopathology shows neuroblasts and melanocyte like cells

Oral melanotic macule

A melanotic macule, unlike ephelide (freckles) does not darken on exposure to sunlight. The lesion is considered to be benign. Presents as flat brownish patch measuring few millimeters to 1 cm. Familiar sites

include the vermilion border of lip and attached gingiva. Pathogenesis involves an increased production of melanin by mature melanocytes. Differential includes melanoma, amalgam tattoo, melanotic nevi and focal ecchymosis. Melanoma in early stages appears homogenous resembling a melanotic macule. A biopsy is necessary in cases of atypical presentation to rule out malignancy [9,10]

Key features facilitating diagnosis:

- Commonly associated with endocrinal disorders
- Preferred site includes vermilion border of lip and attached gingiva
- Is homogenous in appearance
- Does not show rapid growth, often stable in size

Systemic Conditions Associated with Oral Melanotic Macule

Patients presenting with multiple skin, oral and perioral pigmented macules should be suspected for associated systemic disorders (endocrinopathy).

Peutz Jegher's syndrome

Inherited in an autosomal dominant pattern associated with mutations in STK11/LKB1 gene on 19 p 13.3. Apart from the macular patches, around the lips, the patients may complain of abdominal pain, rectal bleeding due to intestinal polyps with a potential for malignant transformation. There is also an increased risk of malignant transformation of internal organs like gastrointestinal tract, pancreas, breast and thyroid. The melanotic macules may be present in other body parts including extremities, rectum, intranasal mucosa and conjunctiva [9,23].

Addison's disease

This is due to adrenocortical insufficiency. It may be due to destruction of adrenal cortex by infections like tuberculosis, autoimmune diseases, malignancy or any other idiopathic process. As a response to the low level of cortisol, there is an increased production of Adrenocorticotropin hormone (ACTH) from neurohypophysis. ACTH increases secretion of melanocyte stimulating hormone leading to increased production of melanin. Other symptoms include fatigue, weakness, orthognathic hypotension. Measuring levels of ACTH (Synthectin Test) and plasma cortisol will aid in diagnosis [24,25].

Cushing's syndrome

It is caused due to increased activity of the adrenal cortex. It may be due to adrenal hyperactivity or increased amount of ACTH. The former is due to an adenoma of the adrenal cortex or any other disease process which increases the cortisol level. Prolonged steroid therapy may lead to Cushing's. The latter exhibits increased secretion of melanocyte stimulating hormone. Other symptoms include hypertension and hyperglycemia

In both Addison's disease and Cushing's syndrome along with the oral and perioral melanotic macules, there is bronzing of the skin due to generalized cutaneous pigmentation. The pigmentation disappears as the endocrinopathy is resolved. Other endocrine disorders with oral pigmentation includes McCune-Albright syndrome, hyperthyroidism and Nelson's syndrome [9-12].

Cafe' au lait macules

The colour of the macule is similar to coffee with cream. It is seen

in many endocrinopathies including McCune Albright syndrome, Addisons disease, Cushing's syndrome and neurofibromatosis [9-11].

Neurofibromatosis (NF)

It has an autosomal dominant inheritance. The two major types are NF1 and NF2. NF1 also called as Von Recklinghausen's disease is commonly associated with cafe' au lait macules apart from neurofibromas of the skin, oral mucosa, and central nervous system and occasionally jaw involvement is also noted. Presence of axillary freckling (Crowe's sign) along with six or more macules is pathognomonic of NF1 [26,27].

The pigmented macules of all the above mentioned endocrine disorders show similar histopathological features: Increased basilar melanosis with melanophages in the subepithelial connective tissue with no apparent increase in the number of melanocytes.

Other Syndromes/Conditions Associated with Melanotic Macules

Laugier hunziker syndrome

Macular pigmentation, predominant in the lips. Histopathology includes epithelial basal cell melanosis with numerous melanophages in the subepithelial connective tissue [28].

Oral melanotic macules associated with HIV infection

HIV sero positive patients have two fold higher risk of developing melanotic macule. Also the number of macules increases as the infection progresses. There is also a marked increase in the recurrence rate. The recurring macule appears to be larger than its predecessor [29].

Lentigo

Actinic lentigo is a benign brown macule found in those regions exposed to sunlight (UV radiation). Labial lentigo, a subtype of lentigo presents in the vermilion border of the lip [9,10].

Melasma

Results from hormonal fluctuation (pregnancy) [9] and affects facial skin.

Lesions with Proliferation of Melanocytes

Lentigo simplex

Clinically differs from labial lentigo by presenting in regions unexposed to sunlight. There is an increase in the number of melanocytes. The etiology is unclear. The lesion presents as a well demarcated brownish macule not exceeding few millimetres. Develops predominantly during childhood [9,10].

Oral melanotic nevus

The clinical features include brownish black to blue elevated papules with a well defined border. Nevi can be classified based on time of occurrence as congenital and acquired. Congenital nevi, can be sub-classified as giant nevus (giant hairy nevus, bathing trunk nevus, garment nevus-larger than 20 cm) and small nevus(less than 1.5 cm). An acquired nevus is also called as a mole, occurs most commonly in the sun exposed regions. In the oral cavity, hard palate is the most predominant site of occurrence. Nevus represents a benign proliferation of melanocytes. Based on histology, oral nevi are classified as junctional, compound and intramucosal nevi. The various histopathological types

of nevi represent the progressive phases of the nevi. In the initial phase, melanocyte proliferation is near the epithelial- connective interface (junctional nevi). In the subsequent phase, the proliferation continues at the interface & also involves the underlying connective tissue (compound nevi). In the advanced phase, proliferating cells migrate completely into the connective tissue (intramucosal nevi). Concurrent with the above theory intramucosal nevi are reported only in adults (advanced phase). If there is evidence of junctional activity in an adult nevus, the probability of malignant transformation should be considered and a close follow up is required. Junctional nevus is black in colour due to their superficial presence. As the proliferating cells move deeper, the nevus lightens in colour [9,30,31].

Blue nevus

Appears blue due to their deep location. Histologically, they have numerous dendritic spindle shaped cells with melanin pigment. Also the nerves and blood vessels could harbour melanin. Melanophages are a common finding. Cellular blue nevus, a variant of blue nevus, contains two population of cells- spindle cell variety containing melanin and larger cells with pale cytoplasm containing little or no melanin. Cellular blue nevus has a higher risk of malignant transformation. Blue nevus should be differentiated from melanoma. Close follow up is advised to rule out malignant transformation [9,10,30,31].

Key features facilitating diagnosis:

- Occurs as brownish black to blue elevated papules with well defined border.
- Preferably noted on sun exposed areas of the oral cavity.

Melanoacanthoma

Clinically, it appears as a brown to black slightly raised lesion, predominantly present in the buccal mucosa. Less common sites include the lip, gingiva. Sudden increase in size is a classic feature and should not be mistaken for melanoma. It is characterised by numerous benign dendritic melanocytes scattered throughout the lesional epithelium. Spongiosis and acanthosis may be noted. The lesion has a tendency to regress after incisional biopsy or after the offending stimulus is removed [32,33].

Key features helpful in diagnosis:

- Predominantly presents as a black nodular lesion in the buccal mucosa.
- Rapid increase in size
- Removal of stimulus reverts the lesion

Oral Mucosal Melanoma

Malignant melanomas represent less than 1% of oral malignancies. The incidence of mucosal melanoma increases with age. It has a male predilection. Hard palate (40%) followed by labial gingiva (30%) are the most common site of occurrence. Intra oral melanoma exclude the etiology of UV light which is true for cutaneous melanoma. The most common aetiology proposed for cutaneous melanoma, which is the UV radiation, cannot be related to oral mucosal melanoma due to its location. Microscopically there is a proliferation of pleomorphic cells with dense melanin pigmentation in its cytoplasm, initially in the epithelial - connective tissue junction (radial growth phase), at later stages the proliferation extends in to the superficial connective tissue and progresses in to the deeper structures (vertical growth phase). Most cases of mucosal melanomas have a radial growth phase, wherein

the proliferation is restricted to the basal layer. Clinically presents as pigmented patch. As the vertical phase sets in, the lesion turns nodular. Most cases of melanoma are diagnosed at the vertical growth phase, which carries a poorer prognosis (higher metastatic risk). Not all cases of malignant melanoma exhibit a predominant radial (horizontal) growth phase. In certain cases the vertical growth phase may set in earlier, which makes diagnosis and treatment time restrained.

The clinician should note the subtle changes (ABCD's) in the pigmented lesion: Asymmetry, irregular Borders, colour changes, sudden increase in Diameter. Apart from these changes any bleeding, ulcerations, pain and associated bone destruction may favour a diagnosis of melanoma. Several recent immunohistochemical markers have shown high sensitivity and specificity for malignant melanoma which are summarised in Table 3. There have been reported cases of a non-pigmented variety of melanoma called amelanotic melanoma. Amelanotic melanoma may mimic a vascular or a fibrous lesion clinically leading to delayed diagnosis and treatment. Treatment involves wide excision with clear margins. A wide excision may not always be possible due to the close proximity of vital structures. Though rare, it has a poorer prognosis than its relatively common cutaneous counterpart due to the following reasons: absence of papillary dermis, reticular dermis and relatively thin submucosa. The above reasons increase the rate of vertical growth, worsening the prognosis. The 5 year survival rate of a malignant melanoma is 15%, which is considerably lower than its cutaneous counterpart [9,10,34-38].

Key features facilitating diagnosis

- Incidence increases with age and has a male predilection
- Sited commonly on hard palate (40%) followed by labial gingival (30%)
- Progresses from macular to nodular lesion
- Shows signs of malignant transformation (ABCD).

Vascular: (blue, red, purple)

Varix and thrombus: Varix is a pathological focal dilatation of vein or a group of veins due to the weakening in the vessel wall

Marker	Function
S-100	21kDa acidic calcium binding protein
HMB-45	Marker for cytoplasmic premelanosomal glycoprotein gp100
MART-1 (Melanoma antigen recognised by T cells)/ Melan A	Cytoplasmic protein of melanosomal differentiation recognised by T-cells
MITF (Microphthalmia transcription factor)	Development of melanocytes during embryogenesis
NKI/C3	25–110 kD glycoprotein located on the inner membrane of cytoplasmic vesicles in melanocytes
Multiplemeloma-1 (MUM-1)	Protein with a role in regulating gene expression in response to cytokines
Melanocortin-1	Receptor for alpha-melanocyte stimulating hormone present on melanocytes
SM5-1	Monoclonal antibody developed from mice immunized with the melanoma cell line SMMU
PNL2	Uncharacterized antibody found to react with 33 of 38 metastatic melanomas.
TRP-1 and TRP-2	New antibodies to tyrosinase that are under investigation.

Table 3: Immunohistochemical markers with increased expression for malignant melanoma [59].

(degeneration of adventitia layer) due to trauma (lip biting, cheek biting). Ventrolateral surface of the tongue and lower lip in the elderly are the most common sites of occurrence. There is no known clinical implication as they rarely rupture or bleed. A varix normally undergoes blanching, but it may contain a thrombi, in which case blanching is absent. Though asymptomatic, if mastication is affected, local excision or use of sclerosing agent (sodium tetradecyl sulphate) will provide relief [39,40].

Key features facilitating diagnosis:

- Commonly located on ventrolateral surface of the tongue and lower lip.
- Common among the elderly
- Asymptomatic and blanches on pressure

Hemangioma

It is a form of vascular hamartoma. Tongue and lower lip are the most commonly affected sites intraorally. They may be macular or tumefactive. The most common form is Port Wine stain. It is seen as a macular patch with magenta colour on the facial skin. These may extend in to the oral cavity. Hemangiomas are developmental anomalies that arise during childhood (infancy). Hemangiomas can be microscopically classified into two types:

1. Cellular (Capillary) hemangioma

Consists of vascular channels with small lumen accompanied by significant proliferation of endothelial cells [41,42].

2. Cavernous hemangioma

Consists of large dilated vascular channel with endothelial cells [43].

Key features facilitating diagnosis:

- Congenital
- Blanching on pressure
- Commonly sited on tongue and lower lip
- Regresses over a period of time

The Distinguishing Feature between Varix and Hemangioma are as follows

Hemangiomas are usually congenital or develop during childhood. Aetiology of hemangioma is unknown, whereas varix, occur following trauma (weakening of the vessel wall). Hemangiomas may show regression over a period of time, especially in the case of children.

Angiosarcoma

Clinical feature includes red/blue/purple nodular growth. Exhibits rapid proliferation. It is a malignant neoplasm of endothelial cells of blood or lymph vessels. Unlike Kaposi's sarcoma, angiosarcoma is not related to the human immunodeficiency virus (HIV). Though occurrence in oral cavity is rare, it is fatal & treatment involves radical resection [44,45].

Key features facilitating diagnosis

- Appears as red/blue/purple nodule.
- Proliferative nature.

Hereditary hemorrhagic telangiectasia (Osler-Rendu-Weber disease)

Autosomal dominant inheritance. Multiple papules representing micro aneurysms are pathognomonic of the lesion. Papules may extend to the face, neck, nasal mucosa leading to epistaxis. The underlying pathogenesis involves a weakening of the adventitia layer of venule wall. Vermilion border and mucosal surface of the lip, tongue, buccal mucosa are the commonly affected sites intraorally. Rare case reports of death due to profuse bleeding are recorded. Petechia are due to blood dyscrasias (platelet disorder) should be distinguished from telangiectasias. A complete blood picture is confirmative. The telangiectatic papules are purple in colour, whereas the petechia is red/brown due to the breakdown of RBCs releasing haemosiderin. Microscopically multiple dilated vessel with extravasated red blood cells are seen. The treatment involves cosmetic removal of the papules by electrocautery [46,47].

Key features facilitating diagnosis:

- Micro aneurysms are pathognomonic in nature.
- Epistaxis is common.

Kaposi's Sarcoma

Associated with HIV sero positive individuals. Presents initially as a multifocal red to purplish macular lesions, commonly affecting hard palate and gingiva (intraorally). The initial red macular lesion, becomes tumefactive with a colour change (turns brown) as the extravasated RBCs, are broken down to hemosiderin pigments. The lesion may ultimately ulcerate, bleed or turn necrotic. Microscopically pleomorphic spindle cell proliferation is seen surrounding blood vessels with plump endothelial cells and extravasated RBCs. Presence of Kaposi's sarcoma, with seropositivity in an HIV patient is indicative of progression to AIDS (auto immune deficiency syndrome) [48-50].

Key features facilitating diagnosis:

- Predominantly associated with HIV positive individuals
- Presents as multifocal red to purplish macular lesions
- Hard palate and gingiva are commonly affected.

Extravascular (Heme) related oral pigmentations

Ecchymosis: Common intra-oral sites include cheek, lip and tongue (sites prone to trauma). Initial presentation is a macular red patch. Browning tan may appear at later stage due to the breakdown of haemoglobin to haemosiderin. The macular patch may become tumefactive if a haematoma forms. Apart from trauma, other underlying coagulopathies or anticoagulant therapies may result in petechial haemorrhage. The mechanism involves leakage of blood in to the submucosa following injury. An estimation of prothrombin time for extrinsic and partial thromboplastin time for intrinsic pathways may confirm the diagnosis in cases of unprovoked ecchymosis. An increased clotting time is not uncommon in these cases. Following trauma the ecchymosis (macular patch) should resolve within 2 weeks [51].

Key features facilitating diagnosis:

- Common sited on cheek, lip, tongue
- Progresses from macular red patch to a brownish tanned lesion
- Resolves within 2 weeks following the trauma

Petechiae

Associated with autoimmune disorders or HIV associated Idiopathic thrombocytopenic purpura, platelet aggregation disorders, aspirin toxicity, myelophthistic lesions and myelosuppressive chemotherapy etc). Oral lesions manifest as red to blue discoloration. As the RBCs breakdown releasing hemosiderin a brownish tinge is added to the lesion. Soft palate is most affected, presenting with multiple petechial spots. The underlying pathology intra-orally could be due to constant clicking or suction of the tongue against the soft palate (suction petechiae) due to allergic or pruritic nature of the soft palate in response to viral infections. Treatment of the underlying infection will resolve the lesion [51].

Key features facilitating diagnosis:

- Predominantly associated with puritic infection
- Commonly sited on the soft palate

Haemochromatosis

It involves the deposition of haemosiderin in multiple organs. The underlying pathology may range from primary heritable disease to secondary conditions following chronic anemia, porphyria, cirrhosis, postcaval shunt for portal hypertension, and excess intake of iron. Microscopically apart from increased deposition of iron, there may be associated basal melanosis. Excessive melanin production is in response to ACTH (adrenocorticotropin hormone) hypersecretion, which in turn is due to haemosiderin deposition within the adrenal cortex resulting in hypocorticism. A biopsy can be confirmatory. The excess iron deposition can be demonstrated by Prussian blue [52].

Key features helpful in diagnosis:

- Multiple intraoral sites are affected
- Increased iron levels
- Positive for Prussian blue.

Exogenous

Amalgam tattoo: It is the most common exogenous source of focal pigmentation in the oral cavity. Gingiva, alveolar mucosa and buccal mucosa which are in close proximity to an amalgam restoration are commonly affected sites. The mechanism involves iatrogenic implantation of amalgam particles during amalgam restoration, removal or post extraction amalgam tattoo can get implanted in to the socket. If the amalgam particles are large, radiographic demonstration is possible. Histopathology reveals deposition of amalgam in the sub epithelial connective tissue, especially around the blood vessels. No treatment is necessary as there are no clinical implications [9,53].

Key features facilitating diagnosis:

- History of amalgam restoration
- Amalgam particles can be visualised in a radiograph.

Heavy metal pigmentation

Industrial workers are often exposed to arsenic, bismuth, platinum, mercury and lead. Previously some heavy metals were part of treatment modality (Cis – platinum-antineoplastic activity, arsenic and bismuth compounds were used to treat diseases such as syphilis, lichen planus and other dermatoses). The incidence of heavy metal pigmentation has been considerably reduced as most of these ancient treatment modalities are no longer followed. Strict measures are implemented

in the industries to minimize heavy metal exposure. Intra orally heavy metals form a linear line along the gingival margin. (eg: burtonian line-lead) [9,10].

Key features facilitating diagnosis:

- History of heavy metal poisoning
- Characteristically a linear line along the gingival margin is seen

Drug induced pigmentation

Most commonly involved drugs causing pigmentation are as follows: Drugs like Quinoline, hydroxyquinoline, amodiaquine – antimalarials and Minocycline used in the treatment of acne. Clinically greyish black macular deposits are observed throughout the mouth, predominantly in the hard palate. The pathogenesis behind drug induced pigmentation ranges from stimulation of melanocytes to direct deposition of the drug or its metabolites. Treatment protocol includes depigmentation procedure and replacement of the drug following consultation from the physician [54-56].

Key features facilitating diagnosis:

- History of drug intake
- Multiple oral sites affected

Other foreign body tattoos

Graphite tattoo represents black or grey macular patch in the anterior palate of young children. No treatment is necessary, but any atypical features should be biopsied to exclude melanoma [57].

Key features facilitating diagnosis:

- History of trauma from a lead pencil

Black hairy tongue

Profound use of antibiotic or antiseptic mouth rinses and smoking are associated risk factors in the proliferation of chromogenic bacteria, which in addition to food debris leads to the pigmentation of filliform papillae on the dorsum of the tongue [58,59].

Key features facilitating diagnosis

- History of antibiotic mouth rinses.

Conclusion

To summarise, in clinical practice the most importance distinction to be made in oral pigmented lesions is with a malignant melanoma. In most cases, oral malignant melanomas are preceded by macular pigmentation which may last from months to years. Invariably most melanomas are diagnosed in their advanced stages which can be attributed to the fact that a standard diagnostic algorithm is not available. Although various diagnostic modalities are available, a thorough clinical examination and histopathological confirmation remains the gold standard for oral pigmented lesions. A clinical diagnostic algorithm for oral pigmented lesions is illustrated in flow chart 2.

References

1. De Luca M, D'Anna F, Bondanza S, Franzi AT, Cancedda R (1988) Human epithelial cells induce human melanocyte growth in vitro but only skin keratinocytes regulate its proper differentiation in the absence of dermis. *J Cell Biol* 107: 1919-1926.
2. Bologna JL, Orlov SJ (2003) *Melanocyte biology*. *Dermatology*. (2nd edn), London.

3. Barrett AW, Scully C (1994) Human oral mucosal melanocytes: a review. *J Oral Pathol Med* 23: 97-103.
4. (2008) Decision Tree for Oral Mucosa Lesions. University of Iowa, College of Dentistry.
5. Miller CT, Beleza S, Pollen AA, Schluter D, Kittles RA, et al. (2007) cis-Regulatory changes in Kit ligand expression and parallel evolution of pigmentation in sticklebacks and humans. *Cell* 131: 1179-1189.
6. Manceau M, Domingues VS, Linnen CR, Rosenblum EB, Hoekstra HE (2010) Convergence in pigmentation at multiple levels: mutations, genes and function. *Philos Trans R Soc Lond B Biol Sci* 365: 2439-2450.
7. Videira IF, Moura DF, Magina S (2013) Mechanisms regulating melanogenesis. *An Bras Dermatol* 88: 76-83.
8. Eversole LR (2003) Pigmented lesions of the oral mucosa. *Burket's oral medicine diagnosis & treatment*. (10thedn), Spain.
9. Kautzman A, Pavone M, Blanas N, Bradley G (2004) Pigmented lesions of the oral cavity: review, differential diagnosis, and case presentations. *J Can Dent Assoc* 70: 682-683.
10. Marx, RE, Stern, D (2003) *Oral and Maxillofacial Pathology: A Rationale For Diagnosis And Treatment*. Quintessence Publishing Co, India.
11. Cawson RA, Odell EW (2002) *Cawson's Essentials of Oral Pathology and Oral Medicine*. (7th edn), Churchill Livingstone, London.
12. Rajendran R Sivapathasundaram B (2012) *Textbook of Oral Pathology*. (7th edn) Elsevier, India.
13. Neville B, Damm DD, Allen CM, Bouquet (2009) *J Oral and Maxillofacial Pathology*. (3rd edn), India.
14. Talebi M, Farmanbar N, Abolfazli S, Sarraf Shirazi A (2012) Management of physiological hyperpigmentation of oral mucosa by cryosurgical treatment: a case report. *J Dent Res Dent Clin Dent Prospects* 6: 148-151.
15. Mobio S, Noujeim Z, Boutigny H, Jensen M, Cassia A, et al. (2008) [Pigmentation and pigmented lesions of the gingival mucosa]. *Rev Belge Med Dent* (1984) 63: 15-28.
16. Amir E, Gorsky M, Buchner A, Samat H, Gat H (1991) Physiologic pigmentation of the oral mucosa in Israeli children. *Oral Surg Oral Med Oral Pathol* 71: 396-398.
17. Dummett CO (1945) Clinical observation on pigment variations in healthy oral tissues in the Negro. *J Dent Res* 24: 7-13.
18. Tamizi M, Taheri M (1996) Treatment of severe physiologic gingival pigmentation with free gingival autograft. *Quintessence Int* 27: 555-558.
19. Grande R, Gutierrez E, Latorre E, Arguelles F (1994) Physiological variations in the pigmentation of newborn infants. *Hum Biol* 66: 495-507.
20. Mergoni G, Ergun S, Vescovi P, Mete Ö, Tanyeri H, et al. (2011) Oral postinflammatory pigmentation: an analysis of 7 cases. *Med Oral Patol Oral Cir Bucal* 16: e11-14.
21. Anjum R, Singh J, Kudva S (2012) A clinicopathological study & probable mechanism of pigmentation in oral lichen planus. *World J Dent* 3: 330-334
22. Tadakamadla J, Kumar S, Nagori A, Tibdewal H, Duraiswamy P, et al. (2012) Effect of smoking on oral pigmentation and its relationship with periodontal status. *Dent Res J (Isfahan)* 9: S112-114.
23. Suresh KV, Shenai P, Chatra L (2011) Peutz-Jeghers Syndrome: In Siblings with Palmer-Plantar Pigmentation. *Journal of Indian Academy of Oral Medicine and Radiology* 23: 68-72.
24. Lanza Inam Heulf A, Perillo L, Dell'Ermo A, Cirillo N (2009) Oral Pigmentation as a Sign of Addison's Disease: A Brief Reappraisal. *The Open Dermatology Journal* 3: 3-6.
25. Shah SS, Oh CH, Coffin SE, Yan AC (2005) Addisonian pigmentation of the oral mucosa. *Cutis* 76: 97-99.
26. Khan M, Ohri N (2011) Oral manifestations of Type Neurofibromatosis in a family. *J Clin Exp Dent* 3: e483-486.
27. Munhoz EA, Cardoso L, Tolentino, Centurion S, Gonçalves ES, et al. (2010) Von Recklinghausen's Disease - Diagnosis from Oral Lesion. *Neurofibromatosis. Int. J Odontostomat* 4: 179-183.
28. Montebugnoli L, Grelli I, Cervellati F, Misciali C, Raone B (2010) Laugier-hunziker syndrome: an uncommon cause of oral pigmentation and a review of the literature. *Int J Dent* 2010: 525404.
29. Ficarra G, Shillitoe EJ, Adler-Storthz K, Gaglioti D, Di Pietro M, et al. (1990) Oral melanotic macules in patients infected with human immunodeficiency virus. *Oral Surg Oral Med Oral Pathol* 70: 748-755.
30. Beena, Isha Chauhan, Heera, Rajeev (2010) Oral melanotic nevi: a case report and review of literature *OMP J* 1: 1-7.
31. Meleti M, Mooi WJ, Casparie MK, van der Waal I (2007) Melanocytic nevi of the oral mucosa - no evidence of increased risk for oral malignant melanoma: an analysis of 119 cases. *Oral Oncol* 43: 976-981.
32. Carlos-Bregni R, Contreras E, Netto AC, Mosqueda-Taylor A, Vargas PA, et al. (2007) Oral melanoacanthoma and oral melanotic macule: a report of 8 cases, review of the literature, and immunohistochemical analysis. *Med Oral Patol Oral Cir Bucal* 12: E374-379.
33. Andrews BT, Trask DK (2005) Oral melanoacanthoma: a case report, a review of the literature, and a new treatment option. *Ann Otol Rhinol Laryngol* 114: 677-680.
34. van der Waal RI, Snow GB, Karim AB, van der Waal I (1994) Primary malignant melanoma of the oral cavity: a review of eight cases. *Br Dent J* 176: 185-188.
35. Nandapalan V, Roland NJ, Helliwell TR, Williams EM, Hamilton JW, et al. (1998) Mucosal melanoma of the head and neck. *Clin Otolaryngol Allied Sci* 23: 107-116.
36. Hicks MJ, Flaitz CM (2000) Oral mucosal melanoma: epidemiology and pathobiology. *Oral Oncol* 36: 152-169.
37. Pai A, Prasad S, Patil BA, Dyasanoor S, Hedge S (2012) Oral pigmentation: case report and review of malignant melanoma with flow charts for diagnosis and treatment. *Gen Dent* 60: 410-416.
38. Brandwein MS, Rothstein A, Lawson W, Bodian C, Urken ML (1997) Sinonasal melanoma. A clinicopathologic study of 25 cases and literature meta-analysis. *Arch Otolaryngol Head Neck Surg* 123: 290-296.
39. Weathers DR, Fine RM (1971) Thrombosed varix of oral cavity. *Arch Dermatol* 104: 427-430.
40. Lazos JP, Piemonte ED, Panico RL (2015) Oral varix: a review. *Gerodontology* 32: 82-89.
41. Dilsiz A, Aydin T, Gursan N (2009) Capillary hemangioma as a rare benign tumor of the oral cavity: a case report. *Cases J* 2: 8622.
42. Rachappa MM, Triveni MN (2010) Capillary hemangioma or pyogenic granuloma: A diagnostic dilemma. *Contemp Clin Dent* 1: 119-122.
43. Kamala KA, Ashok L, Sujatha GP (2014) Cavernous hemangioma of the tongue: A rare case report. *Contemp Clin Dent* 5: 95-98.
44. Loudon JA, Billy ML, DeYoung BR, Allen CM (2000) Angiosarcoma of the mandible: a case report and review of the literature. *Oral Surg Oral Med Oral Pathol Oral Radiol Endod* 89: 471-476.
45. Terada T (2011) Angiosarcoma of the oral cavity. *Head Neck Pathol* 5: 67-70.
46. Bartolucci EG, Swan RH, Hurt WC (1982) Oral manifestations of hereditary hemorrhagic telangiectasia (Osler-Weber-Rendu disease). Review and case reports. *J Periodontol* 53: 163-167.
47. Galletta A, Minerva AG (1998) [Hereditary hemorrhagic telangiectasia (Osler-Rendu-Weber disease) Management of epistaxis and oral hemorrhage by Nd-Yag laser]. *Stomatol* 47: 283-286.
48. Mohanna S, Bravo F, Ferrufino JC, Sanchez J, Gotuzzo E (2007) Classic Kaposi's sarcoma presenting in the oral cavity of two HIV-negative Quechua patients. *Med Oral Patol Oral Cir Bucal* 12: E365-368.
49. Lager I, Altini M, Coleman H, Ali H (2003) Oral Kaposi's sarcoma: a clinicopathologic study from South Africa. *Oral Surg Oral Med Oral Pathol Oral Radiol Endod* 96: 701-710.
50. Ficarra G, Berson AM, Silverman S Jr, Quivey JM, Lozada-Nur F, et al. (1988) Kaposi's sarcoma of the oral cavity: a study of 134 patients with a review of the pathogenesis, epidemiology, clinical aspects, and treatment. *Oral Surg Oral Med Oral Pathol* 66: 543-550.
51. Schelkun PM, Bellome J, Hiatt WR, DeBoom GW (1987) Multiple oral petechiae and ecchymoses in a patient with osteoarthritis. *J Am Dent Assoc* 115: 735-737.

-
52. Frantzis TG, Sheridan PJ, Reeve CM, Young LL (1972) Oral manifestations of hemochromatosis. Report of a case. *Oral Surg Oral Med Oral Pathol* 33: 186-190.
53. Vera-Sirera B, Risueño-Mata P, Ricart-Vayá JM, Baquero Ruíz de la Hermosa C, Vera-Sempere F (2012) Clinicopathological and immunohistochemical study of oral amalgam pigmentation. *Acta Otorrinolaringol Esp* 63: 376-381.
54. Meyerson MA, Cohen PR, Hymes SR (1995) Lingual hyperpigmentation associated with minocycline therapy. *Oral Surg Oral Med Oral Pathol Oral Radiol Endod* 79: 180-184.
55. Kleinegger CL, Hammond HL, Finkelstein MW (2000) Oral mucosal hyperpigmentation secondary to antimalarial drug therapy. *Oral Surg Oral Med Oral Pathol Oral Radiol Endod* 90: 189-194.
56. Cockings JM, Savage NW (1998) Minocycline and oral pigmentation. *Aust Dent J* 43: 14-16.
57. Rihani FB, Da'ameh DM (2006) Intraoral graphite tattoo. *Arch Dis Child* 91: 563.
58. Tamam L, Annagur BB (2006) Black hairy tongue associated with olanzapine treatment: a case report. *Mt Sinai J Med* 73: 891-894.
59. Ohsie SJ, Sarantopoulos GP, Cochran AJ, Binder SW (2008) Immunohistochemical characteristics of melanoma. *J Cutan Pathol* 35: 433-444.