

## Periodontal Treatment with Direct Medication Delivery of Hydrogen Peroxide and Oxygen

Duane C Keller\* and Marissa Buechel

Department of Dentist, Keller Professional Group PC, Perio Protect LLC, Bayless Avenue, St. Louis, MO, USA

### Abstract

**Background:** Periodontal disease affects 50% to 80% of the world population and is a host immune system inflammatory response associated with a change within the gingival sulcus or periodontal pocket. Conventional treatment and homecare programs are inadequate in controlling the biofilm that causes this disease. Direct medication delivery has been shown to modify the periodontal biofilm, decrease the microbial virulence, which should prove beneficial for the patient.

**Method:** In this case study the nature of the biofilm microenvironment was modified by delivering a 1.7% hydrogen peroxide gel, oxygen and Vibramycin into the patient's periodontal pockets using a direct medication delivery method (Perio Tray, Perio Protect LLC St. Louis, MO.). The hydrogen peroxide (Perio Gel, Perio Protect St. Louis, MO) has specific poloxamer and antimicrobial medicinal effects as it generates 5.7X oxygen concentration when hydrogen peroxide disassociates into water and oxygen within the medical device. The medicinal benefits of hydrogen peroxide, oxygen and Vibramycin help control the biofilm.

**Results:** The hydrogen peroxide, oxygen and Vibramycin alter the micro-environment of the patient's periodontal pockets from a more virulent to less virulent population. This decrease in biofilm virulence and a decrease in bacteria numbers is observed clinically as a decrease in bleeding upon probing and pocket probing depth.

**Conclusion:** Delivering and maintaining hydrogen peroxide, oxygen and Vibramycin in a patient's periodontal pocket, which alters the biofilm constituency, results in significantly reduced host inflammatory response. The decreased inflammation is observed clinically through decreased bleeding upon probing and decreasing the pocket probing depth of the periodontal pocket.

**Keywords:** Direct medication delivery; Perio tray; Perio protect method; Perio gel; Vibramycin

### Introduction

Periodontal disease is a host inflammatory response to the pathogens and their products that exist in the subgingival biofilm. There is strong evidence that micro-environmental changes occurring in the host periodontal pocket alters the type and number of periodontal pathogens that were originally commensal to become pathogenic [1]. Inflammatory changes within the host periodontal pocket result in an overgrowth of a specific subset of microbes within the subgingival plaque [2]. Inflammatory changes within the host periodontal pocket modify the microbial flora and alterations in the biofilm constituents are an important part of periodontal pathogenicity [3].

Conventional mechanical treatment such as debridement, scaling and root planning and surgery and conventional homecare like tooth brushing, flossing and oral rinses do not change the species of bacteria present before and after treatment [4]. Colombo et al. found debridement and scaling and root planning modestly decreased the mean counts of many of the recognized periodontal pathogens, but the counts of other suspected pathogens increased after treatment and the mean frequency of the reduced pathogens increased to base values by 9 months [5]. Palmer et al. in evaluating the effects of scaling and root planning found that removal of 75% of a biofilm mass resulted in a regrowth that reached 400% regeneration within three hours [6]. Teles et al. in two published research articles found that biofilms following mechanical therapy attained a growth potential that superseded pre-treatment levels within days and they demonstrated there was no significant alteration in the proportions of periodontal pathogens following conventional plaque removal [7].

Conventional tooth brushing can reduce the number of supragingival bacteria [8], but because a tooth brush can only extend about 0.9 mm

subgingival [9], the use of a tooth brush does not significantly alter the prevalence of subgingival bacteria [10]. Mechanical treatment and the effect of conventional homecare fail to achieve a plaque free dentition and repeated subgingival scaling and root planning should be avoided in sites that are 3 mm or less as this is liable to traumatize the periodontium [11]. Conventional mechanical treatments and home care do not change the subgingival biofilm constituency. Therefore, the remaining biofilm along with the host response to the biofilm lies as a significant part of the cause of periodontal disease.

Research has shown that it is possible to change the biofilm constituents in periodontal pockets 3 mm or greater using a method which delivers and maintains hydrogen peroxide, oxygen and Vibramycin into the periodontal pocket or gingival sulcus [12]. This research showed the constituency of the biofilm was changed where the predominant species before treatment is not the predominant species after treatment. This study further demonstrated that direct medication delivery decreased the numbers of bacteria by a log [2-4] and changed the pathology of the biofilm from a more virulent to a less virulent population. Changes in the biofilm and the decreased

**\*Corresponding author:** Duane C Keller, Department of Dentist, Keller Professional Group PC, Perio Protect LLC, Bayless Avenue, St. Louis, MO, USA, Tel: +966505693307; E-mail: [drdkeller@sbcglobal.net](mailto:drdkeller@sbcglobal.net)

**Received:** March 13, 2017; **Accepted:** March 22, 2017; **Published:** March 25, 2017

**Citation:** Keller DC, Buechel M (2017) Periodontal Treatment with Direct Medication Delivery of Hydrogen Peroxide and Oxygen. Oral health case Rep 3: 133. doi:[10.4172/2471-8726.1000133](https://doi.org/10.4172/2471-8726.1000133)

**Copyright:** © 2017 Keller DC, et al. This is an open-access article distributed under the terms of the Creative Commons Attribution License, which permits unrestricted use, distribution, and reproduction in any medium, provided the original author and source are credited.

virulence are observed clinically in this report to explain changes in the host periodontal pocket probing depths and bleeding upon probing.

The use of hydrogen peroxide in the direct medication delivery device has multiple purposes. Hydrogen peroxide is used to provide a positive pressure to help deliver the medication into the periodontal sulcus or pocket as it disassociates to  $5.7 \times$  saturation of oxygen [13], similar to the oxygen concentration in hyperbaric treatments. Hydrogen peroxide is a wound debridement agent and serves to disrupt the biofilm and fosters biofilm degrading and wound healing [14]. Hydrogen peroxide increases the subgingival oxygen saturation and hydrogen peroxide disrupts the bacterial cells by inactivating their enzymes used to control oxygen metabolism [15]. Hydrogen peroxide help modify the biofilm as it has multiple other antimicrobial activities [16].

The combination of hydrogen peroxide and Vibramycin delivered into a periodontal pocket with direct medication was evaluated by Putt et al. [17]. In their research, they found that the combination of Vibramycin and hydrogen peroxide worked slightly better in controlling bleeding upon probing and pocket depth improvements than only hydrogen peroxide used in custom formed prescription trays. Their study showed that the combination of hydrogen peroxide plus Vibramycin and the use of hydrogen peroxide alone were superior to scaling and root planning.

The delivery of hydrogen peroxide into the periodontal pocket increases the oxygen saturation, which is lethal to most obligate anaerobes, which are the predominant species in the biofilm in periodontal pockets 3 mm or deeper. Keller and Buechel showed the hydrogen peroxide and oxygen modified the biofilm from a pathologic more virulent entity to a less virulent pathologic entity along with a significant reduction in bacteria. This decrease in pathogenicity and decreased numbers of the biofilm should result in a lessened clinical response by decreasing the patient's clinical signs and symptoms of moderate to advanced periodontitis.

## Case Report

This theory of improved patient conditions in response to biofilm management is tested in this clinical case report. Pocket probing depths was recorded with the Florida probe for all sites under investigation by the same evaluator to reduce multiple evaluator error and all values were taken before any treatment. Direct medication delivery was provided with the Perio Protect Method (St. Louis, MO) where a custom formed Perio Tray was used to deliver the medication subgingival and interproximal in accordance with the patient's periodontal conditions. The Perio Protect Method uses the most involved periodontal region as the basis for treatment and treatment is modified as the patient responds to therapy and pocket probing depth and bleeding upon probing decrease over time.

A patient with advanced periodontal disease was treated with direct medication delivery using an FDA cleared medical device (Perio Tray) to deliver a 1.7% hydrogen peroxide (Perio Gel) as the primary antimicrobial. The poloxamers within the Perio Gel scavenge hydrogen and hydroxyl radicals and stabilize the chemical conversion of hydrogen peroxide to oxygen to maintain a constant therapeutic concentration for up to 15 minutes. The oxygen conversion produces a consistent 5.7 times increase in oxygen saturation in the Perio Tray that is delivered into interproximal and subgingival periodontal spaces [18]. Other medications, such as an antioxidant like Vibramycin, could also be used for patients with profuse bleeding, loss of stippling or purulent exudate

either generally applied or site specific to the affected wound area.

Hydrogen peroxide has multiple anti-inflammatory effects. Hydrogen peroxide introduced to human neutrophils suppresses the action of IL-8 mRNA, resulting in a reduction of the pro-inflammatory cytokine IL-8 [19]. Hydrogen peroxide also has a modulating effect on human dendritic cells where they decrease phenotypic activation, decrease pro-inflammatory chemokine and cytokine release and have been shown to regulate adaptive immune responses such as inflammation [20]. These anti-inflammatory effects should help decrease signs of inflammation, such as bleeding upon probing, and the addition of hydrogen peroxide to the periodontal pocket increases the oxygen concentration.

The increased oxygen concentration in the periodontal pocket approximates the oxygen concentration found with hyperbaric oxygen therapy [21] and can affect pro-inflammatory cytokine production. Inflammatory cytokines like IL-8 and tumor necrosis factor- $\alpha$  (TNF- $\alpha$ ) levels when measured in different oxygen environments by enzyme-linked immunosorbent assay and by immunohistochemical analysis were found to decrease in a higher oxygen tension [22]. Hyperbaric oxygen has been shown to markedly reduce prostaglandin production, resulting in a decreased inflammatory effect on alveolar bone in animals [23]. Inflammation is reduced when pro-inflammatory cytokine production is decreased [24] and this should be clinically evident with decreased bleeding upon probing.

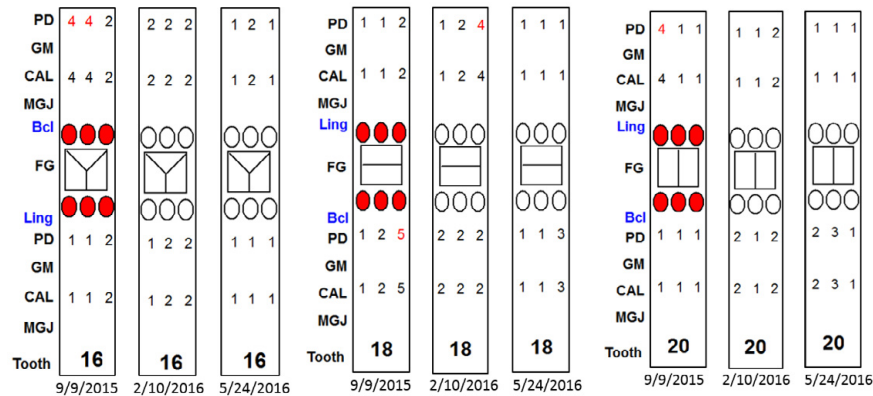
Antioxidant such as doxycycline can be used to help reduce gingival inflammation [25]. This is partially due to the effect doxycycline has on reducing macrophage inflammatory mediators, which provides proven clinical benefits on the inhibition of proinflammatory cytokine responses [26]. The tetracycline type of medications has been found to block the lipopolysaccharide stimulated TNF- $\alpha$  secretion, thereby helping prevent inflammatory tissue destruction. The combined use of antioxidants like doxycycline and hydrogen peroxide have been tested and were found to be clinically better and provided statistically significant better pocket probing depth and bleeding upon probing results [27].

Keller and Buechel (submitted for publication) demonstrate a significant change in the periodontal pathogens when treated with direct medication delivery of hydrogen peroxide gel and Vibramycin [28]. This research demonstrated the predominant species prior to direct medication delivery is not the same as the predominant species after treatment and a less virulent population exists after therapy. This decreased virulence is clinically evident in this study to decrease periodontal pocket depth and tissue inflammation (bleeding upon probing) over time.

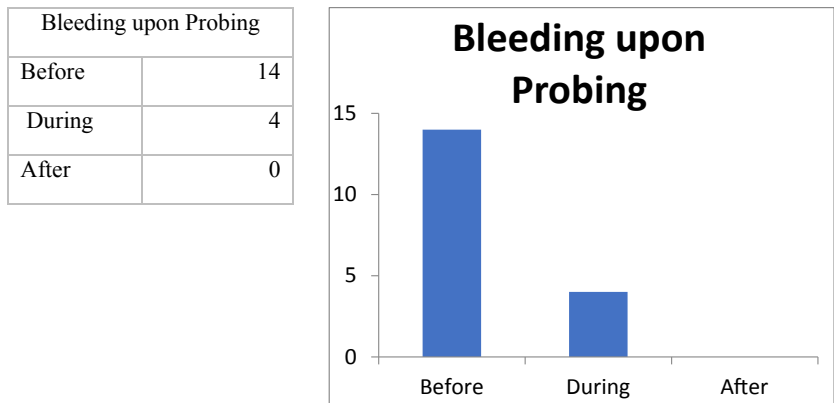
The findings in this case study demonstrate a management of periodontal pathogen and an improved host response. There was a uniform and consistent decrease in all pockets and bleeding upon probing when comparing the before, during and after treatment results. These findings are applicable for any patients suffering with periodontal disease.

## Results

The results shown in Figure 1 demonstrate a decrease in pocket probing depth and a decrease in inflammation (BOP) during the treatment of the periodontal biofilm with direct medication delivery in the absence of scaling and root planning. The pocket depth was found to be greater before treatment, which decreased during treatment from



**Figure 1:** Pocket probing depth and bleeding upon probing were recorded with the Florida Probe system. The initial measurements were recorded prior to treatment on 9/9/2015. During treatment results were recorded on 2/10/2016 and at the end of treatment results were recorded on 5/14/2016, for a total treatment of about 8½ months. These examples demonstrate three regions which are indicative of those found in this treatment evaluation. Pocket probing depths that were above normal prior to treatment decreased to normal measurements by the end of treatment and bleeding upon probing was totally eliminated for this patient with the direct medication delivery of hydrogen peroxide, oxygen and Vibramycin subgingival and interproximal.



**Figure 2:** Bleeding upon probing is an indication of ulceration and/or inflammation of the gingival tissues. This ulcerated and inflamed tissue is a local inflammatory response that may serve as the portal of entry where bacteria may come in contact with the host blood stream (bleeding upon probing). These results show there were 14 bleeding sites before treatment, which decreased to four bleeding sites during treatment to no bleeding sites by the end of treatment. This data supports the findings that direct medication delivery of hydrogen peroxide and oxygen and Vibramycin to the periodontal infected sites on 9/9/2015 decreases bleeding upon probing by 2/10/2016 and bleeding upon probing (tissue inflammation) is eliminate by 5/24/2016 with no evidence of reoccurrence.

an average pre-treatment depth of 5.1 mm to an average post-treatment depth of 2.9 mm at the end of the study. Inflammation as determined by bleeding upon probing was evaluated (Figure 2) and inflammation was found to decrease from 14 sites prior to direct medication delivery treatment, to 4 sites during treatment to zero (no bleeding sites) at the end of treatment.

Figure 3 demonstrates a composite view of the change in pocket depth before and after treatment. The result is a shift in pocket depth from deeper pockets to shallower pockets where there are fewer deeper pockets and more shallow pockets. Changes are also evident when viewing tissue changes before and during/after treatment. Figure 4 shows there is obvious inflammation and a purulent exudate prior to treatment. Figure 5 illustrates the placement of the Perio Tray as the first step in biofilm management. Figure 6 shows the patient's tissue changes during treatment with direct medication delivery and supragingival debridement where the tissue appearance is much improved. Figure 7 demonstrates further significant improvements in the patient's clinical appearance.

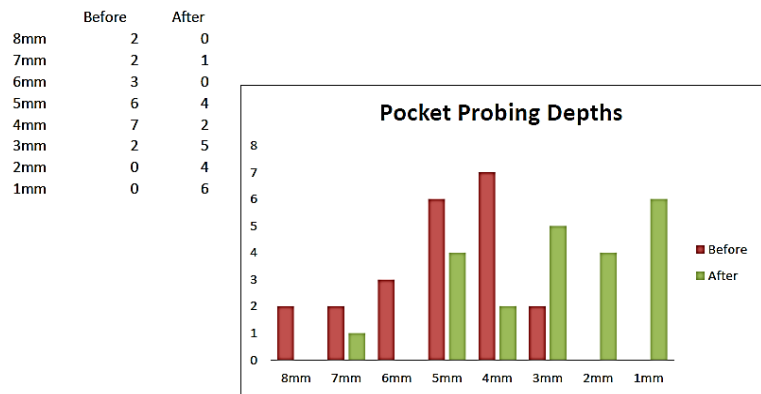
Direct medication delivery of hydrogen peroxide and a subclinical dose of doxycycline change the micro-environment of the periodontal

pocket providing significant improvements for the patient. The increased oxygen concentration, which approximated the oxygen saturation of a hyperbaric chamber, improves wound healing and microbiologic control where Gram negative obligate anaerobes are replaced with more commensal types of bacteria. This change in the biofilm resulted in improved pocket probing depth and bleeding upon probing (Figures 1-3). Much of these improvements in the tissue conditions were due to the increased oxygen concentration and the anti-inflammatory effects of hydrogen peroxide and oxygen and the anti-inflammatory effects of the Vibramycin.

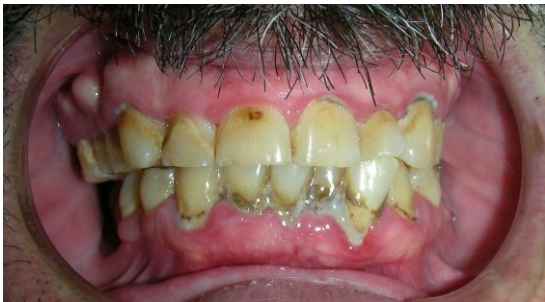The clinical improvements (Figures 4-7) and the significance of these changes is evident and measurable. The direct medication delivery method was found to successfully change the composition of the micro-environment and this change from a more virulent population to a decreased number of less virulent population resulted in decreasing the pocket probing depth and tissue inflammation.

### Discussion

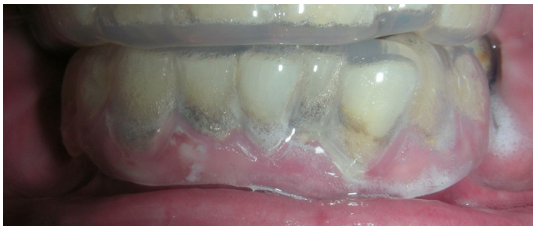Conventional treatments do not alter the biofilm present after treatment and home care like brushing and flossing are not able to



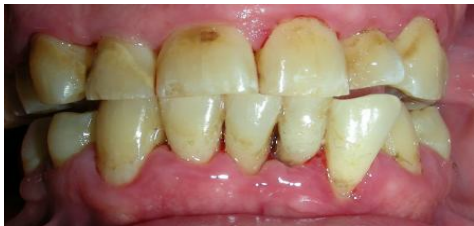**Figure 3:** Pocket probing depths were recorded for all treatment sites before and after treatment. There is a marked change in the pocket depth with more numerous and deeper pockets found prior to treatment and shallower pockets found after treatment. The average pocket depth before treatment is 5.1 mm. The average pocket depth after treatment is 2.9 mm. This indicates there is a significant decrease in pocket depth with usage of the Perio Protect Method direct medication delivery. This is also important because of the short period of time needed to attain these results, which remained constant to the end of treatment without evidence of pocket depth increasing.



**Figure 4:** The tissue inflammation and swelling is obvious with the before treatment photograph. The exudate and the tissue appearance are indicative of a host response to the biofilm. Marked supragingival plaque is evident. Pocket probing depths and bleeding upon probing were recorded for each tooth at the mesial buccal, buccal, distal buccal, mesial lingual, lingual and distal lingual aspects of each tooth. Teeth 16, 18 and 20 recording can be viewed in Figure 1.

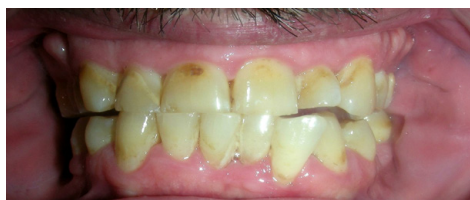

**Figure 5:** The upper and lower Perio Tray were fabricated according to the most severe pocket probing depth before treatment. The trays are used in accordance to the patient's initial conditions, where the frequency and duration of treatment correspond to the degree of infection and damage. The hydrogen peroxide was converted to water and oxygen, increasing the oxygen concentration to >5X, comparable to hyperbaric therapy. The increased inter-tray pressure directs the materials subgingival and interproximal. The materials are held in place long enough for the medications to modifies the micro-environment of the periodontal pocket. The medications delivered subgingival and interproximal change the biofilm during the treatment.



**Figure 6:** The changes in the tissues are evident from this two week visit after Perio Tray delivery. The medications have modified the micro-environment where the predominant species which were Gram negative obligate anaerobes are now Gram positive anaerobes, Gram positive and negative facultative anaerobes and aerobic bacteria. The periodontal pocket depth and bleeding upon probing decreased as hydrogen peroxide and oxygen affected the micro-environment of the patient's periodontal pockets and decreased the tissue inflammation.





**Figure 7:** The end of active treatment photograph demonstrates how much the observable tissue conditions have improved. Bleeding upon probing has decreased as has the pocket probing depths. Through direct medication delivery the cause of disease is controlled and the tissue appears to be healthier. The predominant species found in the periodontal sulci at the after-treatment samples are not the same bacteria found before treatment. Direct medication delivery will be a part of the patient's long-term home maintenance program to help maintain these gains.

change the subgingival micro-environment in pockets 3mm or greater. As a result, patients continue to experience periodontal disease and must be routinely re-treated.

Direct medication delivery resulted in significantly improved patient conditions. Pocket depth decreased and remained decreased during and up to the end of treatment with no signs of deteriorating as the patient continued to use direct medication delivery of hydrogen peroxide and Vibramycin to the periodontal pocket. Most of these benefits are attributable directly to the medicinal benefits of the medication in controlling obligate anaerobes, changing the predominant bacterial species, decreasing bacterial virulence, decreasing inflammation and the promotion of healing.

The bleeding upon probing improved dramatically. Bleeding that was present at the initial examination was absent by the end of treatment and periodontal probing decreased during treatment. This demonstrated a significant improvement of localized inflammation control that lasted through the treatment protocol. This was due to the antimicrobial, anti-inflammatory and biofilm modifications caused by the medications held in place over time. There was no evidence of any bleeding upon probing or localized inflammation at the end of the study.

The tissue appearance and conditions are evident (Figures 4-7). There was a significant decrease in inflammation and tissue swelling. Supragingival plaque was managed and did not appear to reoccur. This improvement in biofilm control significantly reduced tissue damage and resulted in an observable improvement in appearance and tissue conditions. The fact there was no observed return of the disease indicates a long-term management with reduced recidivism and a resultant decrease in costs to the patient.

The cause of periodontal disease can be controlled with direct medication delivery. The improvements for this one patient have significant meaning for any patient suffering with periodontal disease. Controlling the cause of disease resulted in a decrease of disease signs and symptoms when measuring pocket probing depth and bleeding upon probing and a general improvement in the tissue appearance. Further testing will need to be done to confirm these results in a larger study over time.

## Conclusions

The objective of the case report was to evaluate the clinical changes for a patient treated with direct medication delivery of hydrogen peroxide, oxygen and Vibramycin into a patient's gingival sulcus or periodontal pocket. The method was easy for the patient to use, safe, reliable and had demonstrable improved results in pocket probing depths, bleeding upon probing and the general tissue appearance. The treatments changed the biofilm resulting in a less virulent biofilm population and this change in virulence resulted in decreasing the patient's tissue responses to infection.

The use of direct medication delivery provides beneficial results for the patient. The incidence of inflammation as measured with bleeding upon probing was found to decrease substantially during treatment. The periodontal pockets were also found to decrease throughout treatment with an average pocket depth of 5.1 mm prior to treatment that decreased to 2.9 mm by the end of treatment.

The tissue appearances demonstrate significant improvements from the photographs prior to treatment, compared to during and end of treatment images. This method improved treatment results and attain a better localized health for this patient.

This method and improvement in treatment results will need to be evaluated further in a larger study to confirm application. Improvements in local results may have some bearing on changes in systemic inflammatory results and these changes should be applicable to patients experiencing periodontal disease.

## Contributions and Acknowledgements

Perio Protect LLC provided the Perio Tray and Perio Gel for this study.

## References

1. Berezow AB, Darveau RP (2011) Microbial shift and periodontitis. *Periodontol* 2000 55(1): 36-47.
2. Bartold PM, van Dyke TE (2013) Periodontitis: A host-mediated disruption of microbial homeostasis. Unlearning learned concepts. *Periodontol* 2000 62(1): 203-217.
3. Hasturk H, Kantarci A, Goguet-Surmenian E, Blackwood A, Andry C, et al. (2007) Resolvin E1 regulates inflammation at the cellular and tissue level and restores tissue homeostasis *in vivo*. *J Immunol* 179: 7021-7029.
4. Uzel NG, Teles FR, Teles RP, Song XQ, Torresyap G, et al. (2011) Microbial shifts during dental biofilm re-development in the absence of oral hygiene in periodontal health and disease. *J Clin Periodontol* 38(7): 612-620.
5. Colombo AP, Teles RP, Torres MC, Rosalém W, Mendes MC, et al. (2005) Effects of non-surgical mechanical therapy on the subgingival microbiota of Brazilians with untreated chronic periodontitis: 9-month results. *J Periodontol* 76(5): 778-784.
6. Palmer RJ, Caldwell DE (1995) Effects of mechanical dental therapy. *J Micro methods* 24(2): 171-182.
7. Teles RF, Teles R, Uzel NG (2012) Early microbial succession in redeveloping dental biofilms in periodontal health and disease. *J Periodontol Res* 47(1): 95-104.
8. The Use and Handling of Toothbrushes (2013) National center for chronic disease prevention and health promotion. Accessed on: February 12, 2017.
9. Waerhaug J (1981) Effect of tooth brushing on subgingival plaque formation. *J Periodontol* 52(1): 30-34.
10. Costa MR da Silva VC, Miqui MN (2010) Effects of ultrasonic electric and manual tooth brushes on subgingival plaque composition in orthodontically banded molars. *Am J Orthod Dentofacial Orthop* 137 (2): 229-235.

11. Peterslika GJ, Ehmke B, Flemmig TF (2000) Antimicrobial effects of mechanical debridement. *Periodontol* 28: 56-71.
12. Keller DC, Buechel M (2016) Biofilm changes with direct medication delivery. *Oral Biol Dent* 5: 1-7.
13. Dunlap TL, Keller DC, Marshall MV (2011) Subgingival delivery of oral debriding agents: A proof of concept. *J Clin Dent* 22(5): 149-158.
14. Lu M, Hansen EN (2017) Hydrogen peroxide wound irrigation in orthopedic surgery. *J Bone Joint Infect* 2(1): 3-9.
15. Acharya T (2017) Oxygen requirements or pathogenic bacteria. *Microbe online*.
16. Boateng MK, Price SL, Huddersman KD, Walsh SE (2011) Antimicrobial activities of hydrogen peroxide and its activation by novel heterogenous Fenton's-like modified PAN catalyst. *J Appl Microbiol* 111(6): 1533-1543.
17. Putt MS, Mallatt ME, Messmann LL, Proskin HM (2014) A 6-month clinical investigation of custom tray application of peroxide gel with and without doxycycline as adjuncts to scaling and root planing for treatment of periodontitis. *AM J Dent* 27: 273-284.
18. Putt MS, Proskin HM (2013) Custom tray application of peroxide gel as an adjunct to scaling and root planing in the treatment of periodontitis: Results of a randomized controlled trial after six months. *J Clin Dent* 24: 100-107.
19. Yamamoto K, Kushima R, Kasaki O (2003) Combined effect of hydrogen peroxide induced oxidative stress and IL-1a on IL-8 production in CaCo<sub>2</sub> cells (a human colon carcinoma cell line) and normal intestinal epithelial cells. *Inflam* 27(3):123-128.
20. Pazmandi K, Magyarics Z, Boldogh I (2012) Modulatory effects of low-dose hydrogen peroxide on the function of human plasmacytoid dendritic cells. *Free Radic Biol Med* 52(3): 635-645.
21. Latham E, Byrd RP (2016) Hyperbaric oxygen therapy.
22. Thom SR (2011) Hyperbaric oxygen-its mechanisms and efficacy. *Plast Reconstr Surg* 127: 131s-141s.
23. Al-Waili NS, Butler GJ (2006) Effects of hyperbaric oxygen on inflammatory response to wound and trauma: possible mechanism of action. *The Sci World J* 6: 425-441.
24. de Oliveira CMG, Sakata RK, Issy AM (2011) Cytokines and pain. *Rev Bras Anesthesiol* 61: 255-265.
25. Firalti E, Unal T, Onan U, Sandalli P (1994) Antioxidative activities of some chemotherapeutics. A possible mechanism in reducing gingival inflammation. *J Clin Periodontol* 21(10): 680-683.
26. Cazalis J, Bodet C, Gagnon G, Grenier D (2008) Doxycycline reduces lipopolysaccharide-induced mediator secretion in macrophage and ex vivo human whole blood models. *J Periodontol* 79(9): 1762-1768.
27. Putt M, Proskin H (2012) Custom tray application of peroxide gel as an adjunct to scaling and root planing in the treatment of periodontitis: A randomized controlled three-month clinical trial. *J Clin Dent* 23(2): 48-56.
28. <http://www.hoajonline.com/journals/pdf/2053-5775-5-1.pdf>