

Percutaneous Injection of Polymethyl Methacrylate for the Treatment of Osteoarthritic Knee Pain Caused by Bone Marrow Edema: A Case Report and Review of Literature

Li-Hua Gao*, Gui-Qiang Miao, Xue-Hui Zang, Hui Sun and Li-Hui Wang

Nanhai Hospital of Southern Medical University and People's Hospital of Nanhai District of Foshan, Guangdong 528200, Hong Cong Sar, China

Abstract

Osteoarthritis is a common disease that affects the elderly peoples, with a detrimental effect on quality of life as a result of pain, and total joint replacement is usually the last option for end-stage osteoarthritis. However, for those whom have complex diseases, total joint replacement was limited. Thus, looking for an alternative way to relieve pain is necessary. Recently, bone marrow edema is has been demonstrated to associate with knee pain and osteoarthritis. Thus, targeting bone marrow edema may provide a promising approach for relieving knee pain and delayed osteoarthritis development and progression. The present study highlights the importance of bone marrow edema to recurrent knee pain, and demonstrates an alternative way for treating patients who have osteoarthritic knee pain caused by bone marrow edema, and are not suitable for total knee replacement as a result of contraindications such as multiple internal diseases and high risk of operation.

Keywords: Osteoarthritis; Pain; Percutaneous injection; Polymethyl methacrylate; Bone marrow edema

Introduction

Osteoarthritis (OA), a common disease that affects the elderly, is characterized by the degeneration of whole “organ” (e.g. synovium, cartilage, subchondral bone, ligaments and tendons) [1]. As the average life expectancy extend, the incidence of knee osteoarthritis increases gradually in recent years [1,2]. The most detrimental effect of OA on the patient is low life quality as a result of pain caused intra- or extra-knee joint. End-stage OA in knee joint is also a debilitating disease that is often treated with total joint replacement (TKR), which is generally considered as the final option [3]. However, for those whom have a variety of complicated diseases, they miss the chance to undergo TKR. Instead, nonsteroidal anti-inflammatory drugs such as Celebrex and Etoricoxib have been widely used in this population in order to relieve pain and inflammatory response, although they may cause side-effects to the elderly [4,5]. Therefore, it will be significantly to seek an alternative approach to combat the clinical symptom.

Several factors including synovitis, cartilage defect, micro-fracture of subchondral bone, osteophyte, malalignment of the knee joint, and bone marrow edema (BME) have been shown to associate with knee pain [5,6]. With the popularization and continuous renewal of MRI, the recent research highlighted the important role of BME in causing pain and promoting the development and progression of OA [7-9]. Recently, it has been shown that BME of the knee occurs secondary to a myriad of causes such as such as meniscal tears, cartilage deterioration, subchondral cyst formation and mechanical malalignment [9,10]. Therefore, targeting BML has been considered as a promising approach for relieving knee pain and OA.

At present, there are a variety of therapeutic schemes for knee OA with BME, including conservative treatment such as prostacyclin and bisphosphonate therapy, and operative treatment by correcting knee alignment, core decompression and subchondroplasty. However, the most appropriate therapeutic scheme has not yet been standardized [10,11]. The present study aims to highlight the importance of BME to recurrent knee pain, and demonstrate an alternative way of percutaneous injection of polymethyl methacrylate for the treatment of osteoarthritic knee pain caused by BME.

Material and Methods

Information of the patient: female, 73 years old, Body Mass Index (BMI): 28.2kg/m²; having arthralgia on her left knee (weight-bearing walking pain); VAS score: 9, lym score: 45, KOOS score: 52. There was no obvious improvement after conservative treatments; as a result, she was hospitalized for further treatment. Physical examination showed that there was obvious pressing pain on her left knee joint, especially on the inner side. The range of motion of the knee joint was 5-120°. The X-ray showed that there is an introversion of 18° and malalignment (Figure 1A). It passed the bending test (+). Patella had friction fremitus (+). 3.0T MRI (GE Medical systems, Waukesha, WI, USA) was used to evaluate BME in the knee joint. The hallmark of a BME is an area of decreased signal intensity on T1 weighted MRI with a corresponding area of increased signal intensity on a T2 weighted MRI. The analysis indicated that there was obvious BME in the left proximal tibia from lateral, anterior and posterior view (Figure 1B and 1C).

Detailed case discussion was taken after the patient was hospitalized. The patient was suffering from a variety of internal diseases, such as hypertension, diabetes, residuals of cerebral infarction, and chronic obstructive pulmonary disease. EP of color doppler ultrasound of heart was 52%. After sufficient but ineffective conservative treatment, an operation must be carried out as intervention treatment. However, there was high risk for this patient to have an operation like TKR, because the patient was suffering from a variety of internal diseases and the EP is 52%.

***Corresponding author:** Gao LH, Nanhai Hospital of Southern Medical University and People's Hospital of Nanhai District of Foshan, Guangdong 528200, Hong Cong Sar, China, Tel: 86-0757-86281572; E-mail: Gihua200@126.com

Received March 27, 2017; **Accepted** June 07, 2017; **Published** June 15, 2017

Citation: Gao LH, Miao GQ, Zang XH, Sun H, Wang LH (2017) Percutaneous Injection of Polymethyl Methacrylate for the Treatment of Osteoarthritic Knee Pain Caused by Bone Marrow Edema: A Case Report and Review of Literature. J Cytol Histol 8: 452. doi: [10.4172/2157-7099.1000452](https://doi.org/10.4172/2157-7099.1000452)

Copyright: © 2017 Gao LH, et al. This is an open-access article distributed under the terms of the Creative Commons Attribution License, which permits unrestricted use, distribution, and reproduction in any medium, provided the original author and source are credited.

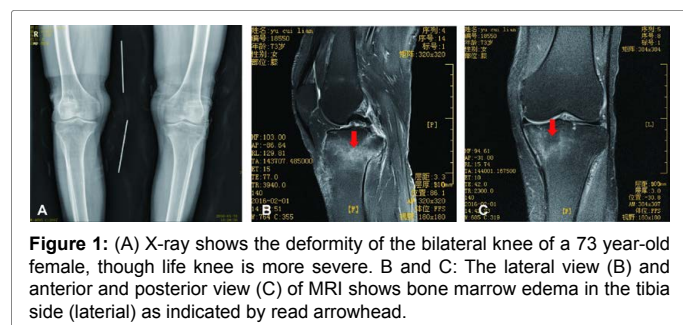


Figure 1: (A) X-ray shows the deformity of the bilateral knee of a 73 year-old female, though left knee is more severe. B and C: The lateral view (B) and anterior and posterior view (C) of MRI shows bone marrow edema in the tibia side (lateral) as indicated by red arrowhead.

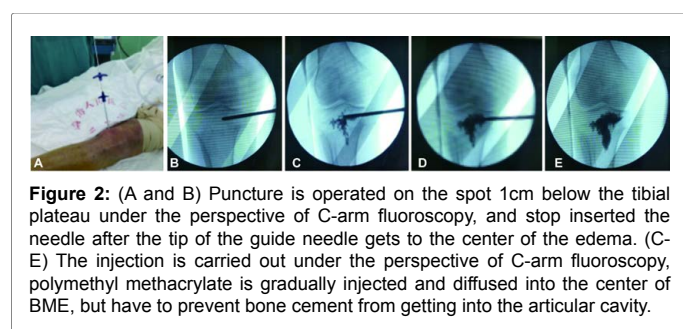


Figure 2: (A and B) Puncture is operated on the spot 1cm below the tibial plateau under the perspective of C-arm fluoroscopy, and stop inserted the needle after the tip of the guide needle gets to the center of the edema. (C-E) The injection is carried out under the perspective of C-arm fluoroscopy, polymethyl methacrylate is gradually injected and diffused into the center of BME, but have to prevent bone cement from getting into the articular cavity.

Since MRI indicated there was relatively obvious BME on the inner side of proximal tibia, and that the pain was probably caused by BME, the percutaneous injection of polymethyl methacrylate was considered. After elaborate explanation to the patient and her family about the state of illness, operation method, and risk of operation, they agreed to have this kind of treatment.

After femoral nerve block anesthesia, the operation was carried out in the operating room. Tourniquet was applied to the left thigh. Conventional disinfection was taken, and operation towel was spread. According to the location of BME indicated by MRI, puncture was operated on the spot 1cm below the tibial plateau. Under the perspective of C-arm fluoroscopy, stop inserting the needle after the tip of the guide needle gets to the center of the edema. Change the tube, pull out the guide needle, and inject polymethyl methacrylate (Figure 2A and 2B). The injection should be carried out under the perspective of C-arm fluoroscopy to prevent bone cement from getting into the articular cavity. Pull out the tube after the bone cement diffuses in the center of BME gradually (Figure 2C-2E). After the operation, the patient got back to the ward safely.

Results

On the first postoperative day, the patient felt the pain was apparently relieved. The range of motion of the knee joint was 5-120°. The VAS score was 5, the LYM score was 65, and the KOOS score was 72. With the aid of double crutches, the affected limb can walk with no weight. On the third postoperative day, X-ray showed cement was localized in the central of the BME site, and MRI showed the BME was obviously alleviated. Semi-quantitative score of WORS was 10, which was dramatically declined compared with that before the operation (Figure 3A-3D). In the follow-up visit to the patient (a month later), the VAS score was 2, the LYM score was 80, and the KOOS score was 78. Semi-quantitative score of WORS was 4. MRI showed there was no any BME around the injection site (Figure 3E and 3F). The patient could walk with weight and take care of herself. She was very satisfied with the treatment.

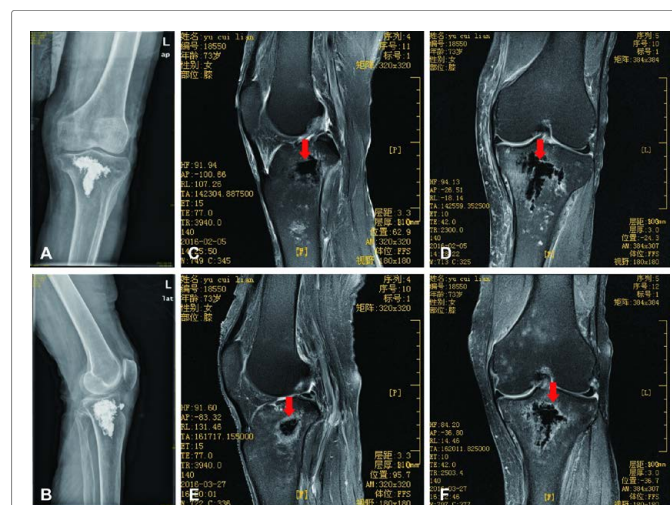


Figure 3: (A and B) X-ray (The lateral view, anterior and posterior view) shows the polymethyl methacrylate is localized in the center of BME. C and D: The lateral view (C) and anterior and posterior view (D) of MRI shows bone marrow edema is disappeared, and the polymethyl methacrylate (read arrowhead) is shown in deep dark as demonstrated by T1 weighted MRI. (E and F) The lateral view (E) and anterior and posterior view (F) of MRI shows no any sign of bone marrow edema. The polymethyl methacrylate (read arrowhead) is existed in deep dark, and some new bone Ingrowth in light dark as demonstrated by T1 weighted MRI.

Discussion

There are a variety of reasons for knee joint pain, including articular cartilage degeneration, malalignment, and BME etc. [9]. But the root cause of the pain has not been found yet. Recent research shows BME of the knee joint is the main reason of knee OA, and that alleviate BME lead to reduction of knee joint pain [10]. In addition to this, BME also contribute to cartilage degeneration of knee joint and is involved in the development and progression of OA [12]. At present, the pathogenesis of BME remains unknown. Recent study has suggested that the increase of stress causes minor fracture of cartilage metaphysis and then developed into genu varum [13]. Stimulation of repeated stress also can destroy the structure of bone trabecula, and decrease the interstitial fluid, accompanied by the increase of bleeding [14]. Evidence has demonstrated that increased internal bleeding of bone marrow results in the increase of intraosseous pressure which may further cause decrease of bone tissue perfusion and bone cell hypoxia [15]; Bone cell hypoxia may induce destruction of nerve vessel bundles, acidosis of regional tissue, release of inflammatory medium, such as prostaglandin etc, and cause pain [14]. Thus, the definite relation between BME of knee joint and knee joint pain has been proved [16]. Since cartilage degeneration marks progression of osteoarthritis, and that cartilage lack of nerve fiber thereby cannot sense pain, we then considered BME, which rich in nerve fiber, as a main reason for causing pain in our case.

In general, patients whom suffered from seriously BME with end-stage OA, the TKR is the first option for them in order to improve the quality of life. However, TKR is prohibited for those whom have several high-risk complications, which are highlighted as contraindications for TKR. Thus, only targeting BME rather than undergo TKR may provide an alternative way for treating end-stage OA with BME. Recently, server clinical studies have undertaken to prove this concept. Randomized controlled trial shows zoledronic acid can alleviate the pain caused by knee osteoarthritis accompanied with BME to a great degree [17].

According to a case report, BME disappears 8 weeks after using Xgeva in treating osteoarthritis accompanied by BME [18]. But this case report is a rare phenomenon which is suitable for young patients, so there is no promotion experience. In contrast, MET analysis indicates that there is no clear evidence showing the effect of bisphosphonate in treating osteoarthritis accompanied by BME [19].

The unfavorable effect of conservative treatment encourages people to try other intervening measures for osteoarthritis accompanied by BME. For example, hyperbaric oxygen therapy has better effect on bone marrow edema of the hip [20], but it has not been applied to the treatment of BME of knee joint. Moreover, noninvasive treatment like extracorporeal shock wave therapy was once applied to treat BME of knee joint, and the pain was alleviated [21]. But it is hardly used as clinical application, so its clinical effect requires further exploration. On the other hand, in treatment for painful BME by open wedge tibial osteotomy, it is believed the pain of patients suffering from symptomatic BME on knee joint was caused by BME resulting from oversized load. Though wedge tibial osteotomy has achieved good clinical effect, it has higher surgical risk and more serious trauma for aged patients. Currently, central decompression is taken as the golden standard for alleviating the pain caused by BME as soon as possible [22]. Invasive treatment includes injection of anhydrous calcium phosphate for treating BME has been reported [23]. In this paper, we have applied invasive treatment in terms of percutaneous injection of polymethyl methacrylate for the treatment of osteoarthritic knee pain caused by BME, and have achieved good results (fewer complications, no affect on range of motion, and decrease pain). Since polymethyl methacrylate is frequently applied in percutaneous vertebroplasty and has achieved favorable clinical effect, its safety has been proved.

There are several possible mechanisms of using percutaneous injection of polymethyl methacrylate to treat osteoarthritic knee pain caused by BME. As aging, tiny fracture will happen on proximal tibia with BME which in turns give rise to the decrease of bearable stress. And after percutaneous injection of polymethyl methacrylate to the proximal tibia, it can provide firm immobilization to recover the altitude of the articular surface so that it can bear more stress. On the other hand, the heat released during solidification will inactivate nerves around the edema to prevent them conducting pain.

Conclusion

As people's average life expectancy extends, the incidence of knee osteoarthritis increases gradually in recent years. How to choose applicable therapeutic methods has been a great issue faced by surgeons. The present study aims to highlight the importance of BME to recurrent knee pain, and demonstrate an alternative way for treating patients who have osteoarthritic knee pain caused by BME, and are not suitable for TKR as a result of contraindications such as multiple internal diseases and high risk of operation. Though it gets favorable clinical effect, it still has many limitations: there are relatively less cases to study; the observation time is not long enough; it is difficult to have TKR after percutaneous injection of polymethyl methacrylate operation. According to the above limitations, it is not suitable for relatively young patients who may choose TKR.

Conflict of Interest

The authors declare no conflict of interest.

References

- Villafane JH, Valdes K, Berjano P (2015) Clinical Update: Conservative

Management of Carpometacarpal Joint Osteoarthritis. *J Rheumatol* 42: 1728-1729.

- Shi D, Dai J, Xu Z (2015) Update on basic and clinical aspects of osteoarthritis. *Ann Transl Med* 3: 142.
- Peer MA, Lane J (2013) The Knee Injury and Osteoarthritis Outcome Score (KOOS): a review of its psychometric properties in people undergoing total knee arthroplasty. *J Orthop Sports Phys Ther* 43: 20-28.
- Richards MM, Maxwell JS, Weng L (2016) Intra-articular treatment of knee osteoarthritis: from anti-inflammatories to products of regenerative medicine. *Phys Sportsmed* 44: 101-108.
- Klinge SA, Sawyer GA (2013) Effectiveness and safety of topical versus oral nonsteroidal anti-inflammatory drugs: a comprehensive review. *Phys Sportsmed* 41: 64-74.
- Fingleton C, Smart K, Moloney N (2015) Pain sensitization in people with knee osteoarthritis: a systematic review and meta-analysis. *Osteoarthritis Cartilage* 23: 1043-1056.
- Xu L, Hayashi D, Roemer FW (2012) Magnetic resonance imaging of subchondral bone marrow lesions in association with osteoarthritis. *Semin Arthritis Rheum* 42: 105-118.
- Suresh SS (2010) Migrating bone marrow edema syndrome: a cause of recurring knee pain. *Acta Orthop Traumatol Turc* 44: 340-343.
- Unay K, Poyanli O, Akan K (2009) The relationship between bone marrow edema size and knee pain. *Knee Surg Sports Traumatol Arthrosc* 17: 1298-1304.
- Collins JA, Beutel BG, Strauss E (2016) Bone Marrow Edema: Chronic Bone Marrow Lesions of the Knee and the Association with Osteoarthritis. *Bull Hosp Jt Dis* 74: 24-36.
- Niethammer TR, Valentin S, Gulecyuz MF (2015) Bone Marrow Edema in the Knee and Its Influence on Clinical Outcome After Matrix-Based Autologous Chondrocyte Implantation: Results After 3-Year Follow-up. *Am J Sports Med* 43: 1172-1179.
- Tanamas SK, Wluka AE, Pelletier JP (2010) Bone marrow lesions in people with knee osteoarthritis predict progression of disease and joint replacement: a longitudinal study. *Rheumatology (Oxford)* 49: 2413-2419.
- Kesemenli CC, Memisoglu K, Muezzinoglu US (2013) Treatment for painful bone marrow edema by open wedge tibial osteotomy. *Eur J Orthop Surg Traumatol* 23: 825-829.
- Eustace S, Keogh C, Blake M (2001) MR imaging of bone oedema: mechanisms and interpretation. *Clin Radiol* 56: 4-12.
- Aaron RK, Dyke JP, Ciombor DM (2007) Perfusion abnormalities in subchondral bone associated with marrow edema, osteoarthritis, and avascular necrosis. *Ann N Y Acad Sci* 1117: 124-137.
- Jacobs CA, Christensen CP, Karthikeyan T (2016) Subchondral Bone Marrow Edema Had Greater Effect on Postoperative Pain After Medial Unicompartmental Knee Arthroplasty Than Total Knee Arthroplasty. *J Arthroplasty* 31: 491-494.
- Laslett LL, Dore DA, Quinn SJ (2012) Zoledronic acid reduces knee pain and bone marrow lesions over 1 year: a randomised controlled trial. *Ann Rheum Dis* 71: 1322-1328.
- Geith T, Mutschler W, Berger F (2015) Therapy of bone marrow edema syndrome in the knee with denosumab. Case report]. *Unfallchirurg* 118: 230-232.
- Davis AJ, Smith TO, Hing CB (2013) Are bisphosphonates effective in the treatment of osteoarthritis pain? A meta-analysis and systematic review. *PLoS One* 8: e72714.
- Capone A, Podda D, Ennas F (2011) Hyperbaric oxygen therapy for transient bone marrow oedema syndrome of the hip. *Hip Int* 21: 211-216.
- Gao F, Sun W, Li Z (2015) Extracorporeal shock wave therapy in the treatment of primary bone marrow edema syndrome of the knee: a prospective randomised controlled study. *BMC Musculoskelet Disord* 16: 379.
- Baier C, Schaumburger J, Gotz J (2013) Bisphosphonates or prostacyclin in the treatment of bone-marrow oedema syndrome of the knee and foot. *Rheumatol Int* 33: 1397-1402.
- Chatterjee D, McGee A, Strauss E (2015) Subchondral Calcium Phosphate is Ineffective for Bone Marrow Edema Lesions in Adults With Advanced Osteoarthritis. *Clin Orthop Relat Res* 473: 2334-2342.