

Percutaneous Endoscopic Interlaminar Approach: Medial Foraminal Decompression in Treating Lumbar Disc Herniation or Spinal Stenosis

Ding Yu*, Zhu Teng-Yue, Zhang Jian-jun, Cui Hong-Peng, Fu Ben-Sheng and Qiao Jin-Lin

Department of Rehabilitation Medicine and Pain Center, PLA Navy General Hospital, Beijing, China

*Corresponding author: Ding Yu, Department of Rehabilitation Medicine and Pain Center, PLA Navy General Hospital, Beijing, China, Tel: +86 10 68546022; E-mail: cosmos_dingyu@163.com

Received date: May 15, 2017; Accepted date: May 27, 2017; Published date: May 31, 2017

Copyright: © 2014 Yu D, et al. This is an open-access article distributed under the terms of the Creative Commons Attribution License, which permits unrestricted use, distribution, and reproduction in any medium, provided the original author and source are credited.

Abstract

Background: The technique of transforaminal endoscopic spine surgery is being widely used for lumbar degenerative diseases. But the interlaminar endoscopic surgery, which is more familiar and easier to be operated for spine surgeons, is more easily applied by traditionally trained surgeons.

Objective: We propose the technique of percutaneous endoscopic medial foraminal decompression through interlaminar approach for the treatment of lumbar disc herniation (LDH) and spinal stenosis (LSS), and to explore the safety and efficacy of using this technique clinically.

Methods: Thirty-two LDH and eleven LSS patients received medial foraminal decompression surgery with 22.6 ± 7.9 months follow-up. Through interlaminar space, we are able to perform discectomy and lateral recess decompression to decompress the medial foraminal area. Clinical efficacy was assessed by calculating the scores of VAS, SF-36, and lumbar disease JOA and ODI respectively at preoperative, postoperative and the discharge period, 3-6 months postoperatively and the final follow-up time point when patients were considered having received maximum surgical benefit. Follow-up time period varied because of the patients' follow-up logistics in China serving a large referral area made it difficult for rural patients to return at established intervals for the study.

Results: For both LDH and LSS patients, the observational indexes of the follow-up time points showed significant differences compared with those preoperatively ($P < 0.01$). Surgical results were assessed according to JOA scores: 22 cases were excellent, 16 cases were good, and 5 cases were fair by modified MacNab criteria. The satisfaction rate of PEMFD was 88.37% during the follow-up period with the improvement of daily life quality. One patient had postoperative radiation calf pain and foot numbness, and another one had the dorsal remnant of the dural sac without symptom.

Conclusion: The treatment for LDH and LSS with medial foraminal decompression is safe and effective with minimal tissue trauma, less surgical morbidity to the lumbar canal, with full decompression of nerve roots and the cauda equina. It is more similar to traditional open surgery and easier to achieve adequate canal decompression, especially for LSS.

Keywords: Lumbar disc herniation; Lumbar spinal stenosis; Endoscope; Minimally invasive surgery; Medial foraminal; Decompression

Introduction

As one of the most common clinical diseases, Lumbar disc herniation (LDH) is caused by protruded nucleus pulposus compressing the nerve root with fibrous ring rupture which leads to back and leg pain as the main symptom manifestation. In recent years, endoscopic transforaminal decompression technology has dominated the endoscopic MIS approach as an important surgical procedure for transforaminal Percutaneous Endoscopic Lumbar Discectomy (PELD). The posterolateral lumbar approach has become the main surgical approach for minimally invasive treatment of LDH [1,2]. However, due to the obstruction of high iliac crest, the application of posterolateral transforaminal technology for treating L5-S1 segment LDH can be difficult [3]. Due to the greater familiarity of the spine surgeon with posterior lumbar anatomy and similarity to conventional open surgical

procedures, many surgeons now prefer the more familiar percutaneous endoscopic interlaminar discectomy (PEID) for treating L5-S1 disc herniation. This approach and this technology could be applied for the L5-S1 segment, or even higher-level LDH [4,5]. Compared with the posterolateral transforaminal technique, the percutaneous interlaminar technique can also directly and still minimally invasively remove the intervertebral disc nucleus pulposus [6]. The PEID technique, however, needs to pass through the spinal canal to reach the protruded intervertebral disc target, and this kind of procedure may increase the risk of spinal canal scaring that can be a considered a negative consequence by some spine surgeons [7]. As a consequence, our endoscopic surgery group proposed percutaneous endoscopic medial foraminal decompression technique as an alternative minimally invasive surgical approach to remove the herniated disc and any contributory compression tissue and lateral recess, release nerve roots under direct vision and reduce the impact on spinal canal structures as much as possible. In view of the fact that there exists an area of safety in the posterior lumbar spinal canal structure between the existing nerve root and traversing nerve root, the premise of this technology is

directly to target disc herniation pressure area through this area with puncture, and percutaneous removal of the stable part of the lateral facet joint. Additionally, the experience of medial foraminal decompression for LDH was applied to LSS cases via established contralateral channel.

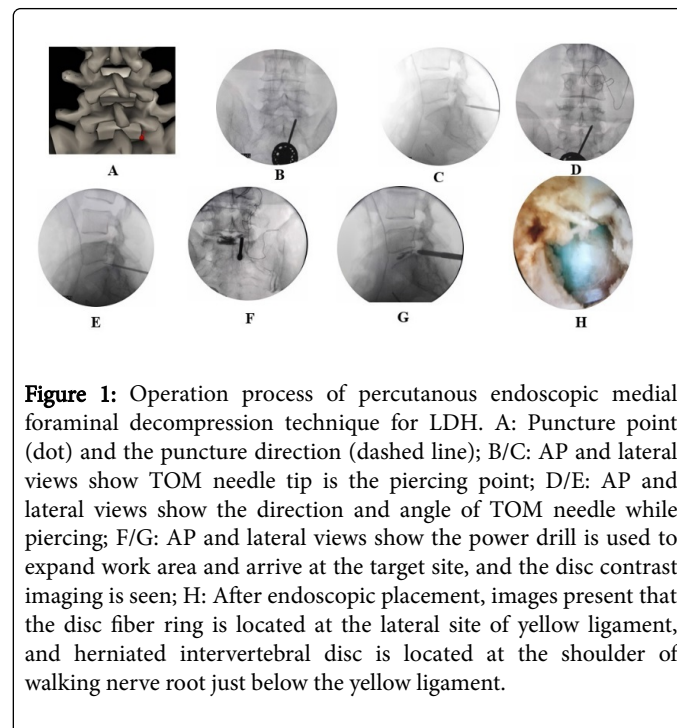
Materials and Methods

From April 2014 to January 2016, 32 patients with LDH and 11 patients with LSS were treated in our department with medial foraminal decompression technology. Among the thirty-two LDH and eleven LSS patients, there are 23 males and 20 females, aged 35-77 years, mean 44.6 ± 19.5 years; sickness duration of 3-120 months, an average of 7.3 ± 6.6 months. All of them were single-segment degeneration, of which 2 cases of L2-S3 segment, 4 cases of L3-S4 segment, 17 cases of L4-S5 segment, 20 cases of L5-S1 segment. The patients were characterized by varying degrees of low back pain with extremity radiculopathy, numbness or neurologic claudication, while suffering weakness of muscle strength, sensory, tendon reflex and other signs of nerve root damage. They were all treated by physical therapy, closed and other conservative treatments and underwent X-ray, CT and MRI inspection before surgery. The diagnosis for LDH or LSS was definite, while spondylolisthesis, instability, cancer, infection, and congenital malformations were excluded.

Surgical technique of endoscopic lumbar medial foraminal decompression

Ipsilateral channel established for LDH: Patients were placed in the prone and appropriate flexion position in the spine surgery bed. Operation was performed with intervertebral foramen minimally invasive surgery equipment. C-arm X-ray fluoroscopy identified skin landmarks for needle and cannula placement 1-2 cm below the targeted segment, 0.5-1 cm beside spinous process line as the body surface needle point, and the outer edge of intervertebral disc as puncture direction. 0.5% lidocaine was used for local anesthesia from skin fascia to the articular surface. After piercing from the puncture point with an 18 G needle, slowly advance the needle through under the guidance of C-arm X-ray. Insert MaxMore's "Tom-shidi" sheath and awl until reaching the junction of medial part of superior joint, tip of inferior joint and the lateral edge of interlaminar space. Slightly adjust the direction of the "Tom-shidi" needle according to the disc protrusion and punch the bone surface at the lateral edge of interlamina space. After penetrating the medial lamina adjacent to the upper facet, safely strike the awl into the bone to ensure that the tip of the needle was located at the pedicle medial margin, and then enter the lateral recess area directly to the intervertebral space plane. Carefully fix the position of TOM-shidi needle sheath, then use a 22 G imaging needle into the intervertebral disc, and infuse the mixed contrast agent 1 ml (iodine 4 ml+1% methylene blue 1 ml mixed liquid). Replace the guide wire, exit the TOM needle, cut 6-7 mm incision at the puncture point, and gradually expand the puncture path soft tissue along the guide wire application expansion device and then gradually use a bone drill of 4 mm to 8 mm diameter with nerve protection to grind part of the lamina and the articular facet joint. And then placed in a 7.5 mm diameter working sleeve under X-ray fluoroscopy monitoring to ensure that the working tube tip located at the medial margin of the pedicle (anteroposterior) and the protruded intervertebral space margin (lateral). During the drilling procedure, a custom unique design of the tongue-shaped sheath is used, that is, the tip of the casing is longer and the inserting drill is only the tip which rarely occupies the

space of the spinal canal. Afterwards, the intervertebral foramen endoscope is placed along the working sleeve. The specific operation flow is shown in Figure 1.



Contralateral channel established for LSS: If the case suffers from bilateral lateral recess or canal stenosis, the contralateral channel may be needed so as to ensure the facet-joint stability and decompression range. Choosing 1 cm beside the intervertebral segment spinous process middle line of the target segment as the surface needle point, and the puncture direction is the contralateral angle of interlamina, and 0.5% lidocaine is used for anesthesia from skin fascia to the articular surface. After piercing the 18 G puncture needle from the puncture point, slowly needle in with the guiding of C-arm X-ray, needle the tip to reach the junction of contralateral interlaminar angle through the back side of the ligamentum flavum. Then, implant the guide wire, replace the taper to expand the soft tissue channel along the guide wire, gently tap in the cone rod along the guide wire, and reach the junction of contralateral interlaminar angle. Pull out the guide wire, place "tongue" casing with 7.5 mm outside diameter along the cone rod. When the casing tip is back to the dural sac, gently hammer the casing stuck to the junction. Perspective is to ensure that: the tip margin of the sleeve is located at the contralateral medial margin of the pedicle (anteroposterior) and the intervertebral space margin or the posterior edge of the lower vertebra (lateral). Along the casing place suitable manual trephine, ring sawing part of the lamina and zygapophysis joint. Carefully appreciate the feel of the ring saw and ask the patient's feeling, remove immediately after feeling release. Seeing the "bone column" embedded in the ring saw, imbed the endoscope and perform microscopic treatment. Figure 2 shows the ipsilateral and contralateral channel establishment via a single skin incision and endoscopic decompression for LSS.

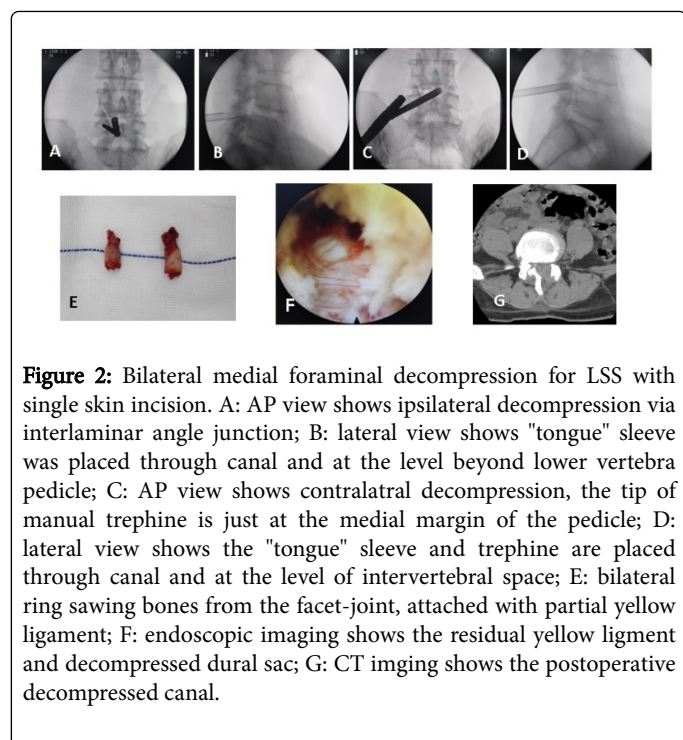


Figure 2: Bilateral medial foraminal decompression for LSS with single skin incision. A: AP view shows ipsilateral decompression via interlaminar angle junction; B: lateral view shows "tongue" sleeve was placed through canal and at the level beyond lower vertebra pedicle; C: AP view shows contralateral decompression, the tip of manual trephine is just at the medial margin of the pedicle; D: lateral view shows the "tongue" sleeve and trephine are placed through canal and at the level of intervertebral space; E: bilateral ring sawing bones from the facet-joint, attached with partial yellow ligament; F: endoscopic imaging shows the residual yellow ligament and decompressed dural sac; G: CT imaging shows the postoperative decompressed canal.

Neurological function and clinical efficacy evaluation

The Nerve Function Assessment Scale of the LDH Patients includes the Lumbar and Leg Pain Visual Simulation VAS Score, the Lumbar Disease JOA Score [8], the Oswestry Functional Disability Index (ODI) score [9] and SF-36 Quality of Life Score [10]. All patients were given neurological assessment, calculation; record the corresponding score before treatment, after discharge, after treatment 3-6 months and the last follow-up period, respectively. In addition, the improvement rate of lumbar decompression was evaluated by the Nakai standard [11] and JOA score improvement rate, and the clinical improvement rate=(last follow-up JOA score-preoperative JOA score)/(29-preoperative JOA score) × 100%.

Statistical methods

SPSS 13.0 statistical software was used for statistical analysis. The mean and standard deviation of the scores were calculated. The scores of neurological scores were compared with the number of paired design data. The difference was statistically significant with P<0.05.

Results

Medial foraminal decompression time 40-125 min, visual average bleeding <50 ml, 4-8 days in hospital. The follow-up time of 14-31 months, an average of 22.6 ± 7.9 months. Clinical efficiency was routinely evaluated in the recovery of neurological function (Tables 1 and 2).

Time points	n	VAS	JOA	ODI
Pre-operative	43	6.42 ± 3.58	13.24 ± 8.50	2.59 ± 1.38
Post-operative discharged	43	3.25 ± 1.74*	19.58 ± 10.03*	1.79 ± 0.97*
3-6 months post-operative	43	2.64 ± 0.99*	24.34 ± 10.47*	1.87 ± 1.35*
Final follow-up	43	2.37 ± 0.82*	23.57 ± 11.40*	1.90 ± 1.04*

*P<0.01, compared with preoperative scores

Table 1: The comparison of clinical evaluation indexes before and after surgery in patients with LDH or LSS.

Time points	n	SF-36							
		PF	RP	BP	VT	SF	RE	MH	GH
Pre-operative	43	0.51 ± 0.47	0.21 ± 0.36	0.46 ± 0.42	0.64 ± 0.37	0.57 ± 0.40	0.59 ± 0.89	0.70 ± 0.29	0.50 ± 0.21
Immediately after surgery	43	0.37 ± 0.61	0.15 ± 0.17	0.50 ± 0.37#	0.70 ± 0.52	0.60 ± 0.33#	0.52 ± 0.56	0.73 ± 0.34	0.57 ± 0.32#
Six months post-operatively	43	0.49 ± 0.61*	0.29 ± 0.26#	0.52 ± 0.40#	0.80 ± 0.34#	0.74 ± 0.28#	0.49 ± 0.68	0.75 ± 0.30	0.60 ± 0.36*
Final follow-up	43	0.40 ± 0.48#	0.30 ± 0.19#	0.21 ± 0.21#	0.82 ± 0.15*	0.77 ± 0.21#	0.59 ± 0.43	0.76 ± 0.47	0.64 ± 0.41*

*Indicates the significant difference compared with the preoperative scores (P <0.01), # indicates the statistically difference compared with the preoperative scores (P<0.05)

Table 2: The comparison of SF-36 before and after surgery in patients with LDH or LSS.

The results showed that VAS, JOA, ODI and SF-36 scores were maintained at a satisfactory level, which was significantly different from that before operation (<0.05); postoperative follow-up clinical

symptoms were more satisfactory to improve the basic symptoms of pain relief, quality of life increased, 3-6 weeks to return to work or resume daily life. According to the improvement rate of JOA, 22 cases

were excellent, 16 cases were good, and 5 cases were fair during the followed-up period. The satisfaction rate was 88.37%. One patient had postoperative radiation calf pain and foot numbness. One patient with posterior CT demonstrated the dorsal remnant of the dural sac, but had the basic relief of lower extremity pain. All patients had no dural sac tear, nerve root injury, intervertebral space infection, spinal cord hypertension, postoperative neuropathic pain and other complications.

Discussion

Lumbar foramen endoscopic technique mainly refers to the operation to get into the intervertebral foramen from the patient's lower back side or side rear (or flat or oblique way) and operate in the safe triangle area [12]. Making use of the operation area just outside the intervertebral disc ring under endoscopic vision, we could clearly distinguish herniated nucleus pulposus, nerve roots, dural sac and hyperplastic bone tissue, and remove the prominent pressure [13]. YESS and other transforaminal methods are considered to be the smallest trauma to patient and best-performing "cost-effective" minimally invasive therapy for LDH, reaching the target area through lateral approach, avoiding interference which traditional posterior open surgery or microendoscopic discectomy may have on the spinal canal and nerve, without affecting the stability of the spine [14,15]. However, posterolateral transforaminal technology has a longer learning curve for traditional surgeons without formal training [16-18]. So many scholars advocate PEID surgery for the treatment of LDH. Combining endoscopy with the traditional posterior laminectomy which the spinal surgeon is familiar with, the doctor has got satisfied clinical efficacy [19].

PEID technology can be seen as an auxiliary technique developed from PELD technology. It was mainly used in the special case of L5-S1 segment LDH, including Germany Professor Ruetten's first intervertebral approach full endoscopic technique and Korean Professor Choi's first inter-lamellar intermittent endoscopic technique [20,21]. First taking use of the L5-S1 lamellar interstitial wide anatomical features, Professor Ruetten developed the "full endoscopic" technique. Putting endoscopy in before the working tube casing into the spinal canal, biting the yellow ligament under direct eyes, identifying the nerve root and dural sac, carefully separating, getting into the working tube layer by layer, pushing the nerve root to the inside, removing the prominent disc in the nerve root shoulder is the feature of Ruetten's technique. The technical characteristics of Ruetten/

PEID technology are after the completion of self-puncture and skin cut, the operations are all under the endoscope [20]. Then, Professor Choi further drew lessons from Ruetten's technology with puncturing directly into the intervertebral disc through the interlaminar space, putting the guide wire into the guide needle, placing the expansion rods and working sleeve to squeeze the yellow ligament, dural sac and nerve root, firstly removing the intervertebral disc, and then gradually retreating the working endoscope to complete the decompression of dural sac and nerve root. The technical feature of Choi/PEID technology is characterized by first put working tube into the spinal canal then use endoscopy [21]. The specific operations of Choi and Ruetten techniques are as shown in Figures 3 and 4.

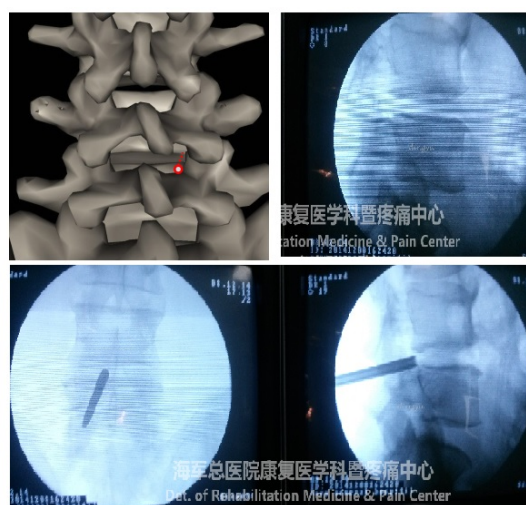


Figure 3: Operation process of Choi/PEID technique. A: PEID puncture point (dot) and the puncture direction (dashed line); B: Lateral view shows that the needle tip reaches the posterior edge of vertebral body; C: Working sleeve directly passes through vertebral canal and achieve the target disc, the character of Choi/PEID technology is to firstly place the working sleeve into vertebral canal before using the endoscope.

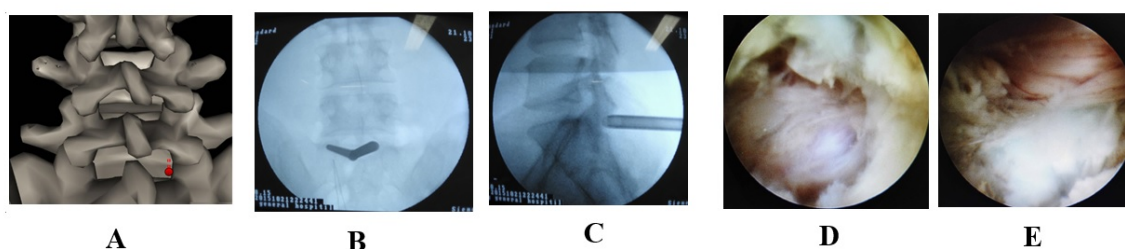


Figure 4: Operation process of Ruetten/PEID technique. A: PEID puncture point (dot) and the puncture direction (dashed line); B/C: AP and lateral views show that the working sleeve is displayed at the interlaminar gap adhering to the yellow ligament; D: Endoscopic imaging shows the dissected yellow ligament and the spinal canal structures; E: Step by step to separate under endoscope, showing herniated intervertebral disc and the compressed nerve root.

Although the PEID surgical approach to anatomical processes and open surgery which spine surgeons are familiar with are basically the same, but the need to cut the yellow ligament during surgery, pull the nerve root and dural sac with the catheter, inevitably cause interference to the spinal environment, resulting in the possibility of spinal canal adhesion, and even cause nerve root traction injury [22]. According to the author's experience, for the huge armpit LDH PEID surgery, the nerve root tension is significantly increased, and would simultaneously cause local edema and allergy. It was difficult to pull the nerve root away to carry out the shoulder operation, which lead to the intolerance of severe root pain. It would affect the conduct of the operation and arouse the postoperative complicated neuropathic pain.

In our opinion, medial foraminal decompression can be beneficial for LDH treatment and it is characterized by: (1) compared with the posterolateral transforaminal method, the puncture target is almost the same, which is at the superior articular process of the ventral side of the disc-ligament flavum gap. The approach of the technique to reach the lesion area is much shorter with a smaller trauma. By precisely positioning and puncturing, it could directly approach the target of the pressure and the fibrosis rupture. (2) Some scholars suggested that there be different approach of the PEID through the shoulder, axilla and shoulder-axillary, which effectively improved the efficiency of the clinical application of PEID method [23]. The medial foraminal decompression method is similar to the PEID approached through of shoulder. But the position direction is more lateral, which could reach the inside region of the intervertebral foramen. (3) The technique makes full use of the safe area among the intervertebral disc, the nerve root canal of the lower lamina, the inner edge of the upper articular process and the dural sac. It can quickly puncture and reach the target of the disc herniation without the help of endoscopy. The new type of the manual drill with the nerve protected blunt head is recommended by the authors. Considering the feeling and movement function response from the patients under the local anesthesia, the operation will be more efficient, safe and practical. In addition, the target of the bone to puncture and remove is located in the upper part of the articular process of the ligamentum punctatus. Placing the working tube at the outside of the yellow ligament may effectively reduce the stripping and the interference of the structure of the spinal canal. (4) The tip of the working tube is naturally located at the walking nerve root of the shoulder. When releasing the nerve root and removing the pressure-induced protrusion, there is no need to deliberately retract the nerve root, which can lower the probability of the severe root pain during the operation. There's a unique advantage of this method for the common shoulder type of the LDH. For the armpit and the ventral type of the LDH, generally, there is the need to remove some of the nucleus pulposus in the nerve root shoulder to reduce the nerve root tension and then pull it inside to remove the pressure target. Due to the fact that the grinding part of the articular process is non-stressed and there exists space on the lateral of the shoulder nerve root, usually there is less pain derived from nerve root pull compared with Ruetten or Choi/PEID method. (5) The puncture point is located at the lateral lamina and the region of the articular process and the surgical area was located near the medial margin of the pedicle. Due to a small amount of grinding off the articular process joints which is non-stress zone bone, it will not affect the segment stability. (6) The anatomical structure of the posterior surgery is clearer. The puncture angle and the direction is easier to control, which makes it conducive to judge accurately and find the lesions. The incidence of postoperative pressure residue is also lower. (7) For the rupture-type LDH, prominent nucleus pulposus is more often in a downward displacement. When

conducting the medial foraminal decompression treatment, the doctors should appropriately reduce the tilt angle of the puncture needle. The working tube can reach the lower level of the vertebral pedicle. But if the protrusion shifts too much further, the application of the method would have its limitations.

Conclusion

Combining with ipsilateral and contralateral channel operation, we could perform satisfactory decompression of the lateral recess and spinal canal stenosis. Because the working channel can go through the medial part of superior facet joint, the lateral recess will be opened during the grinding, which can effectively treat the cases of the lumbar degeneration with the lateral recess stenosis. If the method could be applied with the posterolateral foraminoplasty methods, there would be a chance to arouse the effect of the lumbar spinal stenosis with complete decompression around the nerve root [24]. Additionally, combining with the precise surgical tool, such as laser, the constant effective dissection and ablation for bone and soft tissue can be achieved for further decompression effects. The use of medial foraminal decompression technology to deal with lumbar spinal stenosis has several advantages: (1) Puncturing at one point can cause bilateral decompression. The use of special ring saw to grind the proliferation of small joints can effectively expand the spinal volume. (2) Due to the unique design of the tongue-shaped sleeve, the tip rarely occupies the space of the spinal canal; the patient experience is good with less pain and effectively avoids the crush to the nerve root and dural sac. (3) Grinding small amount of facet joint which has cohesion hyperplasia will not affect the stability of the responsibility phase due to the grinding off joint is non-stress zone bone. (4) The custom ring saw has a higher efficiency; you can quickly remove the facet joint of cohesion hyperplasia, more time-saving than the microscopic power system operation, and can neatly and completely remove the hyperplastic bone. Greatly save the difficulty and time of microscopic operation. (5) Due to the unique design of the tongue-shaped casing and cross-catheterization, the microscopic scope of the yellow ligament is greater than the usual working casing which is convenient to remove more thicken yellow ligament. (6) For the contralateral puncture catheter, because the tip of the casing points to the contralateral side of the lateral recess, we can more easily open the narrow side of the recess without grinding up too much facet joint that will be beneficial for lumbar spine stability, especially for high level lumbar spine stenosis.

The technique of medial foraminal decompression arised from the treatment of herniated disc herniation, and was later found to be more widely used in lumbar spinal stenosis. Given that the two diseases were treated with essentially the same technique and the main purpose of the study is to verify the safety, efficiency and indication of the clinical application, we did not classify specifically the lumbar degenerative diseases. This study showed that the effect using medial foraminal decompression treatment for LDH and LSS is good with less postoperative complications. The technique also has a unique advantage in dealing with L4-S5 and L5-S1 segment LDH. Patients can quickly return to work or the original state of life. Lumbar medial foraminal decompression experiences and techniques can be used for LSS treatment, showing a good application prospects and expandability. Anyway, this technique also has drawbacks, such as limitation for the treatment of extreme lateral LDH, disturbance of the spinal canal, and the operation skills must be rigorously trained, etc. In view of the application of the medial foraminal decompression

technique is just at the beginning, there still lacks a large number of cases and long-term follow-up clinical study. We believe that satisfactory surgical efficacy will promote the related anatomy and biomechanical research as well as prospective study and evaluation.

Acknowledgement

The authors acknowledge Professor Anthony T Yeung for his endoscopic surgery concept instruction and technical guidance.

References

1. Xin G, Shi-Sheng H, Hai-Long Z (2013) Morphometric analysis of the YESS and TESSYS techniques of percutaneous transforaminal endoscopic lumbar discectomy. *Clin Anat* 26: 728-734.
2. Sanusi T, Davis J, Nicassio N, Malik I (2015) Endoscopic lumbar discectomy under local anesthesia may be an alternative to microdiscectomy: A single centre's experience using the far lateral approach. *Clin Neurol Neurosurg* 139: 324-327.
3. Yeung AT, Yeung CA (2003) Advances in endoscopic disc and spine surgery: foraminal approach. *Surg Technol Int* 11:255-263.
4. Tonosu J, Oshima Y, Shibo R, Hayashi A, Takano Y, et al. (2016) Consideration of proper operative route for interlaminar approach for percutaneous endoscopic lumbar discectomy. *J Spine Surg* 2: 281-288.
5. Li ZZ, Hou SX, Shang WL, Song KR, Zhao HL (2015) The strategy and early clinical outcome of full-endoscopic L5/S1 discectomy through interlaminar approach. *Clin Neurol Neurosurg* 133: 40-45.
6. Kim CH, Chung CK, Sohn S, Lee S, Park SB (2014) The surgical outcome and the surgical strategy of percutaneous endoscopic discectomy for recurrent disk herniation. *J Spinal Disord Tech* 27: 415-422.
7. Karikari IO, Isaacs RE (2010) Minimally invasive transforaminal lumbar interbody fusion: a review of techniques and outcomes. *Spine* 35: 294-301.
8. Dohrmann GJ, Hsieh JC (2014) Long-term results of anterior versus posterior operations for herniated cervical discs: analysis of 6000 patients. *Med Princ Pract* 23: 70-73.
9. Yilmaz H, Ertürk AR, Karatas A, Atci İB, Yurt A, et al. (2016) Posterior laminoforaminotomy in the treatment of lateral cervical herniated disc and foraminal stenosis. *Turk J Med Sci* 46: 424-429.
10. Yuzawa Y (2011) The interspinous ligament should be removed for the decompression surgery with the case of lumbar spinal canal stenosis. *Arch Orthop Trauma Surg* 131: 753-758.
11. Sivan M, Sell B, Sell P (2009) A comparison of functional assessment instruments and work status in chronic back pain. *Eur J Phys Rehabil Med* 45: 31-36.
12. Djurasovic M, Glassman SD, Howard JM, Copay AG, Carreon LY (2011) Health-related quality of life improvements in patients undergoing lumbar spinal fusion as a revision surgery. *Spine* 36: 269-276.
13. Zhang WC, Li ZZ, Yuan C (2011) Treatment of lumbar spinal stenosis in the elders by micro-endoscopic discectomy. *Zhongguo Gu Shang* 24: 408-410.
14. Yokosuka J, Oshima Y, Kaneko T, Takano Y, Inanami H, et al. (2016) Advantages and disadvantages of posterolateral approach for percutaneous endoscopic lumbar discectomy. *J Spine Surg* 2: 158-166.
15. Hurday Y, Xu B, Guo L, Cao Y, Wan Y, et al. (2017) Radiographic measurement for transforaminal percutaneous endoscopic approach (PELD). *Eur Spine J* 26: 635-645.
16. Yeung AT (2007) The evolution and advancement of endoscopic foraminal surgery: One surgeon's experience incorporating adjunctive technologies. *SAS J* 1: 108-117.
17. Jasper GP, Francisco GM, Telfeian AE (2013) Clinical success of transforaminal endoscopic discectomy with foraminotomy: A retrospective evaluation. *Clin Neurol Neurosurg* 115: 1961-1965.
18. Hsu HT, Chang SJ, Stephen S, Chai CL (2013) Learning curve of full-endoscopic lumbar discectomy. *Eur Spine J* 22: 727-733.
19. Jacobs WCH, Arts MP, Van Tulder MW, Rubinstein SM, Van Middelkoop M, et al. (2012) Surgical techniques for sciatica due to herniated disc: A systematic review. *Eur Spine J* 21: 2232-2251.
20. Teli M, Lovi A, Brayda-Bruno M, Zagra A, Corriero A, et al. (2010) Higher risk of dural tears and recurrent herniation with lumbar micro-endoscopic discectomy. *Eur Spine J* 19: 443-450.
21. Kaushal M, Sen R (2012) Posterior endoscopic discectomy: Results in 300 patients. *Indian J Orthop* 46: 81-85.
22. Ruetten S, Komp M, Merk H, Godolias G (2009) Full-endoscopic anterior decompression versus conventional anterior decompression and fusion in cervical disc herniations. *Int Orthop* 33: 1677-1682.
23. Choi DJ, Jung JT, Lee SJ, Kim YS, Jang HJ, et al. (2016) Biportal endoscopic spinal surgery for recurrent lumbar disc herniations. *Clin Orthop Surg* 8: 325-329.
24. Xie TH, Zeng JC, Li ZH, Wang L, Nie HF, et al. (2017) Complications of lumbar disc herniation following full-endoscopic interlaminar lumbar discectomy: A large, single-center, retrospective study. *Pain Physician* 20: E379-E387.