

Case Report

Open Access

Penicillosis in Patient of Acute Kidney Injury with Adenocarcinoma Lung: A Rare Presentation

Upma Narain^{1*} and Arvind Gupta²

¹Department of Microbiology and Immunology, Tejas Microdiagnostic, Allahabad, Uttar Pradesh, India

²Department of Nephrology, Moti Lal Nehru Medical College, Allahabad, Uttar Pradesh, India

Abstract

Fungal infections are an increasing problem in immunocompromised patients. Members of the genus *Penicillium* rarely cause infections and are primarily limited to strains of the species *Penicillium marneffei*. We are reporting a successfully treated case of culture proven pulmonary Penicillosis caused by *Penicillium chrysogenum* on the onset of Acute Kidney Injury in a patient of adenocarcinoma lung.

Keywords: Penicillosis; Acute kidney injury; Broncho alveolar lavage; *Penicillium chrysogenum*; Adenocarcinoma lung; Haemodialysis

Introduction

Penicillosis is an invasive fungal infection that primarily occurs in the south east and eastern regions of Asia [1]. *Penicillium* species are among the most common fungi in the environment and are usually considered non-pathogenic to humans [2]. However in immunocompromised host they can be virulent pathogen and can cause death [3]. Acute kidney injury (AKI) is common in cancers [4] and patients on cytotoxic drugs are susceptible to opportunistic infections. Significant proportion of cancer patients are affected by pulmonary infections. Successful outcome requires early identification, aggressive and effective treatment of the infection. Herein, we report the case of successful treatment of concomitant pulmonary Penicillosis and acute kidney injury in the patient of adenocarcinoma lung.

Case Report

He was the diagnosed case of diabetes mellitus, hypertension, hypothyroidism and moderately differentiated adenocarcinoma lung. After completion of 16th cycle of maintenance chemotherapy (Gemcitabine), he was readmitted with complains of fever, restlessness, cough, weakness, anemia, hypertension (180/90) and derranged kidney function. Next day he was referred to nephrology centre for further management. Before admission he was anemic, dyspnoeic, anuric, derranged renal function and was presenting with non-productive cough. On admission investigations revealed 100°F temperature, 86% S.P.O₂, 180/90 BP, 42/min RR, 140/min PR, S. urea 115 mg/dL, S. creatinine 4.43 mg/dL, S. Sodium 120 mmol/L, S. Potassium 41mmol/L. Urinalysis was not specific. Dysmorphic Red blood corpuscles were absent.

Chest examination revealed bilateral fine crepts and ronchi hence BIPAP support was given. Intravenous nitroglycerine started to control hypertension and antidiabetics, diuretics were added along with the conservative treatment of AKI. Various differential diagnosis in this setting was ruled out by appropriate investigations e.g. tumour lysis syndrome, contrast nephropathy, thrombotic thrombocytopenic purpura, obstructive uropathy and pre renal factors.

X-ray (Figure 1) showed bilateral non-homogeneous opacity in lower zones. We requested for Bronchoscopy (Figure 2) on urgent basis and investigations were sent immediately to the lab. After stabilization Bronchoscopy was done and it revealed frothy, blood tinged, mucopurulent lavage. Bronchoscopist abandoned the procedure due to the seriousness of patient as SPO₂ was going down. Microscopy of Broncho alveolar lavage (BAL) revealed occasional gram positive

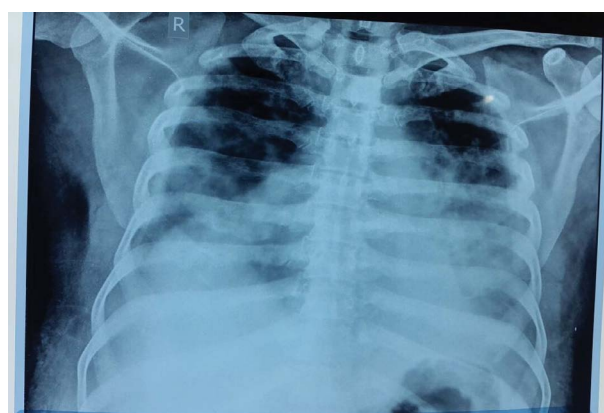


Figure 1: X-ray showed bilateral non-homogeneous opacity in lower zones.

cocci, conidia and hyphae like structures on gram staining. Lacto phenol cotton blue film confirmed the presence of fungal elements and acid fast bacilli were negative. On second day he had cough with streaky haemoptysis. Mantoux was negative. Urine and preliminary blood culture were sterile after 48 hours of incubation at 37°C. After third day sabourad dextrose agar showed tiny grayish green colonies of *Penicillium chrysogenum* (Figure 3). On fifth day Hb was 7.5, Total Leukocyte Count (TLC) 13100 cells/cumm, with 88% neutrophils 12% lymphocytes, RBS 112, S. urea 104 mg/dL, S. creatinine 5.12 mg/dL, 2D Echo showed LV 55%, and kidneys were normal sized.

Patient was started with 5 mg/kg Liposomal amphotericin-B along with 100 mg itraconazole twice a day for 20 days and supportive conservative treatment was given to manage AKI. Patient did not show any improvement during conservative therapy. His renal function was

***Corresponding author:** Upma Narain, 62, Jawahar Lal Nehru Road, Allahabad, Uttar Pradesh, 211002, India, Tel : +919415253337; E-mail: upmanarain@gmail.com

Received: March 08, 2016; **Accepted:** March 22, 2016; **Published:** March 29, 2016

Citation: Narain U, Gupta A (2016) Penicillosis in Patient of Acute Kidney Injury with Adenocarcinoma Lung: A Rare Presentation. J Nephrol Ther 6: 241. doi:10.4172/2161-0959.1000241

Copyright: © 2016 Narain U, et al. This is an open-access article distributed under the terms of the Creative Commons Attribution License, which permits unrestricted use, distribution, and reproduction in any medium, provided the original author and source are credited.

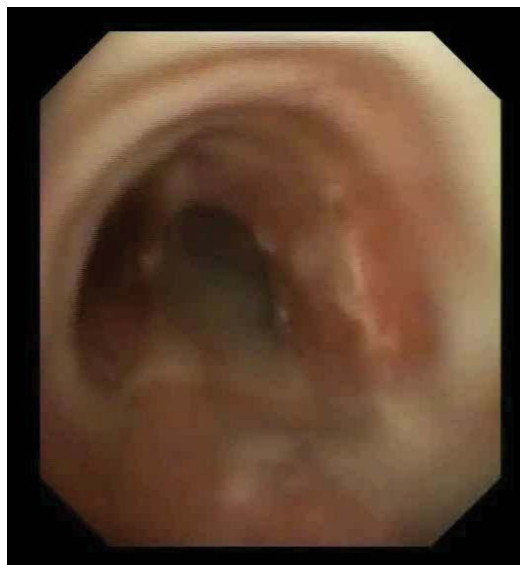

Figure 2: Bronchoscopic view.

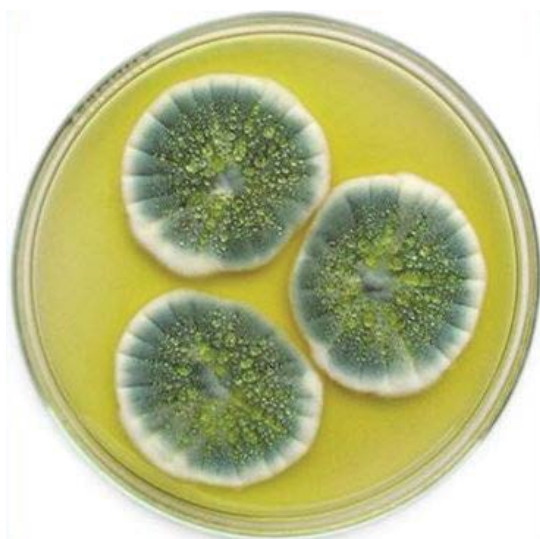

Figure 3: Macroscopic picture of *Penicillium chrysogenum*.

deteriorated and patient developed metabolic acidosis. Hence, he was put on haemodialysis for the indication of anuria. During dialysis five packs of packed red blood cells, three units of 100ml fresh frozen plasma and albumin were infused. Patient went into diuretic phase and most of the symptoms were resolved. After seven days of treatment, Hb was 10.4, 6100 cells/cumm TLC, 75% Neutrophils, 25% lymphocytes 25.0, 80 mg/dl S. urea and creatinine 3.0 mg/dl. Kidney biopsy was done later on to get the exact histology against various differential diagnosis in cancer patient. According to biopsy tubules showed patchy areas of acute tubular necrosis, RBCs and WBC casts were seen in some tubules. Tubular atrophy comprised about 15-20% of cortex. Interstitium showed mild edema. Mild diffuse interstitial inflammation were seen comprising chiefly of eosinophils, few lymphocytes and plasma cells. Arteries and arterioles did not show any significant diagnostic abnormality. Direct Immunofluorescence showed 3-4 glomeruli which

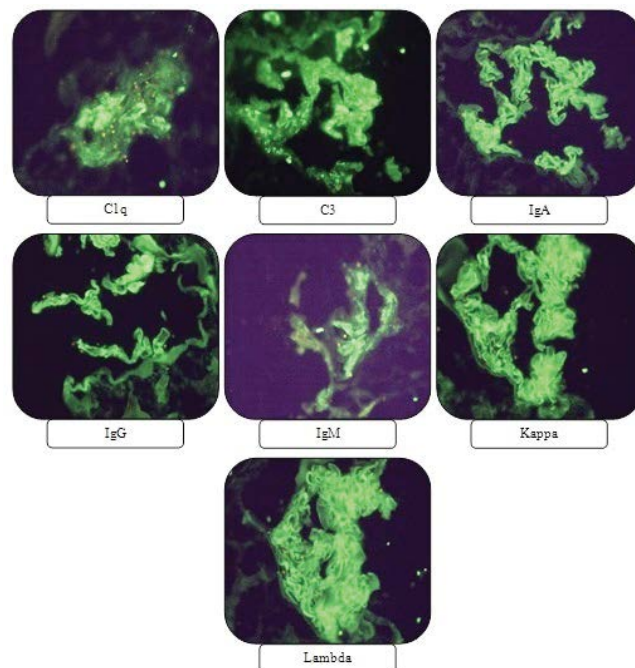


Figure 4: Direct Immunofluorescence slides of renal biopsy.

did not show staining for IgG, IgA, IgM, C3, C1q, Kappa and Lambda. Nonspecific trap noted for C3, C1q and focally for IgM. Therefore findings favour to Acute Tubular Necrosis (Figure 4).

Discussion

Alterations of the immune system in uremics constitute a complex issue. On one hand, hypercytokinemia is a typical feature of uremia, likely due to accumulation of pro-inflammatory cytokines as a consequence of decreased renal elimination and/or increased generation following induction by uremic toxins, oxidative stress, volume overload, comorbidities, etc. [5,6]. On the other hand, uremia is associated with immunosuppression due to the impact of the uremic milieu and a variety of associated disorders exerted on immunocompetent cells. Hence uremia is associated with a state of immune dysfunction characterized by immunodepression that likely contributes to the high prevalence of infections [7]. The genus *Penicillium* is ubiquitous, generally saprophytic, and distributed worldwide [8]. However, some species are known for their positive or negative effects on humans. The positive impacts include their use in food fermentation and the production of drugs, and the negative effects are related to the production of Mycotoxins, the induction of hypersensitivity reactions (e.g. asthma and extrinsic allergic alveolitis) and infection of the humans [9]. Members of the genus *Penicillium* rarely cause infections and are primarily limited to strains of the species *Penicillium marneffei* [10]. As reviewed by Lyratzopoulos et al. [11], only fifteen cases of invasive infections caused by species other than *T. marneffei* have been linked to the *Penicillium* genus worldwide. More recently, other *Penicillium* species, such as *P. chrysogenum*, *P. piceum* and *P. purpurogenum*, were found to be associated with these infections [12]. In the past, *Penicillium chrysogenum* has been recognized as an invasive fungus in only three cases of human disease [8,13]. Apart from toxins liberated by fungi, one of the specific pathogenic factors of *Penicillium chrysogenum* causing invasive infection is its ability to grow at 37°C [14] because majority of *Penicillium* species grow below

37°C; however, exceptions include *P. citrinum*, *P. decumbens* and *P. janthinellum*. In our opinion, both the *Penicillium chrysogenum* ability to grow at 37°C and patient's uremic state contributed for the development of fungal pneumonitis in the patient of adenocarcinoma lung. Pulmonary infections with fungi, including *Penicillium* species, are associated with much higher mortality rates in patients with nosocomial infections or infections complicating organ failure. Patients with *Penicillium* species infections have been treated successfully with itraconazole, amphotericin B, or fluconazole. However, some patients with conditions caused by *Penicillium* species have died despite treatment with ketoconazole, amphotericin B, or itraconazole [15]. That is why we gave combined therapy of Amphoterecin B and itraconazole in our case and finally we achieved successful outcome. This is the first study where we made a striking and novel observation of Penicillosis caused by *Penicillium chrysogenum* on the onset of Acute Kidney Injury in a patient of adenocarcinoma lung. The noteworthy observation is we diagnosed early and attained successful outcome with recovery of kidney function.

Conclusion

It concludes that if identified, diagnosed and treated promptly with the help of X-ray, bronchoscopy, direct microscopy of the specimen and supportive appropriate therapy patient may lead to better outcome which is relatively uncommon but not impossible.

Declaration

The authors declaring that the results presented in this paper have not been published previously in whole or part, except in abstract format.

References

- Chakrabarti A, Slavin MA (2011) Endemic fungal infections in the Asia-Pacific region. *Med Mycol* 49: 337-344.
- Raper KB, Thom C (1968) *Penicillium digitatum*. A Manual of the *Penicillia*. Hafner Publishing Company (Open Library).
- Mok T, Koehler AP, Yu MY, Ellis DH, Johnson PJ, et al. (1997) Fatal *Penicillium citrinum* pneumonia with pericarditis in a patient with acute leukemia. *J Clin Microbiol* 35: 2654-2656.
- Lam AQ, Humphreys BD (2012) Onco-nephrology: AKI in the cancer patient. *Clin J Am Soc Nephrol* 7: 1692-1700.
- Kimmel PL, Phillips TM, Simmens SJ, Peterson RA, Weihs KL, et al. (1998) Immunologic function and survival in hemodialysis patients. *Kidney Int* 54: 236-244.
- Stenvinkel P, Ketteler M, Johnson RJ, Lindholm B, Pecoits-Filho R, et al. (2005) IL-10, IL-6, and TNF-alpha: central factors in the altered cytokine network of uremia—the good, the bad, and the ugly. *Kidney Int* 67: 1216-1233.
- Kato S, Chmielewski M, Honda H, Pecoits-Filho R, Matsuo S, et al. (2008) Aspects of immune dysfunction in end-stage renal disease. *Clin J Am Soc Nephrol* 3: 1526-1533.
- D'Antonio D, Violante B, Farina C, Sacco R, Angelucci D, et al. (1997) Necrotizing pneumonia caused by *Penicillium chrysogenum*. *J Clin Microbiol* 35: 3335-3337.
- Yang SH, Dou KF, Song WJ (2010) Prevalence of diabetes among men and women in China. *N Engl J Med* 362: 2425-2426.
- Tsang DN, Li PC, Tsui MS, Lau YT, Ma KF, et al. (1991) *Penicillium marneffei*: another pathogen to consider in patients infected with human immunodeficiency virus. *Rev Infect Dis* 13: 766-767.
- Lyratzopoulos G, Ellis M, Nerringer R, Denning DW (2002) Invasive infection due to *penicillium* species other than *P. marneffei*. *J Infect* 45: 184-195.
- Geltner C, Lass-Flörl C, Bonatti H, Müller L, Stelzmüller I (2013) Invasive pulmonary mycosis due to *Penicillium chrysogenum*: a new invasive pathogen. *Transplantation* 95: e21-23.
- Houbraken J, Frisvad JC, Samson RA (2011) Taxonomy of *Penicillium* section *Citrina*. *Stud Mycol* 70: 53-138.
- Pitt JI (1994) The current role of *Aspergillus* and *Penicillium* in human and animal health. *J Med Vet Mycol* 32 Suppl 1: 17-32.
- Oshikata C, Tsurikisawa N, Saito A, Watanabe M, Kamata Y, et al. (2013) Fatal pneumonia caused by *Penicillium digitatum*: a case report. *BMC Pulm Med* 13: 16.