

Pediatric Spine Trauma

Mehmet Resid Onen and Sait Naderi*

Department of Neurosurgery, Umraniye Teaching and Research hospital, Turkey

Abstract

Although pediatric spine traumas are seen less compared to adults, they display particular anatomical differences and biomechanical behaviors. They also differ in themselves from infancy to early childhood. All these differences cause some difficulty in diagnosis. Also the treatment procedures may require a different approach than they would for adults. In this study, main topics regarding diagnosis and treatment of the pediatric spinal traumas will be discussed.

Keywords: Pediatric; Spine; Trauma; Spinal fractures; Age distribution

Introduction

Each year approximately 150,000 spinal trauma cases are reported in the US. Pediatric spinal traumas (PST) are relatively rare. PST forms about 1-10% of all spinal traumas. Because different anatomical structures and different biomechanical factors play roles in each childhood age group, the picture changes. The large part of PSTs is seen between. Cervical traumas form 70-75% of these cases [1] the ratio of cervical traumas to all spinal traumas in adults is about 40%. Thoracic and lumbosacral injuries are rare and they are seen more frequently in the older age group. While the PSTs develop most frequently as a result of falling at the age of 10 and below, above 10 they are connected to high-energy traumas such as motor vehicle accidents [1].

Prevalence

Spine traumas indicate a bimodal distribution such as between the ages 15-25 and above 50. The average most frequent age of prevalence is 33. PSTs form the 1-10% group in this distribution. Frequency of the spinal traumas from birth to age 16 is about 6% [1-3].

Biomechanical features of pediatric spine

Various characteristic differences appear in the pediatric and adult spine (Table 1). The basis of these differences is the development process of the bone and muscle maturation. The bone maturation in ages 9-10 nears adult bone maturation. Hence, injury developed in the spinal traumas formed after ages 10-12 substantially resembles adult traumas. Ligament elasticity, laxity and bone maturation have not been completed in the childhood period. Facet joints are in smaller and more horizontal structure. Endplates are in cartilage consistence [3]. In addition, compared to adults, the muscle development is weak. While the more ligament laxity in children is a protective factor in low energy traumas, it turns into a negative factor in the high-energy traumas as it will lose its protective feature. The spine can be stretched out up to 2 cm by axial tensile force in the early childhood period. But the spinal cord can tolerate a maximum of 3-5 mm. Because of these factors, the spine and spinal cord under the spinal traumas formed in the childhood period differ from the ones in adults. Compared to a child's spine, an adult's spine under high stress breaks more easily; however, an adult's spine ensures better spinal cord protection under the trauma than the pediatric spine. Also in the pediatric cases, wideness of the spinal channel in particular increases the tolerance in protection under trauma.

The basic difference between the pediatric spine and the adult spine is the existence of the epiphysis in the former. At the same time, more cartilage – ossify bone ratio causes more elasticity in the vertebrae; however, its resistance against mechanical pressure is less compared to adult vertebrae. In the clinical and experimental studies, pediatric

spine fractures happened generally in the vertebra bodies and between the cartilage surfaces of endplates and calcify surfaces [4]. In children, water makes about 80% of intervertebral disks. This rate decreases to 70% at the ages of 12-13 and this decrease lowers with age. This high water ratio considerably increases the shock absorption power of the disks in children [5].

Adult spine structure includes an adaptive protection system against overloads. It accommodates the anatomy in itself that carries the normal body loads on the axial and sagittal plane to the hips and legs on the vertical plane. Sagittal balance and natural kyphos-lordosis angles are important defense mechanisms and they ensure neutral load distribution as well. Since these adaptive structures have not yet been formed on the sagittal and coronal plane in the pediatric spine, load distribution cannot occur sufficiently under trauma [6,7] Since the ligament laxity is more abundant and the facet joints are located horizontally in children compared to adults, they ensure a wider physiological movement range. As odontoid is not ossified in the upper cervical and transverse ligament is more elastic, the atlanto-dental index is more abundant in children than it is in adults.

One of the anatomical differences is that the ratio of head weight to body weight in children is higher compared to adults. Having more head weight and not having sufficiently developed neck muscles result in more frequent cervical flexion extension injuries. This ratio difference continues until about age eight. Epiphyses points causing the pediatric spine, grow form the weakest points against axial tensile force and sagittal loadings [8].

Etiology

With high-energy traumas to children whose consciousness cannot be examined, patients with local sensitivity in the spine trace and with abdominal thorax injury, the possibility of spinal injury increases [4].

In pediatric cases, some predisposing factors increase the possibly of post-trauma spine injury. Predisposing factors such as Down syndrome, Marfan syndrome, spinal arthritis, spinal trauma history, Klippel-feil syndrome, Morquio syndrome, and Larsen syndrome increase the risk [4,8,9].

*Corresponding author: Prof. Sait Naderi, Department of Neurosurgery, Umraniye Teaching and Research hospital, 34760 Istanbul, Turkey, Tel: +90 532 2621318; E-mail: saitnaderi@yahoo.com

Received December 31, 2014; Accepted February 09, 2015; Published February 11, 2015

Citation: Onen MR, Naderi S (2015) Pediatric Spine Trauma. J Spine 4: 211. doi:10.4172/21657939.1000211

Copyright: © 2015 Onen MR, et al. This is an open-access article distributed under the terms of the Creative Commons Attribution License, which permits unrestricted use, distribution, and reproduction in any medium, provided the original author and source are credited.

0-2 ages	2-10 ages	10-16 ages
<ul style="list-style-type: none"> • High head/body ratio • Weak neck muscles • Elastic ligaments • Non-ossified vertebrates • Horizontally located facets • High disk distance • More than 88% water content of disk • Non ossified endplate • Vertebra corpus in the form of wedge • Existence of epiphyses 	<ul style="list-style-type: none"> • Head/body ratio nears normal • Muscles become stronger • Elastic ligaments • Increased vertebra calcification • Stronger horizontal facet structure, it nears normal • High disk distance • More than 80% water content of disk • Non ossified endplate • Vertebra corpus in the form of wedge • Existence of epiphyses 	<ul style="list-style-type: none"> • Substantially same with adult spine structure • Ligament elasticity too close to the adult spine • Head/neck ratio is in the normal limits • Disk height close to the adult • Epiphyses is closed on a large extent

Table 1: Biomechanical and anatomic differences in the pediatric spine structure according to age groups.

Cervical trauma poses a risk for multiple pregnancies having vaginal delivery, high birth weight in the breech presentation in the neonatal period [9].

The most serious risks in PSTs from birth to eight years are motorized vehicle injuries, falling and child abuse. From nine to puberty, motor vehicle injuries and sport injuries are the most important PST reasons [4,8,9].

Localization

Spine levels of PSTs are affected in the area where trauma effected change. Nevertheless, according to age levels, maturation and biomechanical force distribution in the ligamentous and bone development increase or decrease the spinal trauma possibility on some levels. In children under eight years of age, upper cervical traumas happen 2-3 times more often compared to adults. Lower cervical traumas, and thoracic and lumbar traumas are rare in this age group. In the preadolescence and adolescence periods, lower cervical area injuries are the most frequent traumas followed by thoracolumbar junction injuries. Adolescence period spinal trauma distribution shares similarity with adult period distribution [1,6,9].

Clinical examination

Approach to the pediatric trauma cases starts in the trauma area, as is the case with adults. Pediatric cases considered to be exposed to spinal trauma cannot be examined as easily as adults. Children with trauma are hard to talk to; they cannot fulfill neurological examination instructions. Sensitivity examination findings are not dependable. Therefore, all measures must be taken to accept all trauma cases seriously. Classic cervical neck collars cannot ensure sufficient protection. So, to limit the neck movements of children who are taken in trauma stretcher, objects limiting movement must be placed on both sides of the head. Since the size of the head under eight years is bigger, it causes the formation of cervical flexion posture in the children on plain trauma stretcher. Raising the dorsum part with support helps to prevent it [10].

Especially with children exposed to high-energy traumas, care must be taken by accepting the existence of spinal trauma during transport. Occurrence mechanisms of trauma, face injuries, chest wall and abdominal injuries are the factors increasing the possibility of spinal injuries.

In the examination, the spinal colon must first be examined thoroughly to see any black-and-blue mark, asymmetry, intersperse width and torticollis. After a detailed neural examination, any local sensitivity must be checked. Since ligament laxity is high in children, one must be very careful about traction.

Radiological examination

In the pediatric trauma cases, after vital functions are assured, at

least two directional vertebra graphies must be taken to assess the spinal colon. Primarily, in the centers that have no detailed CT examination opportunity, facet joints, pedicle and lateral masses can be evaluated with oblique graphies. Dynamic imaging examination such as flexion and extension cervical graphies, may be risky in the severe trauma cases and in the patients whose consciousness examination cannot be performed. From the point of odontoid fracture, open mouth odontoid graphy can be taken. However, there are also those who hold that open mouth odontoid graphy is not dependable under the ages of 8 [11,12]. Plain graphies, radiographies give 60-70% dependable results in PSTs. The cases having spinal cord injuries but where pathology cannot be detected by radiology (SCIWORA) can be seen in pediatric spinal traumas [13,14]. SCIWORA phenomenon is most frequently seen in cervical area. In these cases, without determining bone and ligamentous injury by radiology, transection or injury of the spinal cord avulsion in various levels can be seen. Actually this definition belongs to pre-MR period, and it only reflects that the direct graphy is normal; however, ligament, disk and spinal cord changes can be identified in MR.

In pediatric spinal visualization, some findings that are seen as pathologic findings in adults can be regarded as physiologic (Table 2). Atlanto-dental distance (ADI) and spinal cord space (SAC) are the primary ones among them. While the ADI upper limit is 3 mm in adults, up to 5 mm can be accepted as normal in children. SAC distance in young children must be longer or equal to the distance between minimum 13 mm and odontoid C1 front arcus. Pseudo-subluxation seen in the lateral plain graphy in the flexion posture at a distance of C2-C3 or C3-C4 is a physiologic finding in children (Table 2) [15]. Differentiating pathologic subluxation and physiologic subluxation, posterior vertebra corpus line (thick dotted line) used in adults is deceptive. For this purpose, "Swischukline" known as posterior laminar line is more dependable [16].

In pediatric cases, posterior cervical arks are physiologically open until certain ages. Posterior arks of atlas and axis are open until the ages 3-6. At the same time, ossification of odontoid might take until the age of 12.

Evaluating bone pathologies in spinal traumas, CT is the golden standard. Yet, one is exposed to 30 times more radiation in CT than plain graphy [17]. Compared to adults, children are more sensitive to radiation. Malignity development risk on thyroid gland and bone marrow tissues rises [18-20]. Although it seems proper to evaluate local CT examination to prevent unnecessary radiation exposure in pediatric cases, many centers routinely carry out thorough spinal scan in the suspected trauma cases. In a prospective multicenter study, when CT sensitivity in trauma cases has been 93-100%, x-ray reliability has been found 33-74% [19-21].

In pediatric cases taken to the emergency room, spinal trauma suspension comes to mind with some criteria found (Table 3) [22]. In the cases with these criteria, it is advisable to consult such examinations as Ct and MRI.

Sliding forward of C2 on the C3	Cervical Subluxation	Up to age 8
Odontoid ossification line	Odontoid fracture	Up to age 10
Atlanto dental index up to 5 mm	Atlanto-axial dislocation	Up to age 6
Bifid C1 anterior arcus	C1 fracture	Up to age 3
More specific wedge vertebra in upper cervical	Compression fracture	Up to age 5
No cervical lordosis	Instability, pain	Up to age 16

Table 2: Physiological wrong assessment findings seen on x-ray in pediatric cases.

Low risk cases to be tracked with plain graphy	High risk cases requiring further examination with CT and MRI
<ul style="list-style-type: none"> No cervical midline sensitivity No intoxication syptom No change of consciousness No neurological deficit No painful distractive injury 	<ul style="list-style-type: none"> Cervical midline sensitivity Focal neurological deficit Impaired consciousness Intoxication symptom Painful distractive injury Closed-tongue children

Table 3: Criteria causing suspicion of pediatric spinal trauma.

In planning the treatment, MRI presents important advantages in diagnosing soft tissue and spinal cord injury connected to spinal trauma. It is understood that the complications developed in many cases treated by making diagnosis with plain graphy and CT in the previous years, originated from the lack of diagnosis [2,23]. In some SCIWORA cases, the spinal cord edema that will disclose the injury is located with MRI. By further development of the MRI techniques, determining the pathology in all SCIWORA cases might be possible. All spinal MRI examinations in high-energy trauma cases are required for not missing possible pathologies [24]. In MRI, in the first 6 months of life, vertebra corpuses appear like hypo intense in T2 and T2, endplates like hyper intense on cross sections and as hypo intense in T2 cross sections. Becoming vertebra curvature in natural curvature after age 2, the MRI findings appear like hyper intense in T1 and like hypo intense in T2 approaching the adult signal feature.

Spinal Cord Injury without Radiographic Abnormality (SCIWORA)

This concept was first defined in 1982 by Pang and Wilberenger [14]. It was used for patients where spinal cord injury clinic was diagnosed without having abnormality in x-ray, CT, myelography in spinal cord injury especially under the age of 8 when MRI was not used daily. Because spine elasticity involves more than the spinal cord especially in children under 8 years old, it was thought that spinal cord axonal injury developed in axial distractive traumas. This pathology was reported in many trauma cases developing from birth trauma until 16 years of age. It can be rarely seen in adults. Its rate of incidence decreased largely with the use of MRI. It became evident that big changes occurred in the extraneural and intraneural tissues in some of SCIWORA cases. Spinal cord edema can be seen as iso-intense in T1 cross sections and hyper-intense in T2 cross sections [25,26]. Retrospective has been studied towards cases for which SCIWORA diagnosis was made and MRI was taken. While MRI findings were normal in 54 of these cases, in 15 of this cases pathologies such as edema in the spinal cord in MRI were determined [27]. It can develop connected to reasons such as sport injuries, obstetric traumas, penetran injuries, fall, and electric shock [27]. Neurologic loss can be on a wide range from simple paresis up to complete paresis.

In these cases, with the use of orthosis limiting the neck movements, 90-95% of neurological findings completely recover [25,27].

Cervical Spinal Traumas

Atlanto-occipital dislocation

Atlanto-occipital dislocation is an upper cervical pathology generally associated with mortality and its diagnosis can only be made by autopsy. Its possibility of being encountered in children is high because of anatomic susceptibility. The chances for survival have increased nowadays with early emergency intervention. Atlanto-occipital passage area is an area supported by ligamentous structures rather than by bone and joint support. Since ligaments are looser in childhood, and occipital condyles are sharper and cup type, risk is higher [28].

Diagnosis is made with difficulty via physical examination. Increase of the odontoid-basion distance in the X-ray, edema in the ligamentous structures in MRI and the increase in the McRae line and odontoid gap cause diagnosis. The first treatment choices in these patients are rigid orthosis such as Halo or Minerva to ensure immobilization. As surgical treatment, occiput-C1-2 instrumentation and fusion can be applied [28,29].

Atlas fractures

Fractures (Jefferson fracture) occurred in the anterior or posterior arcuses of the atlas are rather rare in childhood. Because the ossification of the atlas is not complete, structure of the cartilage ensures that it has a more elastic structure compared to adults [30]. If the total of distances between the exterior surface of both CI lateral masses in the AP plane and C2 lateral surfaces is equal to 7 mm or higher, it creates treatment indication [31]. Jefferson fractures can be treated with rigid orthosis in pediatric cases [1,28].

Atlantoaxial rotatuar subluxation

Rotational movement of the atlas on axis is between the 23-25° range. If this range of movement exceeds 58° or the difference between the sides is over 8°, this causes hyper mobility [32]. Torticollis lasting longer than 2-3 months in children is among the most frequent reasons. It can develop related to congenital defects such as trauma, infection, Klippel-feil syndrome, Marfan syndrome, and Down syndrome [13].

Atlanto-axial rotator subluxations were classified in four classes by Fielding and Hawkins according to the state of the atlanto-axial ligament (Figure 1) [32]. Type I is the most common and benign form and has unilateral facet subluxation. Transvers ligament is strong and not displaced with atlas anterior. In Type II, atlas is displaced 3-5 mm with unilateral facet dislocation. In Type III, there is bilateral facet dislocation, atlas is more displaced in 5 mm. There is transvers ligament and seconder ligament injury. In this form since all ligaments are ruptured, it is the most serious form. In Type IV, atlas posterior is displaced.

If early diagnosis is made, these cases with typical Cock-robins posture can be treated with conservative approaches. In the subacute cases, after closed reduction is ensured, there is a chance of treatment with orthosis such as halo or minerva. Surgical treatment is a method to be applied in chronic cases that do not respond to conservative treatments [33,34].

Odontoid fractures

It is the most frequent pathology within the cervical fractures in childhood [1]. When it is formed most frequently in high-energy traumas connected to motor vehicle accidents in adults, falling is the most frequent reason in children (Figure 2). Because the proportion

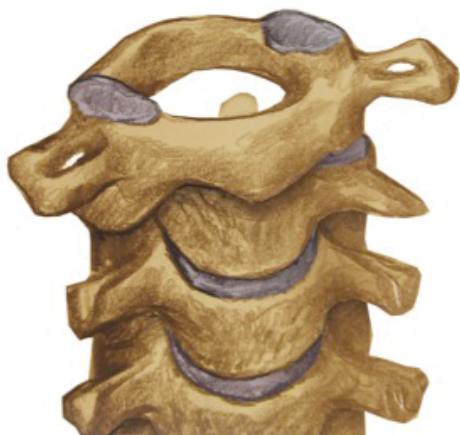

Figure 1: The Atlanto-axial rotatory subluxation.

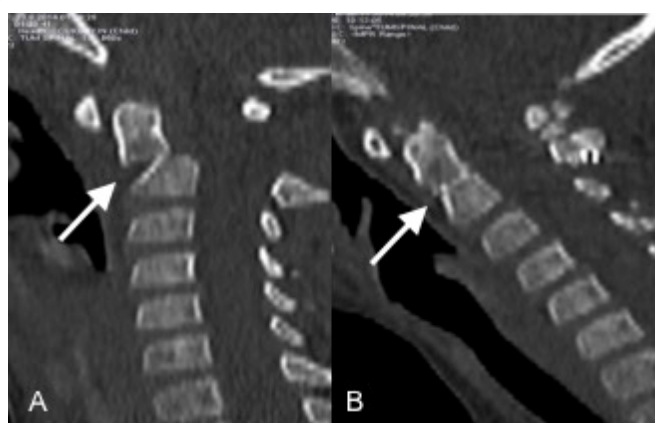


Figure 2: A 6 year-old girl patient with fracture of odontoid after motor vehicle accident (white arrow). (A) Sagittal computerized tomography image, (B) Postoperative sagittal computerized tomography image that posterior approach of the C1-C2 wired.

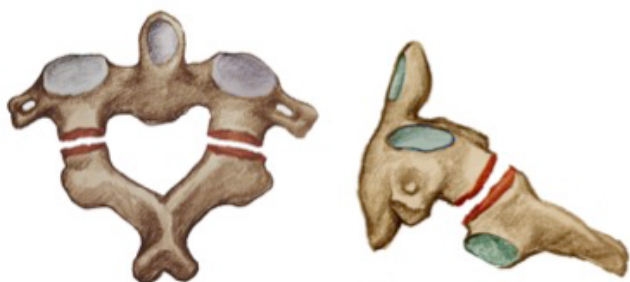

Figure 3: The Hangman's fracture.

of the head weight to the body is high, it is also the most important factor in this case as is in other cervical lesions. Typical fracture area is the non-ossified cartilage line. Different classification systems are used according to the fracture types and localization of the fractured part. When the White and Punjabi classification review by 3 different classifications according to the anterior or posterior dislocation of the fractured part, Anderson and D'Alonzo classification takes the fracture point of the odontoid as the criteria [2,35]. These classification systems help to determine the treatment type.

As in most of the pediatric spinal traumas, conservative methods are also sufficient for odontoid fractures in appropriate patients. Surgical treatment choice can be tried in the cases where reduction and fusion cannot be ensured in spite of external reduction and orthosis. Yet, anterior screws preferred in the adult patients are difficult in pediatric cases because their odontoid diameter is small. For this reason, in necessary cases C1-C2 posterior wiring ensures more dependable surgical treatment [36,37].

Hangman's fracture

Hangman's fracture or the traumatic spondylolisthesis of C2 are formed by the fracture of bilateral C2 pars inter-articularises (Figure 3). Acceleration movements of the big head in small children especially connected to child abuse and hyperextension traumas can cause Hangman's fracture [38,39]. Hangman's fractures seen quite rarely in PSTs have been seen in the Knox et al 206 pediatric spinal traumas at a low rate like 1.4%. In case no additional pathology is found in these cases, neural deficit is not seen since spinal canal diameter is not narrowed. These cases can also be treated with cervical collar much the same in adults [39].

Lower cervical spinal traumas

Traumatic C3-C7 lower cervical area traumas are especially seen in the adolescent and advance childhood period. While lower cervical area trauma ratios are 20-30% in children under nine years of age, it rises up to 70-75 percent in the adolescent and advance childhood period. In the study of McGrory et al. [40] that includes 143 cervical trauma cases, 67 (46.8%) the 11-14 age group forms lower cervical area traumas. After early childhood, the spine bone structure and ligamentous structures considerably resemble the adult spine and transform into a more rigid bone and ligament structure.

Compression or burst fractures connected to the pediatric cervical area traumas, facet fracture or dislocations can develop (Figure 4). Compression fractures are the most frequently developing pathology connected to flexion or axial loading. Compression fractures are generally stable fractures and they don't require surgical treatment.

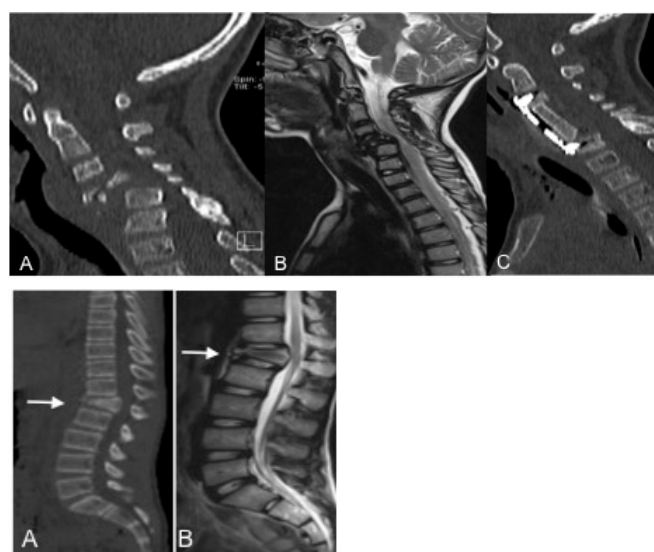


Figure 4: A 5 year-old boy patient with fracture of C4 and C5 after motor vehicle accident. (A) Sagittal computerized tomography image, (B) Sagittal T2 weight magnetic resonance image, (C) Postoperative sagittal computerized tomography who anterior approach of the C4 and C5 corpectomy with plate and screw.

Yet, burst fractures, in comparison with compression fractures, are more instable and are serious pathologies which neurologic problems accompany. Clinical table is formed according to the severity of the trauma and to the level of the spinal cord injury. Bone pathology can be understood in detail with CT. But MRI gives important information in treatment planning. Since MRI shows in detail the ligamentous injury and disk pathologies along with understanding the spinal cord injury, it guides surgical planning. In some cases that have no neurological deficit and are treated by orthosis, and where MR imaging is not performed, kyphotic deformities have developed. In this type of cases, it is considered that a ligamentous injury, which can be determined by MRI but cannot be seen in CT and x-ray, causes kyphosis [41].

Facet dislocations can be unilateral or bilateral. They generally develop connected to the hyper flexion traumas accompanied by rotation. Patients show symptoms with reticular symptoms and/or spinal cord base findings. Compared with the unilateral, bilateral facet dislocations are more instable pathologies [28]. Even though diagnosis can be made by lateral radiography, CT and MRI are necessary to finalize the diagnosis. In early diagnosis cases, reduction can be ensured by traction. In cases in which reduction is ensured, 2-4 month immobilization must be provided by halo or minerva orthosis. In cases where reduction cannot be ensured, reduction and fusion indication appears with anterior or posterior surgeries [1,28].

Thoracic Spinal Traumas

Thoracic fractures are the pathologies that are not widely seen in childhood. Denis and TLICS classifications used in adults can also be used in thoracic and lumbar traumas. TLICS classification helps with the preference between conservative or surgical approach by assessing the morphology of the trauma, integrity of posterior ligament according to clinical examination findings and CT and MR imaging.

In the pediatric thoracic spinal traumas it appears most frequently as a single level compression fracture (Figure 5). In the children who take osteogenesis imperfecta or chemotherapy, multiple thoracic or lumbar fractures may be seen. These fractures are generally stable. Without needing surgical treatment, they can be treated with orthosis [42].

Even though burst fractures are frequently seen pathologies in thoracic and lumbar fractures during adulthood, they are very rare in early childhood. Because the disk distance is high, vertebra ossification is not completed, and endplate cartilage line is distinct, they render burst fractures formation difficult. Nevertheless, after 8-9 years of age, vertebra structure's approximation to the adult vertebra, and its completion of the maturation on a wide extent, increase the risk of the burst fracture [42].

Flexion-dislocation and fracture-dislocation traumas are high-energy traumas. These traumas cause serious spinal cord traumas accompanied by thoracic and abdomen injuries [43,44]. Because of three column injuries in these fractures that are instable, stabilization and fusion surgery treatment are applied by wiring, laminar hook or pedicle instruments. In the spinal traumas below 5-6 years of age, wiring and laminar hook systems can be used in cases where pedicle screw systems cannot be applied.

Lumbar Fractures

Spinal column traumas reaching from the lower thoracic area to the sacrum are rarely seen under 8 years of age pediatric cases. It can develop connected to high-energy traumas such as inside vehicle accidents especially over 10 years of age. Generally abdominal area or

retroperitoneal area injuries accompany these traumas. T12-L2 area fractures are seen classically in safety belt flexion distraction traumas (Figure 6). L3-L5 area fractures are seen more frequently in the later adult period. In these traumas burst or compression fractures and lumbar epiphyseal traumas can be seen. Compression fractures are generally pathologies that recover without applying surgical treatment. In the cases not treated in burst fractures, mainly kyphosis, and mechanical and neurological complications might develop. Lumbar apophyseal injury typically develops in L4 and L5 inferior endplates in males. In case fragment narrows the spinal canal and causes neurologic injury and pain, compressive surgery is required. (44)

Surgical Treatment in Pediatric Spinal Traumas

Pediatric spine structure is not the miniature of adult spine. Along with it is small size, its pedicle structures, pedicle orientations and the differences in the facet joint, make both their anatomic and physical behaviors different.

In thoracic and lumbosacral traumas, current types of treatment in adult patients requiring instrumentation are pedicle screws and fusion. Compared to adults, fusion in pediatric cases happens faster. Since many factors that create comorbidity such as diabetic, smoking, intravenous drug addiction, steroid usage, osteoporosis do not exist in children that enables the fusion to be realized more quickly. As is the case with adults, the best fusion in children is also ensured by autogenous grafts [45,46].

Pedicle screws are the most effective method in ensuring stabilization. Supporting three columns together, allowing rotation, distraction and compression maneuvers, are great advantages of screws.

In pediatric findings, pedicle diameters have been defined in many studies [47,48]. When L5 pedicle diameter is 8 mm in 3-5 years of age, it rises to 14 mm in 10-12 years of age. On T4 and T5 levels, pedicle diameters decrease up to 3-4 mm in the 3-5 years of age group. In the cases where the pedicle diameters are very small, surgical planning must be made by considering the alternatives such as laminar hook systems or wiring. In addition, to increase biomechanical endurance, as in adults, stabilizing with long segments in the pediatric cases is mostly unnecessary. Fast realization of fusion, having lesser load on the screws, and keeping the patient immobile more easily with postoperative orthosis, give the chance of applying instrumentation in

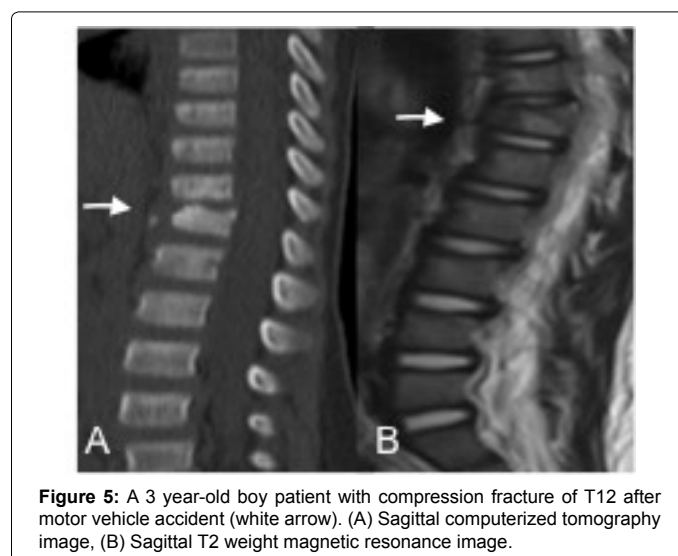


Figure 5: A 3 year-old boy patient with compression fracture of T12 after motor vehicle accident (white arrow). (A) Sagittal computerized tomography image, (B) Sagittal T2 weight magnetic resonance image.

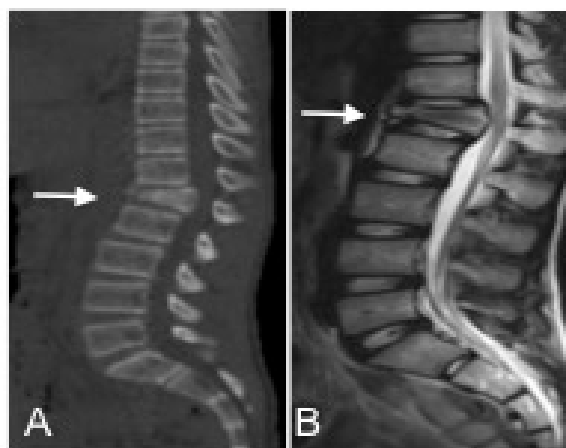


Figure 6: A 4 year-old boy patient with fracture of L1 after motor vehicle accident (white arrow). (A) Sagittal computerized tomography image, (B) Sagittal T2 weight magnetic resonance image.

shorter segments. It should not be forgotten that implants used in pediatric cases may need to be removed in order to prevent deformation when older.

Conclusion

Pediatric spinal traumas distribute rather differently because of the different anatomy and etiopathogenesis from birth to the end of the adolescent period. Pediatric anatomy has advantages and disadvantages against trauma compared to adults. Because of the differences in radiological findings, it should not be forgotten that some findings that may be perceived as pathologic are in fact physiologic. Success with conservative methods in the treatment is higher than it is with adult cases. For this reason, when making surgical decisions, age dependent factors and developmental changes of the pediatric case must be taken into consideration.

References

- Knox JB, Schneider JE, Cage JM, Wimberly RL, Riccio AI (2014) Spine trauma in very young children: a retrospective study of 206 patients presenting to a level 1 pediatric trauma center. *J Pediatr Orthop* 34: 698-702.
- Anderson RC, Kan P, Vanaman M, Rubsam J, Hansen KW, et al. (2010) Utility of a cervical spine clearance protocol after trauma in children between 0 and 3 years of age. *J Neurosurg Pediatr* 5: 292-296.
- Eleraky MA, Theodore N, Adams M, Rekeate HL, Sonntag VK (2000) Pediatric cervical spine injuries: report of 102 cases and review of the literature. *J Neurosurg* 92: 12-17.
- Jones TM, Anderson PA, Noonan KJ (2011) Pediatric cervical spine trauma. *J Am Acad Orthop Surg* 19: 600-611.
- Keyes D, Compere E (1932) The normal and pathological physiology of the nucleus pulposus of the intervertebral disc. *J Bone Joint Surg Am* 14: 897-938.
- Akbarnia BA (1999) Pediatric spine fractures. *Orthop Clin North Am* 30: 521-536, x.
- Nuckley DJ, Eck MP, Carter JW, Ching RP (2004) Spinal maturation affects vertebral compressive mechanics and vBMD with sex dependence. *Bone* 35: 720-728.
- Nitecki S, Moir CR (1994) Predictive factors of the outcome of traumatic cervical spine fracture in children. *J Pediatr Surg* 29: 1409-1411.
- Anders JF, Adelgais K, Hoyle JD Jr, Olsen C, Jaffe DM, et al. (2014) Comparison of outcomes for children with cervical spine injury based on destination hospital from scene of injury. *Acad Emerg Med* 21: 55-64.
- Herzenberg JE, Hensinger RN, Dedrick DK, Phillips WA (1989) Emergency transport and positioning of young children who have an injury of the cervical spine. The standard backboard may be hazardous. *J Bone Joint Surg Am* 71: 15-22.
- Acheson MB, Livingston RR, Richardson ML, Stimac GK (1987) High-resolution CT scanning in the evaluation of cervical spine fractures: comparison with plain film examinations. *AJR Am J Roentgenol* 148: 1179-1185.
- Buhs C, Cullen M, Klein M, Farmer D (2000) The pediatric trauma C-spine: is the 'odontoid' view necessary? *J Pediatr Surg* 35: 994-997.
- Pang D, Li V (2005) Atlantoaxial rotatory fixation: Part 3-A prospective study of the clinical manifestation, diagnosis, management, and outcome of children with atlantoaxial rotatory fixation. *Neurosurgery* 57: 954-972.
- Pang D, Wilberger JE Jr (1982) Spinal cord injury without radiographic abnormalities in children. *J Neurosurg* 57: 114-129.
- Akalan N (2013) Pediatric spinal trauma. *Türk Nöroşirüji Dergisi*. 23: 128-131.
- Swischuk LE (1977) Anterior displacement of C2 in children: physiologic or pathologic. *Radiology* 122: 759-763.
- Chan PN, Antonio GE, Griffith JF, Yu KW, Rainer TH, et al. (2005) Computed tomography for cervical spine trauma. The impact of MDCT on fracture detection and dose deposition. *Emerg Radiol* 11: 286-290.
- Brenner D, Elliston C, Hall E, Berdon W (2001) Estimated risks of radiation-induced fatal cancer from pediatric CT. *AJR Am J Roentgenol* 176: 289-296.
- Gestring ML, Gracias VH, Feliciano MA, Reilly PM, Shapiro MB, et al. (2002) Evaluation of the lower spine after blunt trauma using abdominal computed tomographic scanning supplemented with lateral scanograms. *J Trauma* 53: 9-14.
- Sheridan R, Peralta R, Rhea J (2003) Reformatted visceral protocol helical computed tomographic scanning allows conventional radiographs of the thoracic and lumbar spine to be eliminated in the evaluation of blunt trauma patients. *J Trauma* 55: 665-669.
- Hauser CJ, Visvikis G, Hinrichs C, Eber CD, Cho K, et al. (2003) Prospective validation of computed tomographic screening of the thoracolumbar spine in trauma. *J Trauma* 55: 228-234.
- Viccellio P, Simon H, Pressman BD, Shah MN, Mower WR, et al. (2001) A prospective multicenter study of cervical spine injury in children. *Pediatrics* 108: E20.
- Frank JB, Lim CK, Flynn JM, Dormans JP (2002) The efficacy of magnetic resonance imaging in pediatric cervical spine clearance. *Spine (Phila Pa 1976)* 27: 1176-1179.
- Flynn JM, Closkey RF, Mahboubi S, Dormans JP (2002) Role of magnetic resonance imaging in the assessment of pediatric cervical spine injuries. *J Pediatr Orthop* 22: 573-577.
- Bosch PP, Vogt MT, Ward WT (2002) Pediatric spinal cord injury without radiographic abnormality (SCIWORA): the absence of occult instability and lack of indication for bracing. *Spine (Phila Pa 1976)* 27: 2788-2800.
- Grabb PA, Pang D (1994) Magnetic resonance imaging in the evaluation of spinal cord injury without radiographic abnormality in children. *Neurosurgery* 35: 406-414.
- Mahajan P, Jaffe DM, Olsen CS, Leonard JR, Nigrovic LE, et al. (2013) Spinal cord injury without radiologic abnormality in children imaged with magnetic resonance imaging. *J Trauma Acute Care Surg* 75: 843-847.
- Sellin JN, Shaikh K, Ryan SL, Brayton A, Fulkerson DH, Jea A, et al. (2014) Clinical outcomes of the surgical treatment of isolated unilateral facet fractures, subluxations, and dislocations in the pediatric cervical spine: report of eight cases and review of the literature. *Child's Nervous System*, 1-10.
- Dvorak MF, Fisher CG, Aarabi B, Harris MB, Hurlbert RJ, Rampersaud YR, et al. (2007) Clinical outcomes of 90 isolated unilateral facet fractures, subluxations, and dislocations treated surgically and nonoperatively. *Spine (Phila Pa 1976)* 32: 3007-3013.
- Lustrin ES, Karakas SP, Ortiz AO, Cinnamon J, Castillo M, et al. (2003) Pediatric cervical spine: normal anatomy, variants, and trauma. *Radiographics* 23: 539-560.
- Nigrovic LE, Rogers AJ, Adelgais KM, Olsen CS, Leonard JR, et al. (2012) Utility of plain radiographs in detecting traumatic injuries of the cervical spine in children. *Pediatr Emerg Care* 28: 426-432.
- Phillips WA, Hensinger RN (1989) The management of rotatory atlanto-axial subluxation in children. *J Bone Joint Surg Am* 71: 664-668.
- Crockard HA, Rogers MA (1996) Open reduction of traumatic atlanto-axial rotatory dislocation with use of the extreme lateral approach. A report of two cases. *J Bone Joint Surg Am* 78: 431-436.

34. Fusco MR, Hankinson TC, Rozzelle CJ (2011) Combined occipitoatlantoaxial rotatory fixation. *J Neurosurg Pediatr* 8: 198-204.
35. White AA III, Panjabi MM (1990) The problem of clinical instability in the human spine: a systematic approach, in *Clinical Biomechanics of the Spine*, ed 2. Philadelphia: JB Lippincott, 278-378.
36. Clark CR, White AA (1985) Fractures of the dens. A multicenter study. *J Bone Joint Surg Am* 67: 1340-1348.
37. Maak TG, Grauer JN (2006) The contemporary treatment of odontoid injuries. *Spine (Phila Pa 1976)* 31: S53-60.
38. SULLIVAN CR, BRUWER AJ, HARRIS LE (1958) Hypermobility of the cervical spine in children; a pitfall in the diagnosis of cervical dislocation. *Am J Surg* 95: 636-640.
39. Weiss MH, Kaufman B (1973) Hangman's fracture in an infant. *Am J Dis Child* 126: 268-269.
40. McGrory BJ, Klassen RA, Chao EY, Staeheli JW, Weaver AL (1993) Acute fractures and dislocations of the cervical spine in children and adolescents. *J Bone Joint Surg Am* 75: 988-995.
41. Henry M, Riesenburger RI, Kryzanski J, Jea A, Hwang SW (2013) A retrospective comparison of CT and MRI in detecting pediatric cervical spine injury. *Childs Nerv Syst* 29: 1333-1338.
42. Junewick JJ, Borders HL, Davis AT (2014) Pediatric thoracic spine injuries: a single-institution experience. *AJR Am J Roentgenol* 203: 649-655.
43. Denis F (1983) The three column spine and its significance in the classification of acute thoracolumbar spinal injuries. *Spine (Phila Pa 1976)* 8: 817-831.
44. Chang CH, Lee ZL, Chen WJ, Tan CF, Chen LH (2008) Clinical significance of ring apophysis fracture in adolescent lumbar disc herniation. *Spine (Phila Pa 1976)* 33: 1750-1754.
45. Blanco JS, Sears CJ (1997) Allograft bone use during instrumentation and fusion in the treatment of adolescent idiopathic scoliosis. *Spine (Phila Pa 1976)* 22: 1338-1342.
46. Dodd CA, Fergusson CM, Freedman L, Houghton GR, Thomas D (1988) Allograft versus autograft bone in scoliosis surgery. *J Bone Joint Surg Br* 70: 431-434.
47. Saillant G (1976) [Anatomical study of the vertebral pedicles. Surgical application]. *Rev Chir Orthop Reparatrice Appar Mot* 62: 151-160.
48. Zindrick MR, Wiltse LL, Doornik A, Widell EH, Knight GW, et al. (1987) Analysis of the morphometric characteristics of the thoracic and lumbar pedicles. *Spine (Phila Pa 1976)* 12: 160-166.