

# Parotidectomy in a 54 Years Old Patient: Case Report

Mohamed El Hussein and Abbas El Hussein\*

Dar Al Amal Hospital, Baalbeck, Beirut, Lebanon

## Abstract

Parotid gland tumors account for 80% of all salivary gland neoplasms, 20% of these are malignant, but in daily clinical practice most parotid masses are operated on before obtaining the final histological diagnosis. This clinical setting further complicates the critical point of parotid surgery, which is the management of the facial nerve. We present the case of 54 years old male patient diagnosed with parotid tumor. He underwent a parotidectomy and the postoperative course was uneventful. Different key points of management and of the surgical procedure are highlighted and discussed.

**Keywords:** Parotid tumors; Parotid surgery; Facial nerve

## Introduction

Parotid gland tumors account for 80% of all salivary gland neoplasms, 20% of these are malignant, but in daily clinical practice most parotid masses are operated on before obtaining the final histological diagnosis [1]. This clinical setting further complicates the critical point of parotid surgery, which is the management of the facial nerve [2]. We present herein a case of parotid tumor treated by parotidectomy.

## Case Presentation

The patient, 54 years old male presented with the following signs and symptoms: left tumoral mass, solid and pain and discomfort, despite he had underwent parotidectomy 1 year ago. The tumor was located in front part of the left ear and had 3.5 cm. MRI and CT scan confirmed recurrence of the tumor.

The patient's head was turned away from the side of the tumor and the neck extended (arched back). The incision started in front of the left ear, curved around the bottom of the ear and then down the posterior aspect of the jawbone (Figure 1). An anterior subplatysmal/subsuperficial musculoaponeurotic system (SMAS) flap is made by using the natural plane on the surface of the parotid gland. The ear lobe was lifted-up and backward and the posterior border of the parotid gland was exposed first (Figure 1).

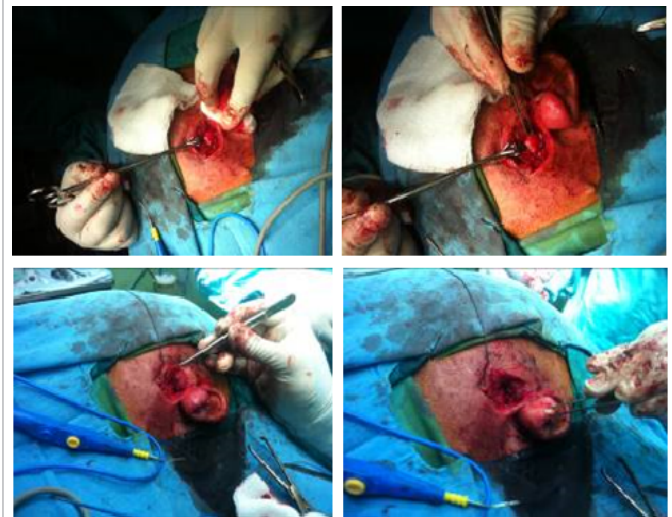The case was difficult and required attention, because the trajectory of the facial nerve was through the left parotid gland. This could explain the recurrence of tumor due to surrounding tissues with the tumor. Finally, we identified the facial nerve trunk and its branches. We removed the superficial lobe first, and then dissected out of the deep lobe between the branches of the facial nerve. We paid attention not to injure the facial nerve branches. As we can see in Figure 2, the facial nerve is white and looks like a plant root. We removed carefully the tumor, process that took us 2 hours (Figures 2 and 3). After that, the drainage tube was placed to prevent hematoma. The patient was discharged the third day with no fistula or any other complication (Figure 4).

## Discussion

Salivary cancers account for approximately 3% of all head and neck malignancies diagnosed in the United States each year; most of these (80%) are located in the parotid glands. Most benign tumors of the parotid gland are epithelial tumors. Pleomorphic adenoma is the most common tumor of the parotid gland (60 to 70% of all tumors) [1,2]. The pleomorphic adenoma is a benign tumor with a potential for local recurrence [2-4] and an extremely low rate of malignant transformation (1-2% of primary parotid gland malignancy) [5,6].

Surgery is the main treatment of pleomorphic adenoma. Enucleation is no longer recommended [1,4-6]. In patients with pleomorphic adenoma of the superficial lobe, either superficial or total parotidectomy can be used. Superficial parotidectomy may be associated with a higher recurrence rate and total parotidectomy with a higher risk of facial nerve dysfunction [7,8].

The parotid gland is shaped like an upside-down triangle and lies in front and below the opening to the ear canal [9]. Anterior is the posterior surface of the jawbone and the masseter muscle. The deep surface of the gland lies alongside the back of the throat, near the tonsils. The gland is divided by the facial nerve into a superficial and deep lobe. The facial nerve arises in the skull, emerges at the stylomastoid foramen, enters the gland and branches out inside the parotid, defining the superficial



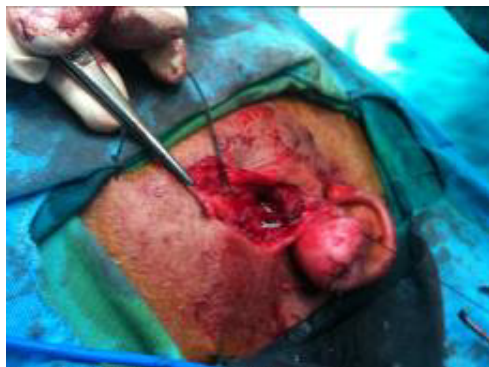**Figure 1:** Parotidectomy: dissecting the skin and underlying layers.

\*Corresponding author: Abbas El Hussein, Dar Al Amal Hospital, Baalbeck, Beirut, Douris (Baalbeck), Lebanon, Tel: +961 8 371 901; E-mail: [drhusseiny@yahoo.com](mailto:drhusseiny@yahoo.com)

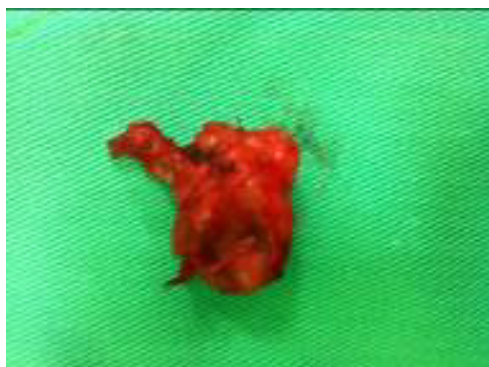
Received July 04, 2017; Accepted July 25, 2017; Published August 01, 2017

**Citation:** El Hussein M, El Hussein A. Parotidectomy in a 54 Years Old Patient: Case Report. Journal of Surgery [Jurnalul de chirurgie]. 2017; 13(3): 105-107 DOI: [10.7438/1584-9341-13-3-6](https://doi.org/10.7438/1584-9341-13-3-6)

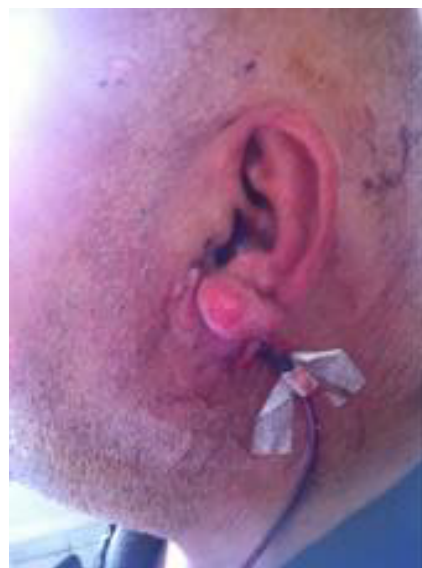**Copyright:** © 2017 El Hussein M, et al. This is an open-access article distributed under the terms of the Creative Commons Attribution License, which permits unrestricted use, distribution, and reproduction in any medium, provided the original author and source are credited.



**Figure 2:** Exposure of the facial nerve.



**Figure 3:** The resected specimen.



**Figure 4:** Final aspect; to note the vacuum drain to avoid hematoma.

and the deep lobe, and must always be identified and dissected when performing parotidectomy. It supplies the muscles of the face. Surgical landmarks to the facial nerve include the tympanomastoid suture line, the tragal pointer, and the posterior belly of the digastric muscle. The tympanomastoid suture line lies between the mastoid and tympanic segments of the temporal bone and is approximately 6-8 mm lateral to the stylomastoid foramen. The main trunk of the nerve can also be found midway between (10 mm posteroinferior to) the cartilaginous tragal pointer of the external auditory canal and the posterior belly of the digastric muscle.

Pathology of parotid glands includes inflammation and infection conditions (stones, abscess) and tumors of the parotid. 70-80% of parotid tumors are benign, the most common being the pleomorphic adenoma and Warthin's tumor. Cancer of the parotid gland occurs in about 20-25% of parotid tumors.

The physical examination is the first diagnostic tool. Most benign parotid tumors present as slow growing, painless masses often in the tail of the parotid gland. Ultrasonography has a high sensitivity in detecting masses in the superficial lobe of the parotid gland. Computerized tomography and/or magnetic resonance imaging reveal the deeper parotid lobe. Fine-needle aspiration biopsy (FNAB) is also indicated by some authors [10-12]. Open biopsy of a parotid mass is not recommended due to the risk of seeding in the case of solid malignancy. Therefore, what usually occurs in clinical practice is that most parotid masses are operated upon in order to obtain the final histological diagnosis.

Surgery of the parotid gland is challenging because the VII cranial nerve. Dissection of the branches of the facial nerve requires patience and special attention both to detail and to landmarks [13]. When the course of a nerve is distorted and attenuated by a tumor, preservation of facial nerve fibers can be very difficult. Experience shows that most of the primary salivary tumors of the parotid are found directly adjacent to at least one branch of the facial nerve.

So, in our opinion, the most conservative operation should be superficial parotidectomy, also in the case of a clearly benign mass. Furthermore, in the event of recurrence, the risk to the facial nerve increases exponentially, particularly in the relatively frequent event of a multi-nodular relapse of a pleomorphic adenoma [14].

Enucleation should be done only in Warthin tumors especially when presenting posterior to the facial nerve [15].

Potential complications of parotidectomy include facial nerve injury, Frey syndrome (the patient may experience sweating or flushing of the skin over the parotid gland every time he eats), salivary leakage, ear numbness, facial asymmetry, flap necrosis, and tumor recurrence.

There may be some weakness of the facial muscles on the side of the surgery due to swelling of the tissues around the nerve. This usually resolves in a few days. Radiation therapy may sometimes be necessary if the tumor was very large, involved nearby tissues or lymph nodes or in cases of deep lobe tumors; as it is sometimes difficult to assess the full extent of the dissection. The prognosis varies with the pathologic type, the size of the tumor and the spread of tumor to surrounding tissues.

## Conclusion

Preoperative investigation includes a minimum of FNA and MRI (contrast enhanced CT is a reasonable alternative in cases where MRI is contraindicated), which inform patient counseling and discussion of adjuvant radiotherapy. The extent of surgery is dictated by the site and size of the tumor and involves a form of superficial or total conservative parotidectomy with preservation of a functioning facial nerve.

## Conflict of Interest

Authors have no conflict of interest to disclose.

## References

1. Laccourreye H, Laccourreye O, Cauchois R, Jouffre V, Menard M, et al. (1994) Total conservative parotidectomy for primary benign pleomorphic adenoma of the parotid gland: A 25-year experience with 229 patients. *Laryngoscope* 104: 1487-1494.
2. Mc Gurk M, Renehan A, Gleave EN, Hancock BD (1996) Clinical significance of the tumour capsule in the treatment of parotid pleomorphic adenomas. *Br J Surg* 83: 1747-1749.
3. Froehlich P, Fombeur JP, Vuong PN (1991) Treatment of recurrence of pleomorphic adenomas of the parotid gland. *Ann Otolaryngol Chir Cervicofac* 108: 333-337.

4. Laskawi R, Schott T, Schroder M (1998) Recurrent pleomorphic adenomas of the parotid gland: clinical evaluation and long-term follow-up. *Br J Oral Maxillofac Surg* 36: 48-51.
5. Chevalier D, Loche V, Darras JA, Apko-Allavo J, Desaulty A, et al. (1996) Reoperation and recurrence of pleomorphic adenoma of the parotid. A propos of 62 cases. *Ann Otolaryngol Chir Cervicofac* 113: 56-60.
6. Myssiorek D, Ruah CB, Hybels RL (1990) Recurrent pleomorphic adenomas of the parotid gland. *Head Neck* 12: 332-336.
7. Becelli R, Perugini M, Mastellone P, Frati R (2001) Surgical treatment of recurrences of pleomorphic adenoma of the parotid gland. *J Exp Clin Cancer Res* 20: 487-489.
8. Carew JF, Spiro RH, Singh B, Shah JP (1999) Treatment of recurrent pleomorphic adenomas of the parotid gland. *Otolaryngol Head Neck Surg* 121: 539-542.
9. <http://www.yoursurgery.com/ProcedureDetails.cfm?BR=4&Proc=40>
10. Zbaren P, Schar C, Hotz MA, Loosli H (2001) Value of fine-needle aspiration cytology of parotid gland masses. *Laryngoscope* 111: 1989-1992.
11. Sergi B, Contucci AM, Corina L, Paludetti G (2004) Value of fine-needle aspiration cytology of parotid gland masses. *Laryngoscope* 114: 789-789.
12. Contucci AM, Corina L, Sergi B, Fadda G, Paludetti G (2003) Correlation between fine needle aspiration biopsy and histologic findings in parotid masses. Personal experience. *Acta Otorhinolaryngol Ital* 23: 314-318.
13. Rea PM, McGarry G, Shaw-Dunn J (2010) The precision of four commonly used surgical landmarks for locating the facial nerve in anterograde parotidectomy in humans. *Ann Anat* 192: 27-32.
14. Redaelli de Zinis LO, Piccioni M, Antonelli AR, Piero N (2008) Management and prognostic factors of recurrent pleomorphic adenoma of the parotid gland: personal experience and review of the literature. *Eur Arch Otorhinolaryngol* 265: 447-452.
15. Heller KS, Attie JN (1988) Treatment of Warthin's tumor by enucleation. *Am J Surg* 156: 294-296.