

Parotid Metastasis of Breast Cancer – A Case Report

Bahaa Razem^{1*} and Faiçal Slimani^{1,2}

¹Department of Stomatology and Maxillofacial Surgery, Hospital August, CHU Ibn Rochd, Casablanca, Morocco

²Faculty of Medicine and Pharmacy, Hassan II University of Casablanca, Casablanca, Morocco

Abstract

Introduction: Parotid metastases of breast cancer are extremely rare. Only 31 cases have been reported between the years of 1982 and 2019.

Case report: We report the case of 41 years-old woman who's parotidian metastasis has been revealed 4 years after the diagnosis of her breast cancer.

Discussion and Conclusion: Any parotid mass occurring in a patient with a history of breast cancer should be considered metastatic until proven otherwise, and a multimodal care should be started as soon as possible.

Keywords: Breast cancer • Parotid gland • Metastasis

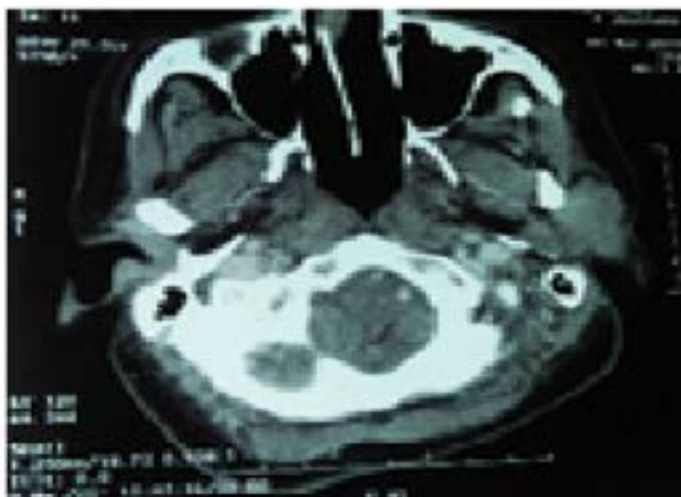
Introduction

Parotid malignant tumors represent 1% to 4% of head and neck cancers, [1] of which only 10.4% to 35.6% are secondary lesions. In a majority of cases, the primary lesion is located in the cervico-facial region [2]. We report a case of parotid metastasis from breast cancer with review of literature.

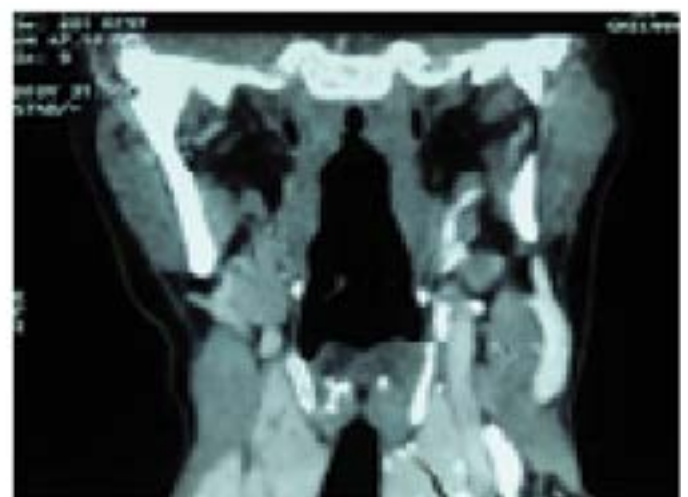Case Report

Ms. L. M., a 41-year-old woman, presented in 2015 and infiltrating ductal carcinoma of the right breast treated by mastectomy, axillary lymph node dissection, adjuvant chemotherapy followed by loco regional radiotherapy. A hormone therapy (Tamoxifen) was prescribed for four years. She presented in January 2019 a painless swelling in the left parotid region. Clinical examination

revealed the presence of a mass in the left parotid region measuring 3 cm/2 cm, firm, painless, mobile, without inflammatory signs and without facial nerve palsy or a limitation of mouth opening and a normal Stenon orifice. Head and neck CT showed an enlarged left parotid, located in its superficial lobe with an oval formation 27 mm long in the long axis, with bilateral cervical lymph nodes below centimeters (Figure 1). The patient underwent a left superficial parotidectomy with the performance of an extemporaneous pathological examination, which revealed the presence of a malignant proliferation, following which a totalization was performed with conservation of the facial nerve. The complement of the anatomopathological and immunohistochemical study was in favor of a secondary localization of the breast carcinoma. The patient subsequently received five additional cycles of adjuvant chemotherapy, radiotherapy then followed by a hormone therapy. One year after the initial diagnosis, the patient was alive with no signs of local or regional recidivism and no facial nerve palsy.



1A



1B

Figure 1. (A and B): Computed tomography scan image of the parotid mass.

*Address for Correspondence: Razem B, Department of Stomatology and Maxillofacial Surgery, Hospital August, CHU Ibn Rochd, Casablanca, Morocco, E-mail: r.bahaa@hotmail.fr

Copyright: © 2020 Razem B, et al. This is an open-access article distributed under the terms of the Creative Commons Attribution License, which permits unrestricted use, distribution, and reproduction in any medium, provided the original author and source are credited.

Received 27 September 2020; Accepted 15 October 2020; Published 22 October 2020

Table 1. Table summarizing the 31 cases in the literature and the patient in this report.

References	Age	Location (breast)	Stage (TNM)	Location (parotide)	Symptoms	Therapy
	62	Left	Stade IV	Left	Mass	RT, HT
Wiesel, et al. [13]	64	Left	T2N0M0	Left	Mass	SP, RT
	74	Left	T2N2M0	Left	Mass+FNP	RT, HT
Bissett, et al. [14]	41	Right	-	Left	Mass+FNP	PT, RT
	65	Right	-	Left	Mass	RT, CT
Calvo, et al. [15]	57	Right	-	Left	Pain	PT
	66	Right	-	Left	Mass	SP, RT, HT
Kollias, et al. [16]	52	Right	-	Right	Mass	SP, RT, HT
	57	Left	-	Left	Mass	SP, RT, HT
Joyce, et al. [17]	71	Right	T2N0M0	Right	Mass+FNP	TP
Szymansky, et al. [18]	66	Right	-	Right	PNF	TP
	58	Right	-	Right	Mass	TP, RT, CT
Zhang, et al. [19]	40	Left	-	Right	Mass	-
Perez, et al.[20]	61	-	-	Left	Mass	TP, RT, CT
Laforga, et al. [21]	52	Left	T1N0M0	Left	Mass	TP, RT, CT
Dangore, et al. [22]	42	Right	T3N0M1	Left	Mass	TP, LND, RT, CT
Ramesh, et al. [23]	63	Right	M1	Right	Mass	HT
Ando, et al. [8]	65	Left	T1N3M1	Left	Mass	TP, CT
Cihan, et al. [24]	70	Left	T2N3M0	Left	Mass	SP, RT, CT
Sellinger, et al. [25]	74	Left	T2N1M0	Right		TP
Alath, et al. [26]	43	Right	T2N2M1	Left	Mass	TP
Duncan, et al. [27]	76	Right	-	Right	Mass	HT
Akcan, et al. [28]	61	Right	-	Right	Mass	TP
Kmeid, et al. [29]	65	Right	-	Right	Mass	TP
El Mrabet, et al. [9]	43	Right	T4d N1M0	Left	Mass	CT
Rawet, et al. [10]	71	Left	-	Left	Mass	HT
Bohli, et al. [7]	48	Right	T2N0M0	Right	Mass	RT, CT
Assarian, et al. [3]	54	Right	IIIA	Right	Mass+FNP	RT, CT
Cao, et al. [11]	36	Left	-	Left	Mass+FNP	CT, HT
Agrawal, et al. [12]	60	Right	T2N0M0	Right	Mass	SP, HT
	37	Right	-	Right	Mass	RT, CH
Our case	43	Right		Left	Mass	TP, RT, CT

PNF: Facial Nerve Palsy; RT: Radiotherapy; CT: Chemotherapy; HT: Hormone Therapy; SP: Superficial Parotidectomy; TP: Total Parotidectomy; LND: Lymph Node Dissection

Discussion

Malignant tumors represent 9% to 14% of parotid tumors [3]. Two thirds of parotid metastases originate from tumors of the head and neck [4], and only 0.16% to 0.4% originate from primary subclavicular sites. These metastases could be explained by lymphatic dissemination via the thoracic duct or hematogenous via the venous connections that exist between the face and the para-vertebral venous plexus of Batson [3,5]. The first case of parotid metastasis from breast cancer was reported by Abrahams et al., in 1950 in a series of 167 autopsies of patients with breast cancer where only one case of parotid metastasis was detected [6]. From 1982 to 2019 31 cases of breast cancer metastatic to the parotid gland were reported worldwide (Table 1) [3-30]. The management of parotid metastases is controversial. According to the majority of authors, total or superficial parotidectomy with preservation of the facial nerve followed by postoperative radiotherapy of the parotid and neck would be the protocol for most tumors restricted to the parotid, without clinical involvement of the cervical lymph nodes. However, in the case of large parotid tumors, the facial nerve may have to be sacrificed because its preservation can compromise the surgical margins. However, others have concluded that radical parotid surgery does not improve life expectancy [13]. Some authors propose parotidectomy followed by adjuvant chemotherapy and explain this by the possible coexistence of occult and microscopic metastases. An ipsilateral cervical lymph node dissection has been proposed by some authors but few references exist to study its benefits [3-14]. Almost all current treatment procedures for metastatic parotid disease are palliative, as the prognosis of patients with parotid metastases remains bleak, with only 5-10% as a survival rate [11].

Conclusion

Parotid gland metastases from breast origin are extremely rare. Any parotid mass occurring in a patient with a history of breast cancer should be considered metastatic until proven otherwise. Multimodal treatment combining surgery, radiotherapy and chemotherapy should be started as soon as possible in order to obtain better local control and a quality of life.

References

1. Amana Bathokedeou, Essobozou Pegbessou, Essohanam Boko and Pegbessou Agoda, et al. "Malignant Tumors of the Parotid Gland: Epidemiology in Togo". *J Stomatol Maxillofacial Surg Oral Surg* 115 (2014): 15-16.
2. Dequanter, Dot. "Secondary Malignant Tumors of the Parotid Gland." *Ann Otolaryngol Cervicofac Surg* 122 (2005): 18-20.
3. Assarian Abdolali, Negar Mashoori and Vahid Soleimani. "Parotid Gland: An Unusual Site for Breast Cancer Metastasis: A Case Report and Review of Literature." *Arch Breast Cancer* 2 (2019): 01.
4. Agarwal Radhika, Deepika Rana, Latika Gupta and Meeta Singh, et al. "Mucinous Breast Carcinoma Metastatic to Parotid Gland: Report of a Case Diagnosed by Fine Needle Aspiration." *Cytopathol* 30 (2019): 128-130.
5. Pearce, James. "The Craniospinal Venous System." *Euro Neurol* 56 (2006): 136-38.
6. Herbert L. Abrams, Robert Spiro and Norman Goldstein. "Metastases in Carcinoma: Analysis of 1000 Autopsied Cases." *Cancer* 3 (1950): 74-85.

7. Bohli, Maha, "Parotid Gland Metastasis from Breast Origin." *J Clin Case Rep* 8 (2018): 2.
8. Ando Katsutoshi, Norio Masumoto, Masaaki Sakamoto and Kou Teraoka, et al. "Parotid Gland Metastasis of Breast Cancer: Case Report and Review of the Literature." *Breast Care* 6 (2011): 471-473.
9. El M'rabet Fatimazahra, Rajae Kanab, Taoufiq Ameuraoui and Fatoumata Sidibe, et al. "Métastase Parotidienne Dun Cancer: A Propos Dun Cas Literature." *Pan Afr Med J* 27 (2017): 01.
10. Thomas Rawet, Apurna Jegannathen and Soni Soumian. "Parotid Gland: An Unusual Site of Breast Cancer Metastasis." *Case Rep* 2017 (2017): 2017-2218.
11. Cao Xiao-Shan, Bin-Bin Cong and Zhi-Yong Yu. "Parotid Gland Metastasis from Carcinoma of the Breast Detected by PET/CT: Case Report and Review." *Med* 97 (2018): 20.
12. Agrawal Chaturbhuj Ramanand, Kumardeep Dutta, Dinesh Chandra Doval and Sunil Pasricha, et al. "Breast Cancer Recurrence Presenting as Solitary Intraparotid Nodal Metastasis Detected by 18F-Fluorodeoxyglucose Positron Emission Tomography: A Very Unusual Occurrence." *Ind J Nuclear Med* 33 (2018): 233.
13. Jochanan M. Wiesel, Zeev Weshler, Yoav Sherman and Isaac Gay. "Parotid Gland Metastatic Carcinoma of Breast Origin." *J Surg Oncol* 20 (1982): 227-230.
14. Bissett Don and Matew Bessell. "Parotid Metastases from Carcinoma of the Breast." *Clin Radiol* 40 (1989): 309-310.
15. Pablo Santos Gorjón, María Gil Melcón, Ángel M. Muñoz Herrera and Fernando Franco Calvo. "Metastasis of Breast Carcinoma in Parotid: A Case Report and Review of the Literature." *Acta Otorrinol* 46 (1995): 391-393.
16. Kollias, Jones. "Superficial Parotidectomy for Parotid Metastases from Breast Cancer." *Breast* 6 (1997): 108-109.
17. Thomas Rawet, Apurna Jegannathen and Soni Soumian. "The Parotid Gland: An Unusual Site of Metastasis from Carcinoma of Breast." *Irish J Med Sci* 169 (2000): 230-230.
18. Marcin, Szymanski. "Parotid Metastases from Breast Cancer." *Wiadomosci Lekarskie* 55 (2002): 494-497.
19. Zhang Shao-Kai, Rongshou Zheng, Qiong Chen and Siwei Zhang, et al. "Oral Cancer Incidence and Mortality in China, 2011." *Chinese J Cancer Res* 27 (2015): 44-51.
20. Perez Fidalgo, Chirivella J. Laforga, Mano Colio and Blanes R. Baydal, et al. "Parotid Gland Metastasis of a Breast Cancer." *Clin Translat Oncol* 9 (2007): 264-265.
21. Juan B. Laforga and Joan M. Gasent. "Mammary Invasive Duct Carcinoma Metastatic to Parotid Gland: Report of a Case Diagnosed by Fine-Needle Aspiration." *Diagn Cytopathol* 37 (2009): 154-158.
22. Suwarna B. Dangore-Khasbage, Shirish S. Degwekar, Rahul R. Bhowate and Arvind Bhake. "Metastatic Involvement of Parotid from Carcinoma of the Breast: A Case Report." *Oral Maxillofac Surg* 13 (2009): 49-53.
23. Rakesh S. Ramesh, Suraj Manjunath, Tanveer Hussain Ustad and Saira Pais, et al. "Breast Cancer Presenting as Parotid Tumour: First Reported Case in Literature." *Ind J Surg Oncol* 1 (2010): 76-77.
24. Yasemin B. Cihan, Kemal Deniz and Mehmet S. Yilmaz. "Synchronous Parotid and Thyroid Gland Metastases from Breast Cancer." *Breast Care* 2 (2011): 133-135.
25. Sellinger Maïke, Klaus Neubauer, Marina William and Bernhard Hemmerlein, et al. "Contralateral Metastasis of Parotid Gland in Advanced Breast Cancer with Peripheral Facial Paralysis." *Arch Gynecol Obst* 284 (2011): 1557-1560.
26. Alath, Pant. "Parotid Gland Metastasis of Breast Cancer Diagnosed on Fine Needle Aspiration Cytology: Case Report and Review of Literature." *Cytopathol* 25 (2014): 346-348.
27. Duncan, Markitziu. "Bilateral Parotid Gland Metastases from Carcinoma of the Breast that Presented 25 Year after Initial Treatment." *Br J Oral Maxillofac Surg* 53 (2015): 94-96.
28. Akcan Fatih, Emel Çadalli Tatar, Gülezer Saylam and Hakan Korkmaz. "Management of Breast Cancer Metastasis to Parotid Gland." *Cancer* 5 (2015): 100-130.
29. Kmeïd Michel, François G. Kamar, Selim Nasser and Nabil Moukarzel. "Metachronous, Single Metastasis to the Parotid, from Primary Breast Cancer: A Case Report and Review of the Literature." *Case Rep Oncol Med* 2016 (2016): 01.
30. Raut, Venkatraman. "Aggressive Treatment of Metastasis to the Parotid." *Ulster Med J* 73 (2004): 85.

How to cite this article: Bahaa Razem and Faiçal Slimani. "Parotid Metastasis of Breast Cancer – A Case Report." *Clin Case Rep* 10 (2020): 1394. Doi: 10.37421/jccr.2020.10.1394