

Orbital Apex Syndrome in a Patient with Sphenoethmoidal Fungal Rhinosinusitis

Thanikachalam Subramanyan¹, Rakesh Singh², Karunanidhi Manickam¹, Jagadeeswaran Vadivel Udayakumaran¹, Neeta pal^{1*}, Namrata Pal³ and Govind Pal⁴

¹Indira Gandhi Government General Hospital and Postgraduate Institute, Pondicherry, India

²Jawaharlal Institute of Medical Education and Research, Pondicherry, India

³Vivekanand Education Society's Institute of Technology, Mumbai, India

⁴Miraj Medical College, Miraj, India

Abstract

A 65 years old lady with uncontrolled diabetes mellitus came with Right Eye (RE) vision loss after 7 day history of drooping of RE upper lid. RE showed painful ophthalmoplegia and complete ptosis. Otorhinolaryngologica I (E.N.T.) examination detected edematous mucosa and mucopurulent discharge from sphenoethmoidal recess. Computed Tomography (C.T.) scan showed bilateral sphenoid and right ethmoiditis with no intracranial spread. Most of the lesions were located at orbital apex with no bony erosion, as confirmed with Magnetic Resonance Imaging (MRI). Clinically, it was Orbital Apex Syndrome (OAS) due to noninvasive fungal rhinosinusitis. Treatment with antibiotics and antifungals was initiated. Functional Endoscopic Sinus Surgery (FESS) was electively done on 7th hospital day. Fungal masses were removed from sphenoid sinus and sent for histopathological study. Microbiological study showed *Conidiobolus coronatus* as causative agent. *Conidiobolus* rhinosinusitis leading to orbital apex syndrome is very rare. Probably the first reported case in India.

Keywords: Orbital apex syndrome; Diabetes mellitus; Rhinosinusitis; Fungal balls

Case Report

A 65 years old lady presented with right visual loss after 7 day history of complete drooping of Right Eye (RE) upper lid. Her physical examination details: Conscious, cooperative well oriented to time, place and person. Blood pressure was 110/60 mmHg, right arm sitting posture. Pulse was 90 beats per minute, feeble and regular low volume. Body temperature was 37°C. Systemic examination: Cardiovascular system: S1, S2 Heard, No murmurs. Respiratory System: Right side: Basal crepts and Rhonchi present, Left side: Within normal limits. Per / Abdomen: Soft, non-tender, no organomegaly. Central nervous system: conscious, co-operative and well- oriented to time, place and person, Higher functions: Normal, Involuntary movements absent. No gross motor abnormalities were detected. Cranial nerve examination showed multiple nerve palsies which included 2nd, 3rd, 4th, 5th (ophthalmic and maxillary division) and 6th nerve palsies of right eye. Blood tests: Hemoglobin: 11 g/dl, White Blood Cells: 11,000 cells/cu.mm, Differential count: Neutrophils: 74%, Eosinophils: 4%, Lymphocytes: 22%, Blood urea: 30 mg/dl, Serum creatinine: 1.2 mg/dl, Blood sugar: 382 mg/dl, Erythrocyte Sedimentation Rate: 15 mm/hr. Liver Function Tests: Total rotein: 6.9 g/dl, Serum Total bilirubin: 0.6 mg/dl, Serum Direct bilirubin: NIL, Serum albumin: 3.4 g/dl, Serum globulin: 3.5 g/dl, S.G.O.T.: 19 IU/L, S.G.P.T.: 34 IU/L, Alkaline phosphatase: 92 IU/L. ELISA: Negative, HbsAg: Negative

Patient had a 2-yr history of poorly controlled type II diabetes mellitus and 10 yr history of bronchial asthma on irregular treatment for the same. The initial blood sugar measured was 382 mg/dL. Her visual acuity in the RE was PL negative and it was 20/200 in the Left Eye (LE). Her RE examination revealed loss of pupillary light reflex with an afferent defect grade 2, normal anterior chamber, intraocular pressure and fundus. It also showed complete ptosis, mild congestion and total ophthalmoplegia (Figure 1a and 1b). There was no evidence of proptosis. The sensations over forehead, cheek, angle of mouth were absent, RE corneal sensations were absent. E.N.T. examination: Right side: 1st pass: Crusts over middle and superior turbinate, congestion of middle turbinate; 2nd pass: Normal osteomeatal complex; 3rd pass:

mucopurulent discharge from the sphenoethmoidal recess of the right side above and behind eustachian tube orifice. Endoscopic examination detected edematous mucosa and mucopurulent discharge from the sphenoethmoidal recess of the right side. The ophthalmological and nasal examinations of the left side showed no abnormal findings. Hence clinical diagnosis was Orbital Apex Syndrome (OAS). Further radiological investigations were conducted to confirm this diagnosis.

C.T. showed bilateral sphenoid and right ethmoiditis with no orbital invasion (Figure 2a and 2b). Most of the orbital lesions were located at the retrobulbar area and the orbital apex, with surrounding soft tissue thickening. There was no evidence of intracranial extension. Increased signal intensities were noted at the same regions on brain MRI (Figure 2c) with gadolinium enhancement. The initial clinical diagnosis of OAS due to noninvasive fungal sinusitis was confirmed. Initial treatment: The patient was started on intravenous cefoperazone with sulbactam 1 gm b.i.d., Flagyl 500 mg t.i.d., systemic antifungal Tab., Fluconazole 150 mg b.i.d and insulin therapy to control blood sugar. The blood sugar levels were fluctuating throughout the therapy. However, there was no improvement in signs and symptoms after medical management.

Improved treatment: Elective surgery, Functional Endoscopic Sinus Surgery (FESS) was performed under local anesthesia on the 7th hospital day. Thick mucus and yellowish-colored matted fungal balls were found in sphenoid sinus during the surgery. All fungal materials were removed using curettes and sinus irrigation. These were sent to the Department of Pathology and Microbiology for detailed evaluation.

***Corresponding author:** Neeta Pal, Indira Gandhi Government General Hospital and Postgraduate Institute, Pondicherry, E-mail: neeta.pal18@gmail.com

Received July 03, 2015; **Accepted** July 29, 2015; **Published** July 31, 2015

Citation: Subramanyan T, Singh R, Manickam K, Udayakumaran JV, Pal N, et al. (2015) Orbital Apex Syndrome in a Patient with Sphenoethmoidal Fungal Rhinosinusitis. J Clin Case Rep 5: 566. doi:10.4172/2165-7920.1000566

Copyright: © 2015 Subramanyan T, et al. This is an open-access article distributed under the terms of the Creative Commons Attribution License, which permits unrestricted use, distribution, and reproduction in any medium, provided the original author and source are credited.

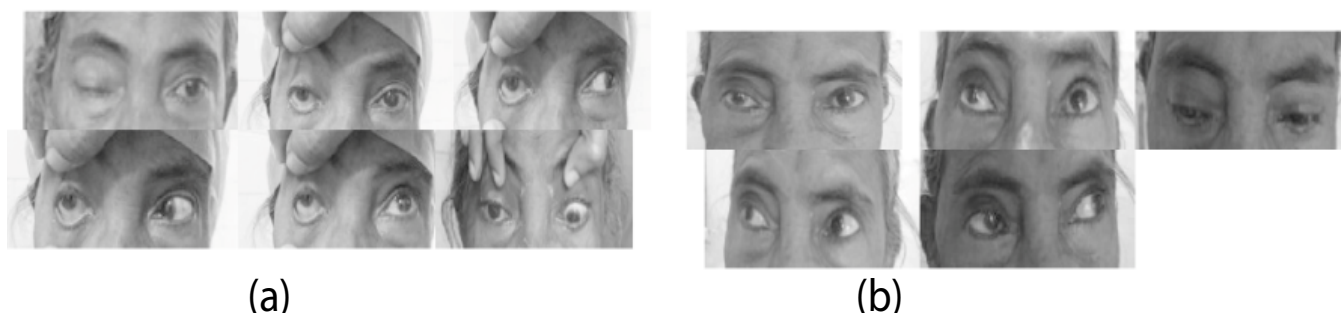


Figure 1: (a) Preoperative ocular movements showing RE total ophthalmoplegia, (b) 4th POD: Extraocular movements full.

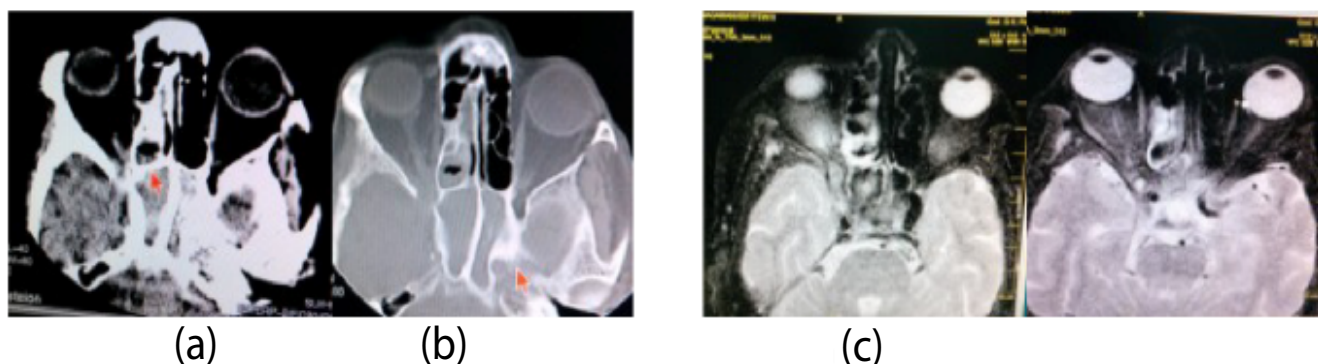


Figure 2: CT pictures: (a) Brain window: Bilateral sphenoid sinuses and right ethmoid show hypodensities 10hu suggestive of fluid probably sinusitis, (b) Bone window: Lateral and medial walls of both orbits are normal, walls of sphenoid and ethmoid sinuses are normal with no evidence of erosion, (c) MRI pictures Axial T2 weighted image of brain at level of orbits show hyperintensities in region of orbital apex, right ethmoid and both sphenoid sinuses, surrounding soft tissue thickening. Both globes appear normal in size, extraocular muscles appear normal. No extension is seen into the cavernous sinus.

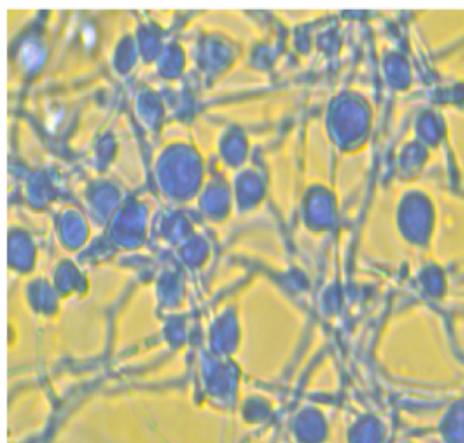


Figure 3: Potato agar culture showed the growth of conidiobolus fungus.

Result of FESS: By the 4th PostOperative Day (POD), there was no improvement in visual acuity but ptosis and extraocular movements resolved completely. The culture of tissue from the sinus biopsy on Sabouraud glucose agar yielded multiple colonies of mold with satellite smaller colonies at periphery. The histopathological report confirmed conidiobolus without evidence of tissue invasion (Figure 3). Therefore, corticosteroid therapy was started with prednisolone (40 mg for first 7

days followed by 20 mg for next 7 days and 10 mg for next 7 days) on 4th POD. With the exception of the visual acuity, the ptotic upper eyelid completely recovered and the extraocular movements improved by the day of discharge (the 30th POD). The patient's blood sugar was not well controlled with fluctuations being noted during the hospitalization. By 2nd month, the right visual acuity was PL negative and the extraocular muscle movement was completely normalized.

Discussion

Most infections with *Conidiobolus* have been described in immunocompetent patients, typically men, working in agriculture or in the forest in subtropical and tropical regions [1,2]. Patients suffer from a local chronic, indolent infection involving facial and subcutaneous tissues as well as the paranasal sinuses, leading to swelling of the infected tissues and chronic sinusitis [2]. *C. coronatus* is the most common species identified. Disseminated infections due to *Conidiobolus* are extremely rare [1-3]. Patients with Diabetes Mellitus (DM) are known to be prone to infection [4]. Orbital apex syndrome is common in poorly controlled diabetics. The most frequent fungal agent that causes rhinosinusitis is *Aspergillus* [5]. Orbital apex syndrome due to mucormycosis [6], aspergillosis [6] have been reported earlier. It is also common in immunocompromised patients. In the immunocompromised patient, there has been an increased incidence of invasive aspergillosis in the last 20 years [7]. Zygomycosis of upper respiratory tract, caused by *Conidiobolus coronatus*, in eight Bengali males and one female is described [8]. But there was no involvement of orbital apex.

Conidiobolus causing orbital apex syndrome is extremely rare. It is known to cause upper respiratory tract infections. But fungal balls were removed from the sphenoid sinus during FESS. A fungal ball is defined as the non-invasive accumulation of dense fungal hyphae in the sinus cavity [9]. Various terms, such as mycetoma, aspergilloma, and chronic noninvasive granuloma have been used interchangeably in the literature to designate sinus fungal ball [9]. Interestingly, the disease has been found more commonly in middle-aged and elderly females, in contrast to all forms of invasive and chronic aspergillosis, which are more common in males [10]. Fungi remain non-invasive in the context of a fungal ball, however, and rarely could become invasive after substantial immunosuppression, such as renal transplantation [11]. In addition, some patients develop allergic mucin surrounding the fungal balls when corticosteroids are tapered [9,12]. Dhong et al. showed that all fungal balls have a characteristic gritty matted gross appearance to the surgeon, whereas the majority, but not all, had C.T. characteristics that included radiographic heterogeneity [13].

The biopsy of specimen obtained from FESS showed spherical conidia with hair-like appendages (villae) and prominent papillae characteristic of *Conidiobolus coronatus* (Figure 3). Although we did not perform orbital apex biopsy, we considered the orbital apex lesion to be non-invasive disease for the following reasons: 1) the lack of response to systemic antibiotics and antifungal agents and 2) the dramatic improvement after surgical drainage and systemic corticosteroid treatment.

The prognosis of OAS secondary to fungal infection is poor, and neurological sequelae and fatal outcomes have been reported in the majority of the cases [9,14,15]. This is probably the first reported case from India. The changing characteristics and clinical behavior of fungal infection should be closely monitored to select the optimal therapeutic modalities. A future study on the proper clinical tools to identify a residual fungal infection after treatment is needed to help save the vision and often the life of patients who suffer with OAS secondary to fungal infection.

References

1. Prabhu RM, Patel R (2004) Mucormycosis and entomophthoromycosis: a review of the clinical manifestations, diagnosis and treatment. Clin Microbiol Infect 10(Suppl. 1): 31-47.
2. Ribes JA, Vanover-Sams CL, Baker DJ (2000) Zygomycetes in human disease. Clin Microbiol Rev 13: 236-301.
3. Fischer N, Ruef C, Ebnöther C, Bächli EB (2008) Rhinofacial *Conidiobolus coronatus* infection presenting with nasal enlargement. Infection 36: 594-596.
4. Zhang Z, Adappa ND, Lautenbach E, Chiu AG, Doghramji L, et al. (2014) The effect of diabetes mellitus on chronic rhinosinusitis and sinus surgery outcome. Int Forum Allergy Rhinol 4: 315-320.
5. Netkovski J, Shirogoka B (2012) Fungal rhinosinusitis Prilozi 33: 187-191.
6. Biswas SS, Al-Amin Z, Razib FA, Mahbub S, Mymensingh (2013) Acute invasive fungal rhinosinusitis: our experience in immunocompromised host. Med J 22: 814-819.
7. Rallis G, Gkinis G, Dais P, Stathopoulos P (2014) Visual loss due to paranasal sinus invasive aspergillosis in a diabetic patient. Ann Maxillofac Surg 4: 247-250.
8. Thammayya A (2000) Zygomycosis due to *Conidiobolus coronatus* in west Bengal. Indian J Chest Dis Allied Sci 42: 305-309.
9. Ferguson BJ (2000) Fungus balls of the paranasal sinuses. Otolaryngol Clin North Am 33: 389-398.
10. Dufour X, Kauffmann-Lacroix C, Ferrie JC, Goujon JM, Rodier MH, et al. (2006) Paranasal sinus fungal ball epidemiology, clinical features and diagnosis. A retrospective analysis of 173 cases from a single center in France, 1989-2002. Med Mycol 44: 61-67.
11. Gungor A, Adusumilli V (1998) Fungal sinusitis: progression of diseases in immunosuppression: A case report. Ear Nose Throat J 77: 207-215.
12. Graham SM, Ballas ZK (1998) Postoperative steroids confuse the diagnosis of allergic fungal sinusitis. J Allergy Clin Immunol 101: 139-140.
13. Dhong HJ, Jung JY, Park JH (2000) Diagnostic accuracy in sinus fungus balls: CT scan and operative findings. Am J Rhinol 14: 227-231.
14. Pieroth L, Winterkorn JM, Schubert H, Millar WS, Kazim M (2004) Concurrent sino-orbital aspergillosis and cerebral nocardiosis. J Neuroophthalmol 24: 135-137.
15. Fernandes YB, Ramina R, Borges G, Queiroz LS, Maldaun MV, et al. (2001) Orbital apex syndrome due to aspergillosis: case report. Arq Neuropsiquiatr 59: 806-808.