

Ocular Metastasis from Breast Cancer: A Case Report and Review of Literatures

Abdelaal E^{1*}, Hacking D¹, Sasiadek W¹, O'Connor M², Owens I³, Murphy K⁴, McGeeney C⁴ and Matthew J⁵

¹Department of Radiation Oncology, UPMC Hilman Cancer Centre, Waterford, Ireland

²Department of Medical Oncology, University Hospital Waterford (UHW), Ireland

³Department of Radiation Physics, UPMC Whitfield Cancer Centre, Ireland

⁴Department of Radiation Therapy, UPMC Whitfield Cancer Centre, Ireland

⁵Department of Nursing Unit, UPMC Whitfield Cancer Centre, Ireland

Abstract

Male breast cancer is relatively uncommon, representing less than 1% of all breast cancer with a peak incidence at 70 years. The principles of management are like that for female patients, including surgery (more mastectomy in men), radiotherapy and systemic treatment. The prognosis is stage dependent and it is generally worse than female breast cancer due to late presentation. The choroid is a relatively common site for metastasis due to rich blood supply and the most common primaries are the breast and the lung. We are presenting a case of a male patient with locally advanced breast cancer, who had mastectomy and radiotherapy in 2015 and who presented three years later with blurred vision in the left eye and was found to have choroidal metastasis. He had urgent palliative radiotherapy to the left eye. Further investigation followed showing widespread metastatic disease and he demised shortly thereafter.

Keywords: Radiotherapy; Cancer; Mastectomy

Introduction

Male breast cancer is relatively rare and accounts for <1% of all male cancer in western countries [1], with an average age at diagnosis of 71 years [2]. There is a significant geographic variation among countries with the highest incidence in Israel and the lowest in Thailand [3].

Common risk factors are like female breast cancer and include genetic, hormonal and environmental factors. Conditions associated with hyperestrogenism like obesity and liver cirrhosis increase the risk [4,5] BRCA2 mutation is a significant risk factor [6,7]. Principles of treatment is like postmenopausal females, except for mastectomy which is common in males [8].

Prognosis is stage dependent, but most male breast cancer patients have worse prognosis due to late presentations, older age and presence of comorbidities [9]. Breast cancer is the most common primary metastasizes to the eye [10] and uveal tract, mainly choroid is the most common metastatic ocular site [11]. Widespread disease to other organs is common before development of ocular metastasis [12,13], however in rare situation ocular metastasis may precede other sites [14].

Case Report

A male patient, aged 68 years, was diagnosed in 2015 with right breast invasive duct cancer, grade 2, Oestrogen receptor and Progesterone receptor positive, and Her-2 receptor positive. He underwent mastectomy and axillary clearance for Stage T4b N1 M0 R0 (5 cm tumour involving epidermis with skin ulceration, 1/21 nodes positive- largest 2 mm), followed by tamoxifen for 5 years, Herceptin for 1 year and radiotherapy to chest wall and nodes.

In February 2018, he presented with blurred vision of the left eye. Ultrasound examination showed avascular, elevated choroidal lesion in the inferior temporal aspect of left globe (Figure 1), measuring 7.5 × 5.6 mm at its base and it was 2.8 mm thick. There was no evidence of retinal detachment and the right eye was normal. Eye Ultrasound showing the choroidal lesion (Figure 2).

Fine needle aspiration cytology from the eye showed metastatic carcinoma. He received radiotherapy to left eye 30 Gy/10 fractions

with improvement of his vision. Further investigations including CT Brain, thorax, abdomen and pelvis and isotope bone scan showed liver, lung and bone metastases with 2 small brain lesions. MRI brain showed extensive brain metastases [15-17]. He was treated with WBRT and was put on Herceptin and Pertuzumab. He died in August 2018.

Details of radiotherapy treatment

A GE CT scanner using a slice thickness of 2.5 mm was used to scan the patient, with the head immobilised in a neutral treatment position

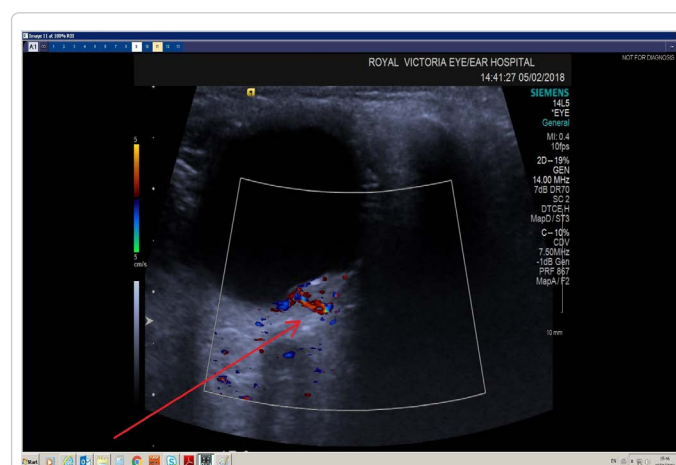


Figure 1: Ultrasound examination showed avascular, elevated choroidal lesion in the inferior temporal aspect of left globe.

***Corresponding author:** Abdelaal E, Department of Radiation Oncology, UPMC Hilman Cancer Centre, Waterford, Ireland, Tel: +1 412-647-2811; E-mail: eshherbieny@yahoo.com

Received March 08, 2019; **Accepted** March 14, 2019; **Published** March 21, 2019

Citation: Abdelaal E, Hacking D, Sasiadek W, O'Connor M, Owens I, et al. (2019) Ocular Metastasis from Breast Cancer: A Case Report and Review of Literatures. J Clin Case Rep 9: 1223. doi: [10.4172/2165-7920.10001223](https://doi.org/10.4172/2165-7920.10001223)

Copyright: © 2019 Abdelaal E, et al. This is an open-access article distributed under the terms of the Creative Commons Attribution License, which permits unrestricted use, distribution, and reproduction in any medium, provided the original author and source are credited.

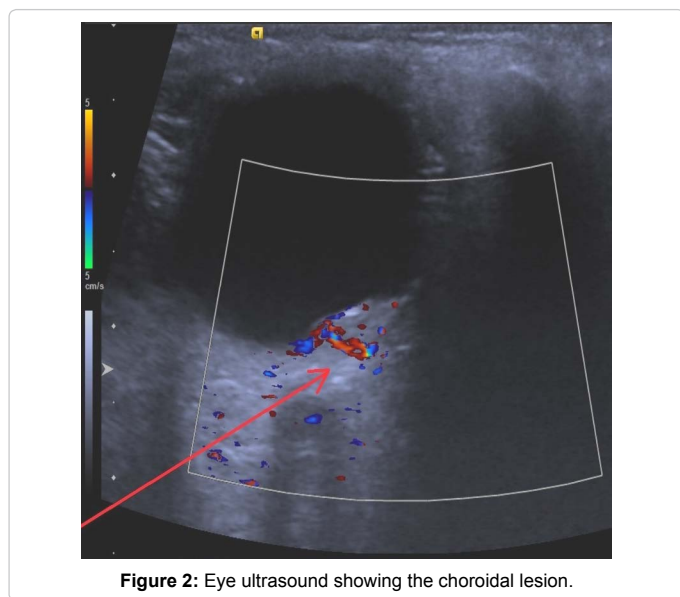


Figure 2: Eye ultrasound showing the choroidal lesion.

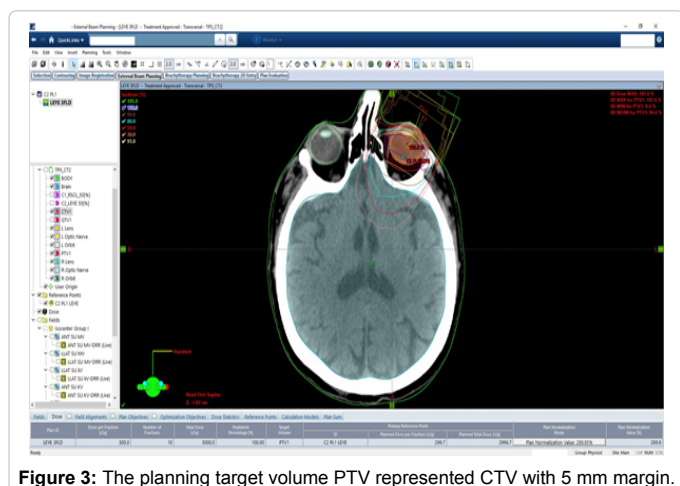


Figure 3: The planning target volume PTV represented CTV with 5 mm margin.

using a thermoplastic mask to maintain a reproducible position throughout the treatment. Treatment plan was performed using the ECLIPSE planning system version 11.0.31 (VARIAN, Palo Alto, CA, USA). The treatment was delivered with a VARIAN CLINAC IX Linear Accelerator. The dose was 30 Gy over 10 fractions using conformational 3D. The clinical target volume CTV was the posterior uvea-choroid of the eye. The planning target volume PTV represented CTV with 5 mm margin (Figure 3).

The plan required three fields with gantry angles of 40, 33 and 55 degrees respectively. Collimator angles of 55, 330 and 310 degrees and couch rotations of 300, 25 and 60 degrees respectively. No wedges or enhanced dynamic wedges were used.

Discussion

The incidence of ocular metastasis from breast cancer varies from 5-30% [18,19]. Breast cancer can metastasize to any orbital structure, however the choroid, due to its good vascular supply, is most commonly affected, accounting for 80% of cases [20]. The first documented case of choroidal metastasis was by Perls [21].

Radiotherapy plays a significant role in improving the vision and

preserving the sight, but generally the survival depends on the burden of metastasis in other organs and the degree of their dysfunction [15].

Metastasis to other organs like lung, liver and bone usually precede ocular metastasis [22,23], but in rare cases ocular metastasis could be the initial manifestation of metastatic disease [24]. Involvement of contralateral eye can occur in 5% within 10 months of initial ocular metastasis [25]. The most common manifestation of choroidal metastasis is blurred vision and diminished visual acuity and other symptoms include photophobia, ptosis and exophthalmos [26]. The blurred vision is due to macular involvement or subretinal fluid collection in the fovea [26]. Ten percent of patients with choroidal metastasis are asymptomatic and some authors have suggested ophthalmic screening for this high-risk group [27,28].

The metastatic foci typically appear as a creamy yellow plaque like lesions which are homogenous and located between macula and equator [29]. In addition to systemic treatment, radiation therapy has been used since 1979 in treating ocular metastasis [30], with regression rates in 85-93% using doses ranging from 30-50 Gy. Side effects of cataract, retinopathy, papillopathy and keratopathy can occur in 12% of patients.

The survival of patients with ocular metastasis depends mainly on other organs metastasis and the degree of dysfunction and in one study the survival rate after ocular metastasis was 65% at one year. In our case the patient expired 6 months after diagnosis of his choroidal metastasis, and this could be due to undetected longstanding widespread disease as found on further investigations.

Conclusion

Prognosis of breast cancer has improved significantly with the introduction of targeted agents and the survival of patients with stage IV disease has been prolonged. We can expect more patients with uncommon metastatic sites. Patients with blurred vision should be evaluated promptly by an ophthalmologist and radiation therapy should be offered immediately to preserve the vision.

References

1. Cutuli B, Cohen-Solal LNC, Serine D, Kirov Y, Gaci Z, et al. (2010) Male breast cancer, evolution of treatment and prognostic factors: Analysis of 489 cases. *Crit Rev Oncol Hematol* 73: 246-254.
2. Anderson WF, Altruist MD, Brinton LA (2004) Is male breast cancer similar or different from female breast cancer. *Br Cancer Res* 83: 77-86.
3. Fiala L, Coufal O, Fait V, Fore OL (2010) Male breast cancer: Our experience. *Rozhl Chir* 89: 612-618.
4. Thomas DB, Jimenez LM, McKiernan A (1992) Breast cancer in men: Risk factors with hormonal implications. *Am J Epidemiol* 135: 734-748.
5. Johnson KC, Pan S, Mao Y (1998) Risk factors for male breast cancer in Canada. *Eur J Cancer Prev* 11: 253-263.
6. Ottini L, Masala G, D'Amico C (2003) BRCA1 and BRCA2 mutation status and tumours characteristics in male breast cancer: A population-based study in Italy. *Cancer Res* 63: 342-347.
7. Struewing JP, Coriaty ZM, Ron E (1990) Founder BRCA1/2 mutations among male patients with breast cancer in Israel. *Am J Hum Genet* 65: 1800-1802.
8. Sasco AJ, Lowenfels AB, Pasker-de JP (1993) Review article: Epidemiology of male breast cancer. A meta-analysis of published case control studies and discussion of selected aetiological factors. *Int J Cancer* 53: 538-549.
9. Fentiman IS, Fourquet A, Hortobagyi GN (2006) Male breast cancer. *Lancet* 367: 595-604.
10. Freedman MI, Folk JC (1987) Metastatic tumours to the eye and orbit: Patient survival and clinical characteristics. *Arch Ophthalmol* 105: 1215-1219.

11. Weiss L (1993) Analysis of the incidence of intraocular metastasis. *Brit J Ophthalmol* 77: 149-151.
12. Amer R, Peer J, Cowers I, Ante I (2004) Treatment options in the management of choroid metastases. *Ophthalmol* 218: 372-377.
13. Ferry AP (1967) Metastatic carcinoma of the eye and ocular adnexa. *Int Ophthalmol Clin* 7: 615-658.
14. Olfa G, Riadh H, Sameh T, Fafani BH, Slim BA (2009) Breast cancer discovered from choroid metastasis: Apropos of a case and review of the literature. *Canadian J Ophthalmol* 44: 67.
15. Amichetti M, Caffo O, Minatel E (2000) Ocular metastases from breast carcinoma: A multicentre retrospective study. *Oncol Rep* 7: 761-765.
16. Giordano SH, Buzdar AU, Hortobagyi GN (2002) Breast cancer in men. *Ann Int Med* 137: 678-687.
17. Hodgson NCF, Button JH, Frances DC, Moffatt FL, Livingstone AS (2004) Male breast cancer: Is the incidence increasing. *Ann Surg Oncol* 11: 751-755.
18. Kreusel KM, Wiegel T, Stange M, Bornfeld N, Forester MH (2000) Intraocular metastasis in metastatic female breast cancer. Incidence, risk factors and therapy. *Ophthalmol* 97: 342-346.
19. Nelson C, Hertzberg BS, Klintworth GK (1983) A histopathology study of 716 unselected eyes in patients with cancer at the time of death. *Am J Ophthalmol* 95: 788-793.
20. Shields JA, Shields CL (1992) Metastatic tumours to the intraocular structures. In: Shields JA, Shields CL (eds.) *Intraocular tumours*. Philadelphia: Saunders pp: 207-238.
21. Perl's M (1872) Beitrage zur Geschwulstlehre. *Virchow's Arch* 1: 437.
22. Demirci H, Shields CL, Chao AN, Shields JA (2000) Uveal metastasis from breast cancer in 264 patients. *Am J Ophthalmol* 136: 264-271.
23. Konstantinidis L, Rospond-Kubiak I, Zeolite I (2014) Management of patients with uveal metastases at the Liverpool Ocular Oncology Centre. *Brit J Ophthalmol* 98: 92-98.
24. Solav S, Bhandari R, Sowani A, Saxena S (2010) Choroidal metastasis from carcinoma of breast detected on F18-FDG PET scan CT: A case report and review of literature. *Ind J Nuclear Med* 25: 160-163.
25. Wiegel T, Kreusel KM, Bornfeld N, Bottke D, Stange M, et al. (1998) Frequency of asymptomatic choroid metastasis in patients with disseminated breast cancer: Results of a prospective screening programme. *Brit J Ophthalmol* 82: 1159-1161.
26. Stephens RF, Fields JA (1979) Diagnosis and management of cancer metastatic to the uvea: A study of 70 cases. *Ophthalmol* 86: 1336-1349.
27. Rudoler SB, Shields CL, Corn BW, De-Potter P, Hyslop T, et al. (1997) Functional vision is improved in most patients treated with external-beam radiotherapy for choroid metastases: A multivariate analysis of 188 patients. *J Clin Oncol* 15: 1244-1251.
28. Shields JA, Shields P, De P, Quaranta M, Freire J, et al. (1997) Plaque radiotherapy for the management of uveal metastasis. *Arch Ophthalmol* 115: 203-209.
29. Chen CJ, McCoy AN, Brahmer J, Handa JT (2011) Emerging treatments for choroidal metastases. *Survey Ophthalmol* 56: 511-521.
30. Merrill CF, Kaufman DI, Dimitrov NV (1991) Breast cancer metastatic to the eye is a common entity. *Cancer* 68: 623-627.