

Neurological Improvement after Omental Transplantation on the Upper Cervical Cord

Hernando Rafael^{1*} and Gabriel Polo²

¹Clinica Santa Mónica, Lima, Peru

²Hospital Edgardo Rebagliati Martins, Lima, Peru

Abstract

Background: Since 1986 by the work of Goldsmith, we know that placing omental tissue on the injured spinal cord, we can provoke neurological improvement.

Case report: A 4-year-old girl received a gunshot wound on August 2010., at the upper cervical cord, which was followed immediately by tetraplegia. Lose of respiratory automatism and she was connected to a fan. Preoperative MRI scans revealed a severe ischemic infarct at C2-C3. On July 2011, she received an omental transplantation. During surgery we found abundant scar tissue on the cervical cord between C2 and C3, small intramedullary cyst in the left side, reduction of blood vessels, and 70 percent of cervical cord hypotrophied. On this residual cervical cord a segment of omentum was placed. Two days after surgery, she began with respiratory automatism and voluntary movement of shoulders and right limbs. She could stand up and to walk with aid of orthopedic devices since 4 months after surgery. At present, 4 years after surgery, she(a 9-year-old girl) present partial control of sphincters and motor improvement by 40 percent. During the postoperative evolution she receive rehabilitation and electrical stimulation in the cervical cord.

Conclusions: These results indicate that ischemic neurons and axons in the traumatized cervical cord can improve if is revascularized with omental tissue.

Keywords: Cervical cord; Gunshot wound; Tetraplegia; Respiratory automatism; Omental transplantation

Background

To date, the sequelae of traumatized spinal cord is a challenging condition that only receives rehabilitation as treatment, in spite of previous neurosurgical experiences by means of omental transposition [1-3] or transplantation [4-6] on the affected zone. We report to a patient with severe sequelae in the upper cervical cord caused by a gunshot wound. The patient received an omental transplantation.

Case Report

A 4-year-old girl received a gunshot wound on August 8,2010 at the upper cervical cord, which was followed immediately by loss of alert, tetraplegia and loss of respiratory automatism. Ten days later, a magnetic resonance imaging (MRI) scans revealed a severe ischemic infarct in the cervical cord between C2 to C3 (Figure 1). Since her

admission to the Instituto Nacional de Salud del Niño (Peru), she was connected to a ventilator. During 11 months before surgery, she suffered of pain in the neck, as well as several episodes of pneumonia and urinary tract infection. During these months, she was attended by several peruvian and foreign neurosurgeons and all of them concluded that the patient is not neurosurgical. The examination showed a patient confined to bed, with tracheotomy and connected to an automatic fan. She suffered severe pain in the neck, slight dysarthria and severe weak voice (she was heard at one meter). She presented spastic tetraplegia predominantly in extension, patellar hyperreflexia and clonus at the ankles. The patient's sensory level was at C4, ciliospinal response in both sides, Babinski's sign on the right foot and doubtful on the left. An omental transplantation (free graft with vascular microanastomoses by invagination) was performed on July 2011, in two stages [4,6-10]. First, by means of laparotomy, a 4 x 15 cm segment of omentum was obtained, which contained vascular elements of good caliber. Second, the upper cervical cord was located through a laminectomy at the C2-C3 level.

During surgery we found: 1) leptomeningeal adhesions; 2) abundant fibrosis in the posterior surface of the spinal cord between C2 and C3; 3) small intramedullary cyst (about 5 mm of diameter) in the left side of the cervical cord; 4) reduction of blood vessels, and 5) cervical cord was reduced to 70 percent and 3 cm of height. Previous end-to-end

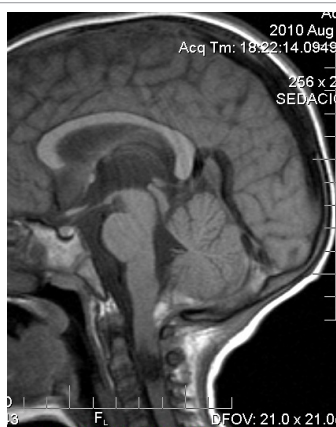

Figure 1: MRI revealing severe ischemic infarct in the cervical cord between C2 to C3.

***Corresponding author:** Hernando Rafael, Bélgica 411-BIS, Colonia Portales, 03300 Mexico City, Mexico, Tel: +52555264 2774; E-mail: hrtumi@yahoo.com

Received September 09, 2015; **Accepted** October 21, 2015; **Published** October 28, 2015

Citation: Rafael H, Polo G (2015) Neurological Improvement after Omental Transplantation on the Upper Cervical Cord. J Trauma Treat 4: 270. doi:[10.4172/2167-1222.1000270](https://doi.org/10.4172/2167-1222.1000270)

Copyright: © 2015 Rafael H, et al. This is an open-access article distributed under the terms of the Creative Commons Attribution License, which permits unrestricted use, distribution, and reproduction in any medium, provided the original author and source are credited.

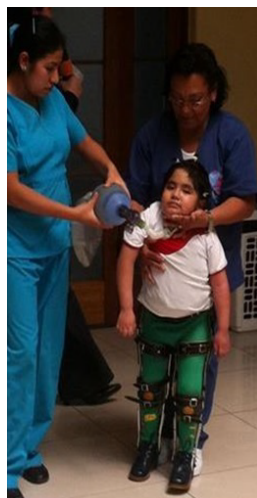


Figure 2: Four months after surgery.

Incomplete Transection	Complete Transection
<ul style="list-style-type: none"> Paraplegia or paraparesis Spasticity Light muscular hypotrophy Anesthesia, hypesthesia or dysesthesia level Loss or partial control of sphincters Bilateral or unilateral Babinski's sign 	<ul style="list-style-type: none"> Paraplegia Flaccidity Moderate or severe muscular hypotrophy Anesthesia level Loss of sphincters control Absent or flexor plantar response

Table 1: Clinical findings in the traumatized spinal cord.

anastomoses by invagination [10] between the right occipital vessels and the gastroepiploic vessels from the omentum, a small segment was placed on the anterior, right lateral and posterior surface of the residual cervical cord, as well as on a part of the superior and inferior normal cord. During the first days after surgery, the temperature of the limbs increased and the spasticity diminished. About 48 hours after surgery, she began with respiratory automatism, voice more intense and with voluntary movement of shoulders and neck. Ten days later, she presented sensory in her hands and voluntary movement, occasionally, in the right limbs. Two months later, the voluntary movement in the right forearm and leg was evident and the pain in the neck disappeared. Four months after surgery, the motor improvement was better and she could stand up and to walk with aid of orthopedic devices (Figure 2). This postoperative picture is recorded on videotape.

One year after surgery, the voluntary movement of shoulders and neck improved by 70 percent and in less degree, in upper limbs and right leg. Moreover, the intensity of the voice to be heard to 15 meters of distance and she tolerated the respiration without ventilator until by 2 minutes in the daytime and 5 minutes during to sleep. It is two years since she suffered a severe respiratory complication by 2 weeks, which was attended at intensive care unit. Postoperative MRI scans (February 2014) showed small omentum at the C2 level and severe degenerative changes in the vertebral body of C3. At present, four years after surgery, she (a 9-year-old girl) present partial control of sphincters and the sensory is still deficient up to the T3 level. The voluntary movement in the right limbs is approximately by 40 percent, specially of proximal predominance. By contrast, the voice and movement of shoulders and neck is better. During whole postoperative evolution she has received rehabilitation, electrical stimulation in the cervical cord and she has been oriented to tolerate the respiration without ventilator.

Discussion

Since November 20, 1987 and to date, we have transplanted omental tissue into about 400 patients with late sequelae in the spinal cord and cauda equina. All of them had dyscomplete or incomplete transection corroborated by means of clinical data [8] and/or MRI scans [4,8]. No patient with complete transection (Table 1) was operated.

The first 192 patients with traumatic spinal cord injury were not selective cases [11] and at the 4.5 year follow-up examination, approximately 40 percent of these operated patients experienced neurological improvement in various aspects of their motor, sensory, tone and sphincters functions. Meanwhile other authors [1,3,12] with selective patients and by means of omental transposition (pedicled graft), they observed a neurological improvement in about 65 percent of the cases [8,12].

Like our patient reported here, two patients were reported previously. Case 1, A 27-year-old man was admitted with a 3-years history of spastic paraplegia and sensory level at T6, caused by a gunshot wound. He received rehabilitation and suffered on various occasions from urinary tract infection. On November 29, 1987, he received an omental transplantation on the thoracic cord at the T4-T6 level [6]. During surgery we found: 1)leptomeningeal adhesions; 2) intramedullary fibrosis ; 3)reduction of blood vessels ; 4)medullar hypotrophy of 40 percent and 2.5 cm of height, and 5) absence of two roots and hypotrophy of others four. The residual cord found corresponded to the anterior and right lateral parts of the spinal cord. After surgery, during the first days, the temperature of the lower limbs increased, the spasticity diminished and the voluntary movement of the toes of the right foot began. Likewise, he began to have anal sphincter control, followed by vesical control two weeks later. About 3 years later on, the sphincters control was almost normal and he presented motor improvement in right lower limbs. During whole postoperative evolution, he received only rehabilitation. Case 2, A 42-year-old man was admitted with a 21- year history of flaccid paraplegia by a gunshot wound at T6-T7. About 26-years of age, he acquired control of both sphincters by 80 percent, as well as penile erection under normal sexual stimulation. For this reason, he contracted marriage and procreated 4 children of 10, 8,4 and 1 year of age, respectively. On October 1988, he received an omental transplantation on the thoracic cord (4). During surgery we found: 1) abundant scar tissue peridural and left intradural; 2) spinal cord reduced to 25 percent of 6 cm length; 3) severe vascular alterations, and 4) absence of two roots and hypotrophy of others. The residual spinal cord corresponded to the anterior and right lateral portion of the thoracic cord. After surgery, he conserved the sphincters control and experienced motor improvement in the muscles of the lumbar region, and the tactile sensation in the right scrotum re-appeared. Moreover, he acquired better control of both sphincters, as well as penile erection and ejaculation. After 10 years of follow-up, motor and sensory evolution in lower limbs remained without changes.

Thus, our 3 patients presented incomplete anatomical transection of the spinal cord and with variable height of lesion; however, all of them demonstrated neurological improvement after surgery. In base to these results, we believe that all patients which incomplete transection must receive omental transplantation to recover the function of the residual nervous tissue in ischemia and ischemic penumbra in the traumatized spinal cord. Because through the omentum, the glia, neurons and axons in the residual spinal cord in ischemia and ischemic penumbra can improve if receives an increase in blood flow, oxygen, neurotrophic factors, adipocytokines and omental stem cells [8,12-15]. Likewise, we

confirm that the clinical analysis in patients with injured spinal cord is most important than the auxiliary studies, A similar conclusion was used for the diagnosis of the spinal or bulbar form of amyotrophic lateral sclerosis [9,16]. Because in this disease, with exception of electrodiagnostic studies, no another auxiliary study can demonstrate minute arteries less than 1 mm in diameter, in the spinal cord and /or medulla oblongata [9].

Finally, we wish to comment on the neurosurgical management in patients with traumatized spinal cord. The first part of the approach should be surgical liberation of the spinal cord and its roots, and second, omental transplantation to the affected zone of the spinal cord and part of the normal cord [4,11]. Besides this, during whole postoperative evolution the patient should receive rehabilitation, especially electrical stimulation of the superior and inferior cord to the affected zone [4,17,18].

Conclusions

Based in our wide experience with omental transplantation on the injured spinal cord, we have not doubt that the function of neurons and axons in the residual spinal cord can improve if circulation is restituted through the omentum and later on, because of neuronal regeneration, gliogenesis and neurogenesis. Besides this, the patients should receive rehabilitation and electrtical stimulation of the superior and inferior normal cord to the affected zone.

References

1. Goldsmith HS, Neil-Dwyer G, Barsoum L (1986) Omental transposition to the chronically injured human spinal cord. *Paraplegia* 24: 173-174.
2. Abraham J (1987) Revascularization of the traumatized spinal cord: Experimental and clinical. In: Vigouroux RP (ed.) *Advances neurotraumatology*. Vol 2, Wien, Springer-Verlag, 171-180.
3. Zheng WJ (1993) Improving greater omentum transposition for treatment of traumatic spinal cord. Presented at the X International Congress of Neurological Surgery Acapulco, Mexico, 325.
4. Rafael H, Malpica A, Ruiz C, Moromizato P, Malo J, et al. (1991) Paraplejia traumática crónica. Diagnóstico y tratamiento (Segunda parte) *Mundo Médico Mex* 18: 11-19.
5. Nagashima C, Masumori Y, Hori E, Kubota S, Kawanuma S, et al. (1991) [Omentum transplantation to the cervical cord with microangioanastomosis]. *No Shinkei Geka* 19: 309-318.
6. Rafael H, Malpica A, Espinoza M, Moromizato P (1992) Omental transplantation in the management of chronic traumatic paraplegia. Case report. *Acta Neurochir (Wien)* 114: 145-146.
7. Rafael H, Moromizato P, Espinoza M, Malpica A (1992) Trasplante de epiplón al cerebelo en pacientes con trombosis de la arteria vertebral. *Diagnóstico* 30: 23-26.
8. Rafael H (1996) El epiplón: Trasplante al sistema nervioso. México DF, Editorial Prado, 55-145.
9. Rafael H, Mego R, Amezcua JP, García W (2011) Omental transplantation for amyotrophic lateral sclerosis. Case report. *J Neurol Sci* 28: 101-108.
10. Cruz HR, López E, Méndez Heredia J, Rubio Díaz F (1986) [Termino-terminal vascular microanastomosis by invagination]. *Salud Publica Mex* 28: 172-175.
11. Rafael H (1997) False localizing signs in upper cervical spinal cord compression. *Neurosurgery* 40: 217-218.
12. Goldsmith HS (1990) The omentum. Present status and future applications. In: Goldsmith HS (ed.) *The omentum: Research and clinical applications*. New York Springer-Verlag 131-145.
13. García-Gómez I, Goldsmith HS, Angulo J, Prados A, López-Hervás P, et al. (2005) Angiogenic capacity of human omental stem cells. *Neurol Res* 27: 807-811.
14. Gimble J, Guilak F (2003) Adipose-derived adult stem cells: isolation, characterization, and differentiation potential. *Cytotherapy* 5: 362-369.
15. Wang T, Yuan W1, Liu Y1, Zhang Y1, Wang Z2, et al. (2015) miR-142-3p is a Potential Therapeutic Target for Sensory Function Recovery of Spinal Cord Injury. *Med Sci Monit* 21: 2553-2556.
16. Rafael H, Mego R (2011) Trasplante de epiplón para isquemia en la medula espinal y oblongada. *Rev Argent Neurosci* 25: 85-89.
17. Bajd T, Kralj A, Turk R, Benko H, Sega J (1989) Use of functional electrical stimulation in the rehabilitation of patients with incomplete spinal cord injuries. *J Biomed Eng* 11: 96-102.
18. Gater DRJr, Dolbow D, Tsui B, Gorgey AS (2011) Functional electrical stimulation therapies after spinal cord injury. *NeuroRehabilitation* 28: 231-248.