

Neurologic Complications after Spinal Surgery: Personal Experience

Salah Fallatah*

Department of Surgery, Faculty of Medicine, Umm Al-Qura University, Kingdom of Saudi Arabia

*Corresponding author: Salah Fallatah, Department of Surgery, Faculty of Medicine, Umm Al-Qura University, Kingdom of Saudi Arabia, Tel: 0555708176/0125501000, extn. 2041; Fax: 0126925387; E-mail: salahmf@mac.com

Rec date: Jan 29, 2015, Acc date: Mar 09, 2015, Pub date: Mar 11, 2015

Copyright: © 2015 Fallatah S. This is an open-access article distributed under the terms of the Creative Commons Attribution License, which permits unrestricted use, distribution, and reproduction in any medium, provided the original author and source are credited.

Abstract

Neurological complications are a potential risk after spine surgery with various reported rates. This a case series of a single surgeon's experience of neurological complications following spine surgery between the 2007-2010 with review of the current recommendations regarding the use of intra-operative neuro monitoring during spine surgery.

In the period between 2007-2010, 215 spine procedures were performed by single surgeon in all regions of the spine for various pathological conditions (deformity, tumor, infection, trauma, and degenerative), 61% were female patients with an average age of 37 years. Patients with preoperative complete neurological loss were excluded from this review. Intra operative neuro monitoring was used in 27 cases. Three patients (1.4%) wake up from surgery with new neurological deficit and after urgent appropriate imaging studies, 2 were taking back to the operating rooms within few hours of their index operation. Both made full recovery of their deficit in the postoperative period. The 3rd patient's lower ext paralysis was observed and over time. He was able to regain his ambulation ability. The incidence of neurological complication in this series is very similar to other reports, higher risk procedures should be done under intra operative neuro monitoring. This report could serve as guide for counseling of patients pre operatively regarding the potential for such adverse effects.

Keywords: Spine; Neurological complication; Paralysis; Neuromonitoring

determine the causative factor of the complication and the final neurologic outcome.

Introduction

New neurologic deficit or deterioration after spinal surgery is a major concern for surgeons and patients. Previous studies have reported that an incidence of significant spinal cord or cauda equina injury after spinal surgery for specific disease entities ranges from approximately 0% to 2%, usually <1% [1-8]. The etiology of neurologic injury during spinal surgery includes direct surgical trauma to the neural elements; compression and/or distraction of the vertebral column [1,9]; vascular compromise, including intra operative or postoperative hypotension [1,2,6,10,11]; compressive spinal epidural or subdural hematoma [12,13]; and mechanical compression from infolding of the ligamentum flavum, posterior longitudinal ligament, or disc or adjacent bony structures [13-22].

Thus, the purpose of this study was to determine such incidence and etiology, and to compare our results with those of other published reports.

Materials and Methods

This was a retrospective review of all patients who underwent any spinal surgery from 2007 to 2010 by a single surgeon. Only those who were neurologically intact preoperatively and had complete medical records were included in the study. Those who developed a documented postoperative neurologic complication (defined as new neurologic motor or sensory deficit) were evaluated further to

Results

A total of 215 spinal surgical procedures were performed on 203 patients. One hundred twenty-three patients (61%) were female and 80 (39%) were male, with an age range of 4-80 years. Only 27 procedures (13%) were performed under intra operative neurologic monitoring. Surgeries were performed for degeneration (n=64, 29.7%), deformity (n=60, 28%), trauma (n=50, 23%), infection (n=20, 9.3%), and tumor (n=9, 4.2%). Surgeries were further classified according to the approach used: anterior procedure (n=37, 17%), combined anterior and posterior procedure (n=24, 11%), and posterior procedure (n=154, 71.6%).

Anterior procedures were performed in 1 (2.7%) deformity case, 15 (40.5%) infection cases, 6 (16%) trauma cases, and 12 (32%) degeneration cases.

Combined anterior and posterior procedures were performed in 3 (12.5%) deformity cases, 3 (12.5%) tumor cases, 2 (8.3%) infection cases, 4 (16%) trauma cases, and 0 (0%) degeneration cases.

Posterior procedures were performed in 56 (36.4%) deformity cases, 3 (1.9%) tumor cases, 3 (1.9%) infection cases, 40 (25.9%) trauma cases, and 52 (33.7%) degeneration cases. In all,

63 (29.3%) surgeries were performed for deformity, 12 (5.5%) for tumor, 22 (10.2%) for infection, 54 (25.1%) for trauma, and 64 (29.7%) for degeneration (Table 1).

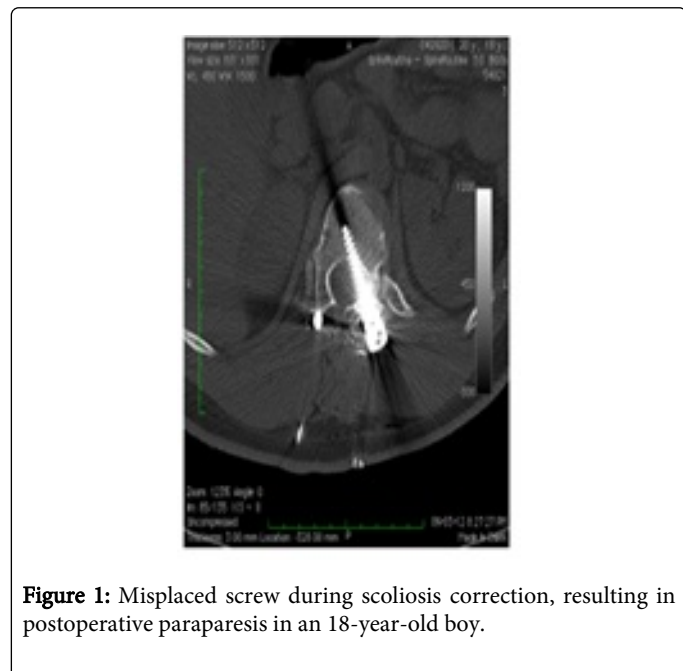
Condition	Total patients	Anterior	Anterior/posterior	posterior	Total surgeries
Deformity	60 (28%)	1 (2.7%)	3 (12.5%)	56 (36.4%)	63 (29.3%)
Tumor	9 (4.2%)	3 (8.1)	3 (12.5%)	3 (1.9%)	12 (5.5%)
Infection	20 (9.3%)	15 (40.5%)	2 (8.3)	3 (1.9%)	22 (10.2%)
Trauma	50 (23%)	6 (16.2%)	4 (16%)	40 (25.9%)	54 (25.1%)
Degenerative	64 (29.7)	12 (32.4%)	0	52 (33.7%)	64 (29.7%)
Total	203 (100%)	37 (17.2%)	24 (11.1%)	154 (71.6%)	215 (100%)

Table 1: Summary of surgical procedures.

Postoperative neurologic complications were defined as any new worsening in the neurological status after surgery for which intervention was needed.

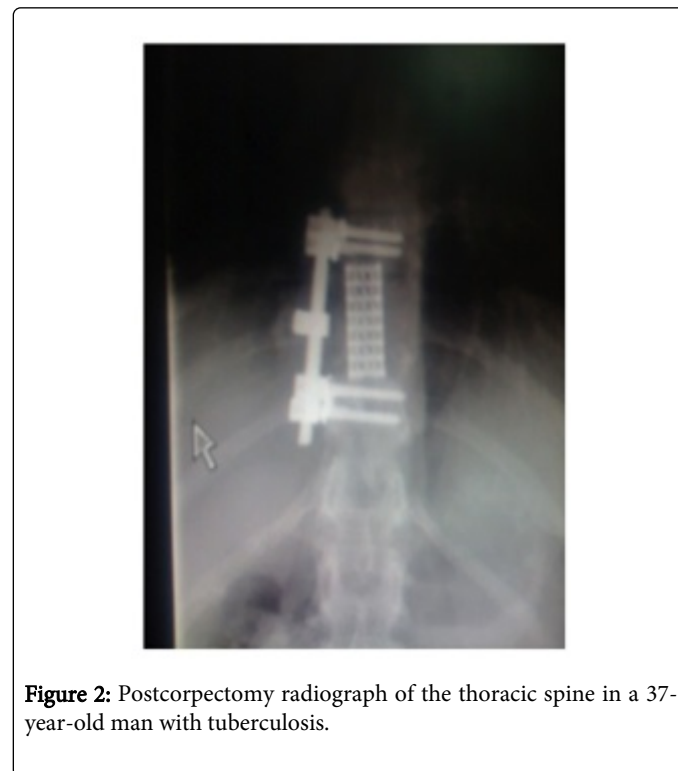
New postoperative neurologic deficits developed in 3 patients (1.4%); none of the surgeries were performed under intra operative neurologic monitoring.

The first case was an 18-year-old man with adolescent idiopathic scoliosis who underwent deformity correction from T4 to L3. Immediately postoperative, the patient was unable to move or feel his lower extremities. Urgent computerized axial tomography scanning and magnetic resonance imaging confirmed a medially placed screw at the T12 on the left side. The patient immediately returned to the operating room, and the screw was removed. He started to recover at postoperative day 13 and made a full recovery after 3 months (Figure 1).



The second case was a 37-year-old man with tuberculosis of the thoracic spine (T8), in whom medical treatment had failed. He underwent a right-side thoracotomy for corpectomy and fusion. Postoperatively, he developed weakness and loss of sensation in his left lower extremity. Urgent computerized axial tomography scanning

showed a bony fragment compressing the spinal cord on the left side. The patient was immediately returned to the operating room, and the spinal cord was decompressed multilaterally through a posterior approach. He started to move his left lower extremity at postoperative day 7 and made a full recovery after 2 weeks (Figure 2).



The last case was a 67-year-old man with metastatic thyroid carcinoma of the T11 in whom radiotherapy had failed to control the disease. He underwent a left-side thoracotomy for T11 corpectomy and instrumented fusion. The patient woke up from surgery unable to move either lower extremity but with his sensations intact. Imaging studies did not show any correctable cause. During removal of the posterior wall of the vertebral body, it was difficult to identify the thickened dura and separate it from other tissues owing to the previous radiotherapy to the area. Excessive manipulation or direct trauma may have occurred during that stage of surgery, with a few episodes of intra operative hypotension. Over the course of 5 weeks, the patient started to regain his motor power, with near complete recovery (Table 2).

Age (years)	Sex	Diagnosis	Procedure	Cause of deficit	Time to recovery
18	male	Idiopathic Scoliosis	Posterior scoliosis correction	Malposition of screw	13 days
36	male	Tuberculosis	Rt. Thoracotomy	Inadequate decompression	7 days
67	male	Metastatic thyroid ca.	Lt. Thoracotomy	Direct trauma	37 days

Table 2: The 3 cases of new post operative neurological deficit.

Discussion

The risk of neurologic deficit is a major concern for patients undergoing spinal surgery. Incidence of such complication is low, and is reversible in some cases. As in other reports, this feared complication occurred in high-risk cases, including deformity correction, thoracotomy procedures, and cases of metastatic tumor with prior radiation. The use of intra operative neurologic monitoring has become a standard of care in such high risk procedures. Meticulous technique and proper attention to intra operative details help maintain the probability of such complication low, and timely and expedient correction of the causative factor, if found, increases the chances of recovery should a deficit occur. Neurologic deficits developed in 1.4% of our patients, all of whom underwent surgery without intra operative neuro monitoring and all made a full recovery with the appropriate intervention. Intra operative neurologic monitoring could have helped to recognize the deficit, which would have allowed the surgeon to reverse its cause [1-8]. The etiology of neurologic injury during spinal surgery includes direct surgical trauma to the neural elements; compression and/or distraction of the vertebral column [1,9]; vascular compromise, including intra operative or postoperative hypotension [1,2,6,10,11]; compressive spinal epidural or subdural hematoma [12,13,23]; and mechanical compression from infolding of the ligamentum flavum, posterior longitudinal ligament, and disc or adjacent bony structures [24-35].

Cramer et al.'s [24] 10-year retrospective study of 11,817 adult spinal surgeries confirmed that spinal instrumentation increases the risk of neurologic injury; 57.1% of cases with new neurologic deficit had instrumentation. In his study, 0.178% (approximately 2:1,000 cases) suffered neurologic injury: 0.293% (approximately 3:1,000 cases) in the cervical spine and 0.488% (approximately 5:1,000 cases) in the thoracic spine. Four patients with inadequate decompression were obese (mean body mass index, 45.8 kg/m²), causing limited surgical exposure secondary to their body habitus. Intra operative neurologic monitoring has become widespread, with the goal of providing feedback to the surgeon and anesthesia team regarding neurologic function. Other reports looked at the post operative complications after spinal surgery in general which included both neurological deficit and non neurological complications, and some looked at a particular complications like incidental durotomy only [36,37]. This one of the strength in this study that it looked into a particular complication after spinal surgery, namely the neurological deficit and excluded other complications. A limitation in our study is that it did not include in cases for intra dural pathology because of the orthopedic background of the treating surgeon [30-34]. Given the rare occurrence of neurologic complications, the number of patients included in this study is too small to draw any statistical conclusion.

Larger studies are still needed to accurately report on these complications. However, this report should serve as a guide for counseling patients prior to undergoing major spinal surgery.

Conclusion

This review reported a low incidence of new postoperative neurologic deficit after spinal surgery. Due to the rare occurrence of such an event, a study with a large number of cases would be needed to identify and statistically analyze the causative factors. Based on our results, intra operative neurologic monitoring should be used more frequently, especially in high-risk cases. The rare potential for such event should be fully explained and discussed with the patient prior to surgery.

References

- Bridwell KH, Lenke LG, Baldus C, Blanke K (1998) Major intraoperative neurologic deficits in pediatric and adult spinal deformity patients. Incidence and etiology at one institution. *Spine (Phila Pa 1976)* 23: 324-331.
- Bridwell KH, Lewis SJ, Edwards C, Lenke LG, Iffrig TM, et al. (2003) Complications and outcomes of pedicle subtraction osteotomies for fixed sagittal imbalance. *Spine (Phila Pa 1976)* 28: 2093-2101.
- Leung YL, Grevitt M, Henderson L, Smith J (2005) Cord monitoring changes and segmental vessel ligation in the "at risk" cord during anterior spinal deformity surgery. *Spine (Phila Pa 1976)* 30: 1870-1874.
- MacEwen GD, Bunnell WP, Sriram K (1975) Acute neurological complications in the treatment of scoliosis. A report of the Scoliosis Research Society. *J Bone Joint Surg Am* 57: 404-408.
- McLaren AC, Bailey SI (1986) Cauda equina syndrome: a complication of lumbar discectomy. *Clin Orthop Relat Res* 143-149.
- Orchowski J, Bridwell KH, Lenke LG (2005) Neurological deficit from a purely vascular etiology after unilateral vessel ligation during anterior thoracolumbar fusion of the spine. *Spine (Phila Pa 1976)* 30: 406-410.
- Padberg AM, Wilson-Holden TJ, Lenke LG, Bridwell KH (1998) Somatosensory- and motor-evoked potential monitoring without a wake-up test during idiopathic scoliosis surgery. An accepted standard of care. *Spine (Phila Pa 1976)* 23: 1392-1400.
- Yonenobu K, Hosono N, Iwasaki M, Asano M, Ono K. (1991) Neurologic complications of surgery for cervical compression myelopathy. *Spine* 16: 1277-1282.
- Tribus CB (2001) Transient paraparesis: a complication of the surgical management of Scheuermann's kyphosis secondary to thoracic stenosis. *Spine (Phila Pa 1976)* 26: 1086-1089.
- Kling TF Jr, Fergusson NV, Leach AB, Hensinger RN, Lane GA, et al. (1985) The influence of induced hypotension and spine distraction on canine spinal cord blood flow. *Spine (Phila Pa 1976)* 10: 878-883.
- Taylor BA, Webb PJ, Hetreed M, Mulukutla RD, Farrell J (1994) Delayed postoperative paraplegia with hypotension in adult revision scoliosis surgery. *Spine (Phila Pa 1976)* 19: 470-474.
- Kou J, Fischgrund J, Biddinger A, Herkowitz H (2002) Risk factors for spinal epidural hematoma after spinal surgery. *Spine (Phila Pa 1976)* 27: 1670-1673.
- Lawton MT, Porter RW, Heiserman JE, Jacobowitz R, Sonntag VK, et al. (1995) Surgical management of spinal epidural hematoma: relationship between surgical timing and neurological outcome. *J Neurosurg* 83: 1-7.
- Sokolowski MJ, Garvey TA, Perl J 2nd, Sokolowski MS, Cho W, et al. (2008) Prospective study of postoperative lumbar epidural hematoma: incidence and risk factors. *Spine (Phila Pa 1976)* 33: 108-113.
- Teplick JG, Haskin ME (1983) Review. Computed tomography of the postoperative lumbar spine. *AJR Am J Roentgenol* 141: 865-884.

16. Brown MD, Brookfield KF (2004) A randomized study of closed wound suction drainage for extensive lumbar spine surgery. *Spine (Phila Pa 1976)* 29: 1066-1068.
17. Payne DH, Fischgrund JS, Herkowitz HN, Barry RL, Kurz LT, et al. (1996) Efficacy of closed wound suction drainage after single-level lumbar laminectomy. *J Spinal Disord* 9: 401-403.
18. Mirzai H, Eminoglu M, Orguc S (2006) Are drains useful for lumbar disc surgery? A prospective, randomized clinical study. *J Spinal Disord Tech* 19: 171-177.
19. Davne SH, Myers DL (1992) Complications of lumbar spinal fusion with transpedicular instrumentation. *Spine (Phila Pa 1976)* 17: S184-189.
20. Thomsen K, Christensen FB, Eiskjaer SP, Hansen ES, Fruensgaard S, et al. (1997) 1997 Volvo Award winner in clinical studies. The effect of pedicle screw instrumentation on functional outcome and fusion rates in posterolateral lumbar spinal fusion: a prospective, randomized clinical study. *Spine (Phila Pa 1976)* 22: 2813-2822.
21. Wilber RG, Thompson GH, Shaffer JW, Brown RH, Nash CL Jr. (1984) Postoperative neurological deficits in segmental spinal instrumentation. A study using spinal cord monitoring. *J Bone Joint Surg Am* 66: 1178-1187.
22. Alleyne CH Jr, Cawley CM, Shengelaia GG, Barrow DL (1998) Microsurgical anatomy of the artery of Adamkiewicz and its segmental artery. *J Neurosurg* 89: 791-795.
23. Cramer DE, Maher PC, Pettigrew DB, Kuntz C 4th (2009) Major neurologic deficit immediately after adult spinal surgery: incidence and etiology over 10 years at a single training institution. *J Spinal Disord Tech* 22: 565-570.
24. Cheshire WP, Santos CC, Massey EW, Howard JF Jr. (1996) Spinal cord infarction: Etiology and outcome. *Neurology* 47: 321-330.
25. Dommissse GF (1974) The blood supply of the spinal cord. A critical vascular zone in spinal surgery. *J Bone Joint Surg Br* 56: 225-235.
26. Ginsburg HH, Shetter AG, Raudzens PA (1985) Postoperative paraplegia with preserved intraoperative somatosensory evoked potentials. Case report. *J Neurosurg* 63: 296-300.
27. Hilibrand AS, Schwartz DM, Sethuraman V, Vaccaro AR, Albert TJ (2004) Comparison of transcranial electric motor and somatosensory evoked potential monitoring during cervical spine surgery. *J Bone Joint Surg Am* 86-86A: 1248-53.
28. Johnston CE 2nd, Happel LT Jr, Norris R, Burke SW, King AG, et al. (1986) Delayed paraplegia complicating sublaminar segmental spinal instrumentation. *J Bone Joint Surg Am* 68: 556-563.
29. Deyo RA, Cherkin DC, Loeser JD, Bigos SJ, Ciol MA (1992) Morbidity and mortality in association with operations on the lumbar spine. The influence of age, diagnosis, and procedure. *J Bone Joint Surg Am* 74: 536-543.
30. Katz JN, Lipson SJ, Brick GW, Grobler LJ, Weinstein JN, et al. (1995) Clinical correlates of patient satisfaction after laminectomy for degenerative lumbar spinal stenosis. *Spine (Phila Pa 1976)* 20: 1155-1160.
31. Katz JN, Lipson SJ, Larson MG, McInnes JM, Fossel AH, et al. (1991) The outcome of decompressive laminectomy for degenerative lumbar stenosis. *J Bone Joint Surg Am* 73: 809-816.
32. Silvers HR, Lewis PJ, Asch HL (1993) Decompressive lumbar laminectomy for spinal stenosis. *J Neurosurg* 78: 695-701.
33. Sanderson PL, Wood PL (1993) Surgery for lumbar spinal stenosis in old people. *J Bone Joint Surg Br* 75: 393-397.
34. Daubs MD, Lenke LG, Bridwell KH, Cheh G, Kim YJ, et al. (2012) Decompression alone vs. decompression and limited fusion for the treatment of degenerative lumbar scoliosis with stenosis *Evid Based Spine Care J* 3: 27-32.
35. Tadokoro K, Miyamoto H, Sumi M, Shimomura T (2005) The prognosis of conservative treatments for lumbar spinal stenosis: analysis of patients over 70 years of age. *Spine (Phila Pa 1976)* 30: 2458-2463.
36. McMahon P, Dididze M, Levi AD (2012) Incidental durotomy after spinal surgery: a prospective study in an academic institution. *J Neurosurg Spine* 17: 30-36.
37. Reis RC, de Oliveira MF, Rotta JM, Botelho RV (2015) Risk of complications in spine surgery: a prospective study. *Open Orthop J* 9: 20-25.