

## Neurogenic Pulmonary Edema: A Case Report

Dr Shagufta Naaz\*

Department of anaesthesiology, critical care and pain management, AIIMS, Patna.

### Abstract

Neurogenic pulmonary edema is an increase in pulmonary interstitial and alveolar fluid as a consequence of injury to central nervous system. It is an underdiagnosed condition. The main cause of its poor recognition is a lack of specific marker of its etiology in order to diagnose and treat it. It has been rarely reported in paediatric age group. We are presenting a case of neurogenic pulmonary edema in a fifteen year old female child.

**Keywords:** Neurogenic pulmonary edema; Central nervous system; Paediatric age

### Introduction

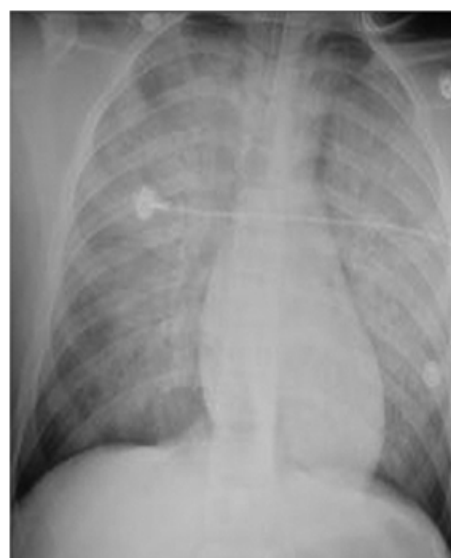Neurogenic pulmonary edema (NPE) is often a subclinical complication arising from many types of brain injury like, trauma, seizures, haemorrhage etc. Till now no specific criteria is there to diagnose it. When a patient of CNS injury develops signs and symptoms of respiratory failure in the absence of any cardiovascular risk factors, NPE should be considered as one of the possible causes. Its pathophysiology is not very well known. It is often confused with aspiration pneumonia. Treatment mainly requires ventilator support, intracranial pressure reduction and treating the cause.

### Case Presentation

A 15 yrs old female had come with the complaints of some psychiatric problem. She also gave the history of head injury 15 days back after being hit with a piece of brick. The attendant gave the history of one episode of convulsions following trauma. Neuromedicine reference was done. A non-contrast CT Scan (NCCT) was done which was found to be normal. According to neurophysicians everything was normal and no intervention was required. She also had the complaint of pain in the loin on the right side. During her clinical investigations she was found to have renal stone in her right kidney for which she was referred to urosurgery department. Percutaneous Nephrolithotomy (PCNL) with DJ stenting was planned by the surgeons under general anaesthesia. Her preanaesthetic checkup was done and she was posted for surgery (Figures 1-3).

The patient was conscious and the vitals were pulse 98/min, BP 120/78, SpO<sub>2</sub> 100% and normal ECG. Preoxygenation was done with 100% oxygen for 3 min. Injection (inj) midazolam 1mg, inj fentanyl 100 mcg and inj glycopyrrolate 0.2 mg was given for premedication. Induction was done with inj thiopentone(2.5%) 250 mg and inj vecuroneum 4 mg was used for muscle relaxation. Patient was intubated with orotracheal tube #7.5 and after inflating the cuff the tube was fixed at 20 cm mark. The patient was put on ventilator on CMV mode with tidal volume of 400 ml/min, RR 12/min and O<sub>2</sub>:N<sub>2</sub>O in 1:1 ratio and flow rate fixed at 1 litre/min for both nitrous oxide and oxygen. Isoflurane 0.6-1% was being used for inhalation. For the initial 1.5 hr the operation went smoothly. But there was no sign of return of spontaneous efforts of the patient as seen on capnograph, hence no vecuroneum injection was supplemented till then (Figure 4).

Suddenly patient started to have convulsions. The patient was given inj thiopentone 50 mg and inj vecuroneum 1mg. The convulsions stopped. Loading dose of injection phenytoin 800 mg was given. The surgery was completed after another 40 min. Inj ondansetron 4 mg, inj



**Figure 1:** Chest X-ray (AP view) of patient: bilateral diffuse infiltrates.

ranitidine 50 mg and inj diclofenac 100 mg was given 30 min before the completion of surgery. Isoflurane was stopped 10 min before and nitrous oxide was stopped at the end of surgery. The patient showed no spontaneous effort by this time. She was kept ventilated. Then after half an hour she showed some signs of spontaneous respiratory efforts. Reversal agent was given which consisted of inj neostigmine 2.5 mg and glycopyrrolate 0.4 mg. But her spontaneous respiratory efforts were inadequate. She tolerated the endotracheal tube well and she had poor response to commands. On chest auscultation bilateral crepitations were felt. So injection furosemide 20 mg was given to her. Also thinking of inadequate reversal inj neostigmine 1 mg and inj glycopyrrolate 0.2 mg were supplemented. Her response improved than before. She was then extubated. Oxygenation was done with the mask

**\*Corresponding author:** Dr Shagufta Naaz, Department of Anesthesiology and Critical Care, UP University of Medical Sciences, Etawah, Uttar Pradesh, India, Tel: 7838117314; E-mail: [dr\\_shagufta\\_naaz@yahoo.co.in](mailto:dr_shagufta_naaz@yahoo.co.in)

**Received:** November 30, 2017; **Accepted:** January 01, 2018; **Published:** January 08, 2018

**Citation:** Naaz S (2018) Neurogenic Pulmonary Edema: A Case Report. J anesthesiol pain res 1: 102.

**Copyright:** © 2018 Naaz S. This is an open-access article distributed under the terms of the Creative Commons Attribution License, which permits unrestricted use, distribution, and reproduction in any medium, provided the original author and source are credited.

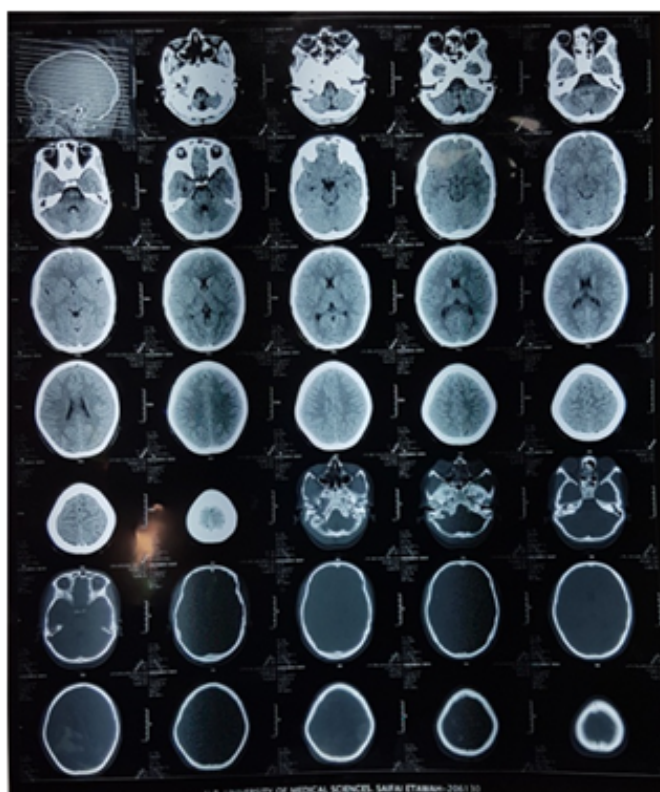


Figure 2: NCCT of skull ---normal finding.

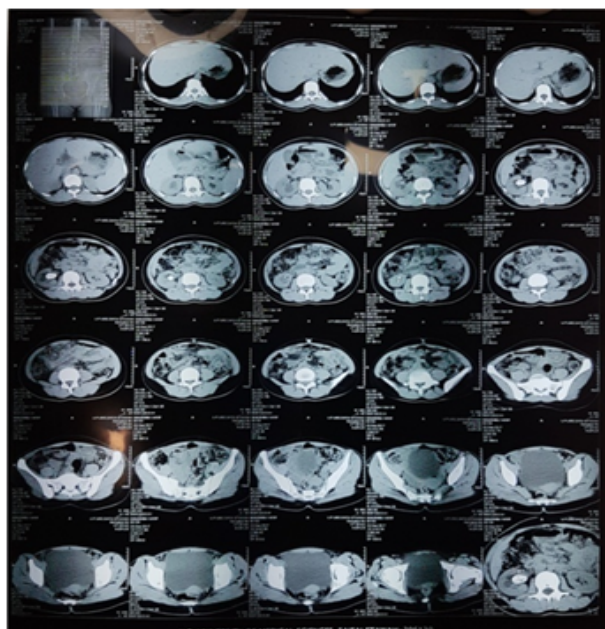


Figure 3: CT abdomen having renal stone.

on Bain circuit. Then a vent mask was placed for oxygenation. In a few minutes her oxygen saturation started to fall. Her  $\text{SpO}_2$  dipped from 100 to 17% and she became cyanosed. Immediately IPPV was given with bag and mask and her oxygen saturation returned to 100%. She was ventilated for some time and again a vent mask was put on. She

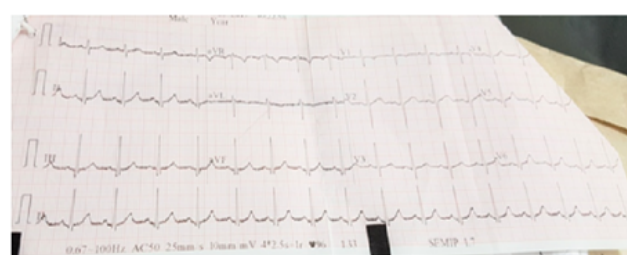

Figure 4: ECG of patient showing normal finding.

responded to commands but didn't seem to be awake and was deeply sedated. Again her saturation started to fall. Again IPPV was given. This time patient vomited. The patient was immediately turned laterally, her head was turned down and suction of the vomitus was done. Injection ondansetron 4 mg was repeated. Injection dexamethasone 8 mg was also given.

Now we decided to intubate the patient after injecting inj thiopentone 200 mg and inj vecuroneum 3 mg. When she was intubated, pink frothy sputum of pulmonary edema started coming out of the orotracheal tube. Suction of the tube was done. It was decided to give IPPV to the patient. The patient was shifted to the SICU where an ABG was done which showed mild acidosis with pH 7.2. The patient maintained normal vitals on CPAP mode of ventilation. Inj phenytion was started at 100 mg TDS. Pink frothy sputum kept coming for many hours. A chest X-ray was done which showed some infiltrates in the chest. Her vitals like pulse, BP and  $\text{SpO}_2$  remained stable in the ICU. After about 7 hours ABG was repeated. This was found to be normal. The patient was found to be conscious and oriented. Pink and frothy sputum were no more coming and her vitals were normal. Neuromedicine reference was done. Injection phenytoin was replaced with injection levetiracetam 500 mg BD. A repeat CT Scan was done but the neurophysician did not detect any organic cause of the seizures.

The patient was stable and was shifted to the ward. For two days she complained of blood stained sputum. She was prescribed inj tranexaemic acid 500 mg tds and injection furosemide 20 mg tds after which this problem subsided. She stayed in the hospital for 6 days after which she was discharged.

## Discussion

Neurogenic pulmonary edema (NPE) was first described by W T Shanahan in 1908 [1]. Since there is difficulty in recognizing and diagnosing NPE due to lack of standard definition on this condition, epidemiological data is rare. Hence it can be said that it is an underdiagnosed condition.

One third of patients having status epilepticus have evidence of NPE [2]. 50% of the patients with severe head injury have associated NPE. About 30-70% of patients with subarachnoid and intracerebral haemorrhage may have NPE which may even recur after initial resolution [3,4]. The underlying condition that leads to NPE determines the outcome. Reported morbidity associated with NPE is 40-50% but mortality is low at about 7% [5]. Besides head injury, NPE has also been seen in conditions like brainstem lesion, acoustic neuroma resection, and ruptured intracranial aneurysm, excessive irrigation during ventriculostomy, post ictal period and pneumocephalus [6].

Two forms of NPE have been described: early and delayed [7].

The early form is common and occurs within minutes to hours after neurologic injury. The delayed form usually starts after 24-48 hrs of the acute CNS injury. NPE is reversible within 48-96 hrs but it may require prolonged ventilation.

Pulmonary edema is characterized by sudden onset breathlessness, tachypnoea, tachycardia, hemoptysis (streaks of blood in sputum), pink frothy sputum, bilateral lung crackles on auscultation, low oxygen saturation on arterial blood gas analysis and bilateral diffuse opacities in chest radiograph [8]. NPE can be confused with cardiovascular conditions, aspiration pneumonia or volume overload causing such pathology.

The pathogenesis of NPE is not fully understood [9]. Various mechanisms have been proposed for its development. Studies done on animals suggest that hypothalamic (paraventricular and dorsomedial nuclei) lesions, stimulation of the vasomotor centers of the medulla (A1 and A5, nuclei of tractus solitarius, area postrema, medial reticulated nucleus and the dorsal motor nucleus of vagus), elevated intracranial pressure and activation of the sympathetic system have roles in the causation of NPE [10,11]. Cervical spinal cord nuclei may also have a role. NPE trigger zones may exist in the structures described above [12].

An acute neurological crisis, associated with a marked increase in intracranial pressure, may stimulate the hypothalamus and the vasomotor centers of the medulla. This gives rise to a massive autonomic discharge mediated by preganglionic centers within the cervical spine which then affects pulmonary vasculature.

Sudden and intense increase in intracranial pressure leading to catecholamine surge is considered as a key etiologic factor behind the development of such complications [13,14]. This has been explained in several ways: neurocardiac, neuro-haemodynamic, blast theory, and pulmonary venule adrenergic hypersensitivity [7].

A marked change in Starling forces occurs as a result of central nervous system event. This governs the movement of fluid between capillaries and the interstitium. Both hemodynamic (cardiogenic) and nonhemodynamic (noncardiogenic) components have their roles in edemaformation.

Change in pulmonary vascular pressures seems to be the most likely starling force to affect NPE formation. An increase in left atrial pressure may occur because of increases in sympathetic tone and venous return. Secondary to the direct effects of catecholamines and other mediators, as well as transient systemic hypertension, left ventricular performance may deteriorate. Thus pulmonary capillary hydrostatic pressures can acutely increase.

The capillary hydrostatic pressure may be increased by sympathetic stimulation and pulmonary edema may be produced without affecting left atrial or pulmonary capillary wedge pressures.

An increase in capillary permeability can result in NPE without increasing pulmonary capillary hydrostatic pressure. Epinephrine, norepinephrine, and even a release of secondary mediators may directly increase pulmonary vascular permeability. Whether the capillary leak is produced by pressure-induced mechanical injury due to the elevated capillary hydrostatic pressure or because of some direct nervous system control over the pulmonary capillary permeability remains obscure.

Pulmonary micro vascular injury can result from an initial and rapid rise in pulmonary vascular pressure due to pulmonary vasoconstriction or pulmonary blood flow. As a consequence, an increase in vascular

permeability causes edema formation, as suggested by the frequent observation of pulmonary hemorrhage in neurogenic pulmonary edema. This is the blast theory [15,16].

Cardiogenic pulmonary edema should be excluded when managing NPE. Echocardiography must be done if in doubt. Some proposed criteria which can differentiate neurogenic pulmonary edema from cardiogenic one are (a) bilateral infiltrates (b)  $\text{PaO}_2/\text{FiO}_2 < 200$  (c) no evidence of lateral arterial hypertension (d) presence of severe CNS injury and (e) absence of other common causes of ARDS [7].

Management involves hemodynamic and respiratory support and measures to keep intracranial pressure within normal limits. For respiratory support positive pressure ventilation with positive end expiratory pressure (PEEP) to improve lung functioning is given [8]. To maintain hemodynamics alpha adrenergic blockers, milrinone or dobutamine may be needed. Diuretics like furosemide and mannitol may be added for the rapid regression of NPE. The patient should be nursed in 30 degree prop up position. Fluid management is also important.

In our patient supportive measures helped to improve the patient's condition within a few hours only. In this case the cause of pulmonary edema could be confused to be aspiration as there was one episode of vomiting post operatively. But crepitations in the lungs were auscultated even before vomiting and sufficient precautions were taken so that patient might not aspirate the vomitus and it did not seem that the patient had aspirated. Moreover there was a history of head trauma and episodes of convulsions about two weeks before surgery and intra operatively. This strongly points the cause to be neurogenic.

## Conclusion

Neurogenic pulmonary edema can occur after any severe injury to the CNS. It can lead to sudden deterioration of patient's condition and hence requires timely diagnosis and treatment. If supportive measures are taken and the cause is treated, it usually resolves.

## References

- Shanahan W (1908) Acute pulmonary edema as a complication of epileptic seizures. *NY Med J* 37: 54-56.
- Khademi S, Frye MA, Jeckel KM, Schroeder T, Monnet E, et al. (2015) Hypoxia mediated pulmonary edema: potential influence of oxidative stress, sympathetic activation and cerebral blood flow. *BMC Physiol* 15: 4.
- Reuter-Rice K, Duthie S, Hamrick J (2011) Neurogenic pulmonary edema associated with pediatric status epilepticus. *Pediatr Emerg Care* 27: 957-958.
- Muroi C, Keller M, Pangalu A, Fortunati M, Yonekawa Y, et al. (2008) Neurogenic pulmonary edema in patients with subarachnoid hemorrhage. *J Neurosurg Anesthesiol* 20: 188-192.
- Bahloul M, Chaari AN, Kallel H, Khabir A, Ayadi A, et al. (2006) Neurogenic pulmonary edema due to traumatic brain injury: evidence of cardiac dysfunction. *Am J Crit Care* 15: 462-470.
- Kumar L S, Durga P, Naik M, Ramachandran G (2010) Neurogenic pulmonary edema -The lurking peril. *Webmed Central Anaesthesia*.
- Davidson DL, Terek M, Chawla LS (2012) Neurogenic pulmonary edema. *Critical Care* 16: 212.
- Sedy J, Zicha J, Kunes J, Jendelova P, Sykova E (2008) Mechanisms of neurogenic pulmonary edema development. *Physiol Res* 57: 499-506.
- Maron MB, Dawson CA (1980) Pulmonary venoconstriction caused by elevated cerebrospinal fluid pressure in the dog. *J Appl Physiol* 49: 73-78.
- Hoff JT, Nishimura M, Garcia-Uria J, Miranda S (1981) Experimental neurogenic pulmonary edema. Part 1: The role of systemic hypertension. *J Neurosurg* 54: 627-631.

11. Baumann A, Audibert G, McDonnell J, Mertes PM (2007) Neurogenic pulmonary edema. *Acta Anaesthesiol Scand* 51: 447-455.
12. Ducker TB, Simmons RL (1968) Increased intracranial pressure and pulmonary edema. The hemodynamic response of dogs and monkeys to increased intracranial pressure. *J Neurosurg* 28: 118-123.
13. Kosnik EJ, Paul SE, Rossel CW, Sayers MP (1977) Central neurogenic pulmonary edema: with a review of its pathogenesis and treatment. *Childs Brain* 3: 37-47.
14. Mutoh T, Kazumata K, Ueyama-Mutoh T, Taki Y, Ishikawa T (2015) Transpulmonary thermodilution-based management of neurogenic pulmonary edema after subarachnoid hemorrhage. *Am J Med Sci* 350: 415-419.
15. Chen WL, Huang CH, Chen JH, Tai HC, Chang SH, et al. (2016) Electrocardiographic abnormalities predict neurogenic pulmonary edema in patients with subarachnoid hemorrhage. *Am J Emerg Med* 34: 79-82.
16. Ridenti FA (2012) Neurogenic pulmonary edema: a current literature review. *Rev Bras Ter Intensiva* 24: 91-96.