

## Neuro Endocrine Breast Tumor: Primary or Secondary Tumor? Case Report and Review of the Literature

Debbagh A<sup>1\*</sup>, Allaoui M<sup>2</sup>, Alaoui Slimani K<sup>1</sup>, Sbitti Y<sup>1</sup>, Bennani F<sup>1</sup>, Ichou M<sup>1</sup> and Errihani H<sup>3</sup>

<sup>1</sup>Department of Medical Oncology, Military General Hospital Mohammed V, Mohammed V- Souissi University, Rabat, Morocco

<sup>2</sup>Department of Pathology, Military General Hospital Mohammed V, Mohammed V- Souissi University, Rabat, Morocco

<sup>3</sup>National Institute of Cancer, Souissi University, Rabat, Morocco

### Abstract

**Background:** Neuroendocrine breast tumors may be primary or secondary with a fairly rare frequency; The diagnosis is based on the results of the pathological findings and the characterization between the primary and secondary origin is guided by the data of radiology (echomammography), the pathological and immunohistochemistry examinations as well as the data reported by the octreoscanner.

**Case presentation:** We describe here a case of a 70-year-old patient who had a dorsal pain for six months. A Scan of rachis showed a tumoral process of the vertebral body of D2 extending intramedullarily. The realization of a thoraco abdomino-pelvic CT scan as part of an assessment of extension, revealed the presence of a left mammary nodule with diffuse liver metsatases. Liver and breast biopsy evoking a localization of a neuroendocrine tumor.

**Conclusion:** This presentation reveals that the Differentiation between primary or secondary neuro endocrine breast tumor is based on the results of the pathological, immunohistochemical findings and radiological characteristics. In the absence of a generalized metastatic disease, the treatment is similar to Invasive breast tumors, under metastasis conditions. The treatment consists of various therapeutical modalities including chemotherapy, hormonotherapy targeted therapies.

**Keywords:** Neuro endocrine; Breast tumor; Metastase; Liver; Mammography; Chemotherapy

**Abbreviations:** NET: Neuro Endocrine Tumor; WHO: World Health Organization; MRI: Magnetic Resonance Imaging; PET: Positron Emission Tomography.

### Introduction

Primary breast Neuroendocrine tumors (NET) referred to as Argyrophilic tumors are a rare form and represent less than 10% of all breast cancers. This entity was defined in 2003 by the World Health Organization (WHO) as a type of invasive mammary carcinoma in which more than 50% of the tumor cells express neuroendocrine markers, with four histological subtypes: 1. Solid-type 2. Neuroendocrine carcinoma 3. Carcinoid-type 4. Small cell carcinoma 5. Carcinoma Neuroendocrine with large cells [1].

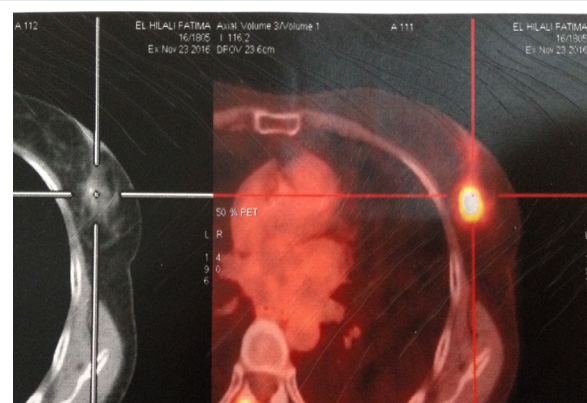
Intramammary metastases are also rare and often synchronous of a multi-metastatic evolution. They represent less than 0.5% of all breast cancers [2]. Intramammary metastases from neuroendocrine tumors (NET) are exceptional and there is no consensus on their therapeutic management. The extent of the exeresis and ganglionic control are the subject of controversy. Furthermore, their differential diagnosis with primitive breast NET is sometimes posed.

### Case Report

Clinical observation of a 60-year-old patient with no significant medical history, who had a dorsal pain for six months. A scan of rachis showed a tumoral process of the vertebral body of D2 extending intramedullarily, a complement of Magnetic Resonance Imaging (MRI) confirming the presence of the vertebral process lateralized on the left side, with bulging of the posterior wall without sign of medullary suffering. The diagnosis of a bone metastasis was posed. The realization of a thoraco abdomino-pelvic CT scan as part of an assessment of extension, revealed the presence of a left mammary nodule with diffuse liver metsatases.

Mammography showed an opacity with a clear macrocalcification

and irregular microcalcifications with a sectoral distribution in the left breast. The mammary ultrasound revealed an irregular formation with spiculate contours, frankly hypoechogenic containing calcifications, in the left breast, this formation measures 16.8 × 23.6 mm with two nodes of the axillary extension. This echomammographic aspect revealed an ACR5. Liver biopsy evoking a localization of a tumor neuroendocrine grade 2, Ki67 to 15% (Figure 1).



**Figure 1:** Hepatic infiltration by a tumour composed of nests and foci of cells with hyperchromatic nuclei (Hematoxylin-Eosin staining).

**\*Corresponding author:** Adil Debbagh, Department of Medical Oncology, Military General Hospital Mohammed V, Mohammed V- Souissi University, Rabat, Morocco, Tel: +223 71 99 02 82; E-mail: [dr\\_raulito@live.fr](mailto:dr_raulito@live.fr)

**Received** March 28, 2017; **Accepted** March 28, 2018; **Published** March 30, 2018

**Citation:** Debbagh A, Allaoui M, Alaoui Slimani K, Sbitti Y, Bennani F, et al. (2018) Neuro Endocrine Breast Tumor: Primary or Secondary Tumor? Case Report and Review of the Literature. J Clin Case Rep 8: 1092. doi: [10.4172/2165-7920.10001092](https://doi.org/10.4172/2165-7920.10001092)

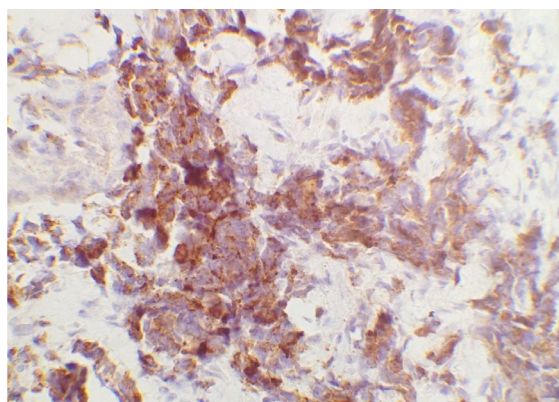
**Copyright:** © 2018 Debbagh A, et al. This is an open-access article distributed under the terms of the Creative Commons Attribution License, which permits unrestricted use, distribution, and reproduction in any medium, provided the original author and source are credited.

**The first question raised: Is there a metastatic neuroendocrine tumor with unknown primitive associated to a mammary neoplasia?**

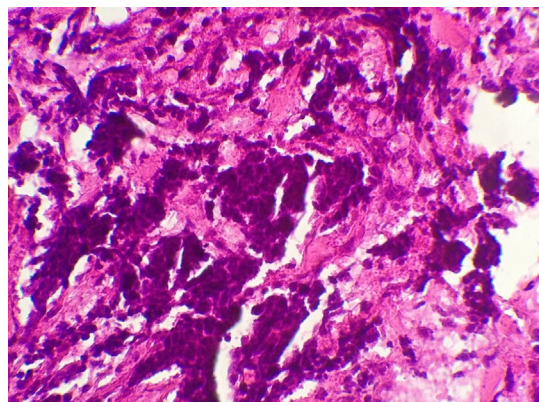
A mammary biopsy oriented towards infiltrating breast carcinoma with neuroendocrine differentiation grade II, KI 67 6%, positive hormonal receptors and negative heceptest (Figures 2 and 3).

**The secondary question raised: Is there a primary neuroendocrine metastatic (bone and liver), breast cancer or metastatic neuroenocrine (breast, bone and liver) of unknown primitive?**

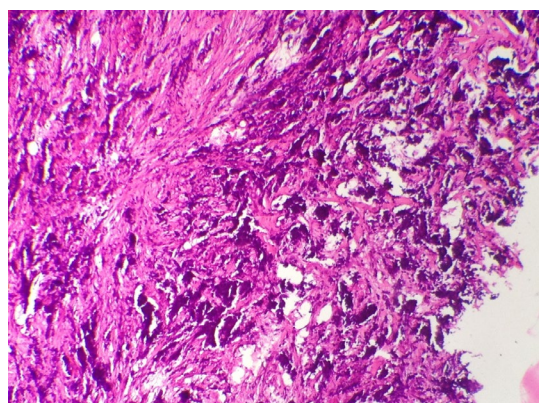
In view of the unavailability of the octreoscanner, a Positron



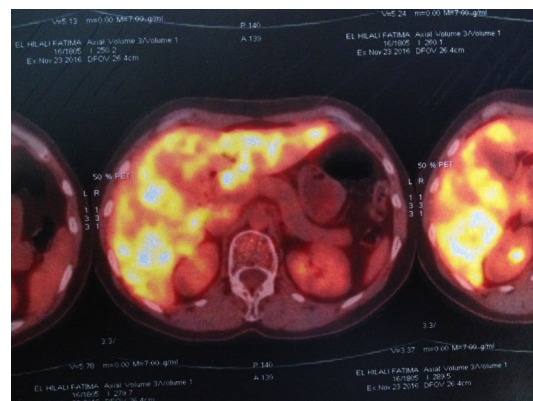
**Figure 2:** Breast infiltration by a proliferation with same architectural and nuclear characteristics (Hematoxylin-Eosin staining).



**Figure 3:** Tumor cells are positive to synaptophysin.



**Figure 4:** PET scann showed a metabolic hyperactivity on the left breast and bone.



**Figure 5:** PET scann showed a metabolic hyperactivity on the liver.

Emission Tomography (PET) scan was performed showing a metabolic hyperactivity on the left breast, liver and bone without any digestive or pulmonary origin (Figures 4 and 5).

Liver and renal function were normal, CA15-3 was 29 U ml. in view of the evolutive and symptomatic profile of the disease, a polychemotherapy was proposed based on anthracyclines according to the protocol FAC with zoledronic acid after dental care, after two cycles of chemo the patient reports a clear clinical benefit and a disappearance of spinal pain. A reassessment by a thoraco abdomino pelvic CT scan will be performed after the third cycle of chemotherapy.

## Discussion

Primary breast NET is very rare, their frequency is estimated at 0.3%-0.5% of all breast cancers [3]. They correspond to invasive mammary carcinomas, generally with low or intermediate nuclear grade, and whose morphological characteristics are similar to the digestive or pulmonary NET [4]. More than 50% of the tumor cells express neuroendocrine markers whose positivity confirms the diagnosis

The clinical presentation of secondary NET is different, they are multiple and bilateral, which has not been observed in our case. It is exceptional that it is the discovery of the breast involvement leading to the diagnosis of the primitive extramammary NET [5], in our case the mamary lesion was discovered in the CT scan work up of the suspect bone lesion.

Radiologically, a secondary NET often take the form of rounded and multiple masses. According to Gunhan, the common radiological sign of primary breast neuroendocrine tumors was a high-density mass with margins primarily spiculated or lobulated on mammography, which has been reported in our case [6]. Microcalcifications are less frequent in primary breast neuroendocrine neoplasms than in other mammary carcinomas [7,8] Somatostatin analog scintigraphy (octreotide, lanreotide Pentetreotide) or octreoscan, which is based on the overexpression of somatostatin receptors by neuroendocrine cells, often shows the presence of multiple lesions in the secondary NETs; unfortunately this examination is unavailable in our training, although this examination is negative in one third of the cases, due to the absence of this overexpression and the false positives due to infectious and inflammatory lesions [9].

The histological diagnosis of primary neuroendocrine tumors of the breast is based on optical microscopy on the distinction of an endocrinoid morphotype. It is mainly expressed by a lobulated

tumor architecture, which is associated with a rich vascularization of the capillary type, and by an arrangement of cells in massifs or spans with sharp edges, the most peripheral cells are readily disposed in “palisade” [10].

When there is doubt between a primary or secondary mammary NET, the histological analysis may be contributory. The presence of a component of carcinoma *in situ* associated with the NET is orienting to a primitive breast origin [11]. Hormone receptors are generally expressed in well-differentiated NETs and in more than half of small cells differentiated neuroendocrine breast carcinomas [4].

In the literature, the expression of HER2 has been very little studied in primitive breast neuroendocrine tumors given the rarity of this entity, however the majority of authors agreed on the negativity of HER2, [12] which matches our clinical case. Based on the data from the literature and after the studying our case we focus more on a probability of a primitive neuroendocrine breast disease than on a metastatic neuroendocrine breast neoplasia.

**Unfortunately, there are no immunohistochemical biomarkers or markers being able to differentiate between a primitive or a secondary origin**

The treatment of primitive Neuroendocrine tumors of the breast is mainly surgical. Chemotherapy and radiotherapy are used to treat Neuroendocrine however with no significant changes to chemotherapy and radiotherapy administered in other breast cancer types. There is no standard chemotherapy protocol [12,13]. There are four main classes of effective agents:

- Intercalating,
- Anti-metabolites,
- Alkylating agent
- The spindle poison

In case of small cell carcinoma, chemotherapy including a platinum-based therapy is indicated [13]. In the case of a multimetastatic visceral or bone evolution, which is the case in our patient, loco-regional treatment generally has no benefit. Systemic treatment is proposed in the first intention, [14].

In the literature, primitive neuroendocrine tumors of the breast have only been discovered in the metastasis stage in rare cases [12].

In our case it was a multimetastatic and symptomatic disease on the bone, the mammary local treatment was not discussed however a local spinal surgery or radiotherapy were proposed but not retained that's why we have introduced anthracycline based chemotherapy according to the protocol FAC and zoledronic acid.

The prognosis of NET is related to the grade and stage of the tumors, but not to their differentiation [15]. However, in some series of breast NET, a more favorable or unfavorable prognosis was observed in comparison with other invasive mammary carcinomas [12,15].

## Conclusion

Neuroendocrine tumors of the breast are rare tumors, they may be primitive or secondary. Differentiation between primary or secondary

origin is based on the results of the pathological, immunohistochemical findings and radiological characteristics.

In the absence of generalized metastatic disease, the treatment is similar to Invasive breast tumors, under metastasis conditions, treatments consist of various therapeutical modalities including chemotherapy, hormonotherapy, targeted therapies and the decision remains variable from one case to another, from where the interest of presenting each case in a multidisciplinary concertation.

For a better understanding of this pathology and for a better characterization of the primitive or secondary nature of the breast NET multicentric wider studies are necessary.

## References

1. Tavassoli FA, Devilee P (2003) Pathology and genetics. In: Tumors of the breast and female genital organs. WHO classification of tumors series. Lyon: IARC Press 32-34.
2. Koch A, Richter-Marot A, Wissler MP, Baratte A, Mathelin C (2013) Mammary metastasis of extramammary cancers: current knowledge and diagnostic difficulties. Gynecol Obstet Fertil 4: 653-659.
3. Bofin AM, Qvigstad G, Waldum C, Waldum HL (2002) Neuroendocrine differentiation in carcinoma of the breast. Tyramide signal amplification discloses chromogranin A-positive tumour cells in more breast tumours than previously realized. APMIS 110: 658-664.
4. Lakhani S, Ellis I, Schnitt S (2012) WHO classification of tumours of the breast, Lyon: IARC Press.
5. La Rosa S, Casnedi S, Maragliano R, Goyault G, Weber JC, et al. (2015) Breast metastasis as the first clinical manifestation of ileal neuroendocrine tumor: A challenging diagnosis with relevant clinical implications. Endocr Pathol 26: 145-151.
6. Gunhan IB, Zekioglu O, Ustun EE, Memis A, Erhan Y (2003) Neuroendocrine differentiated breast carcinoma: imaging features correlated with clinical and histopathological findings. Eur Radiol 13: 788-793.
7. Boufettal H, Noun M, Mahdaoui S, Heras S, Samouh N (2011) Une tumeur d'origine inhabituelle : Le carcinome endocrine mammaire primitif. Imag Femme 21: 35-38.
8. Psoma E, Nikolaidou O, Stavrogianni T, Mavromati A, Lytras K, et al. (2012) A rare case report of a primary large-cell neuroendocrine carcinoma of the breast with coexisting Paget disease. Clin Imaging 36: 599-601.
9. Granberg D, Sundin A, Janson ET, Oberg K, Skogseid B, et al. (2003) Octreoscan in patients with bronchial carcinoid tumours. Clin Endocrinol 59: 793-799.
10. El HF, Hammas N, Moumna K, Bedahou M, Mellas N, et al. (2011) Carcinome neuroendocrine du sein : à propos d'un cas et revue de la littérature. Pan Afr Med J 13: 40.
11. Tang F, Wei B, Tian Z, Gilcrease MZ, Huo L, et al. (2011) Invasive mammary carcinoma with neuroendocrine differentiation: histological features and diagnostic challenges. Histopathology 59: 106-115.
12. Wei B, Ding T, Xing Y, Wei W, Tian Z, et al. (2010) Invasive neuroendocrine carcinoma of the breast. A distinctive subtype of aggressive mammary carcinoma. Cancer 116: 4463-4473.
13. Ghanem SS, Glaoui M, Naciri S, Khoyaali S, Kabbaj M, et al. (2011) A rare tumor of the breast: solid neuroendocrine carcinoma. WebmedCentral BREAST 2: WMC001591.
14. Inno A, Bogina G, Turazza M, Bortesi L, Duranti S, et al. (2015) Neuroendocrine carcinoma of the breast: current evidence and future perspectives. Oncologist 21: 28-32.
15. Miremadi A, Pinder SE, Lee AH, Bell JA, Paish EC, et al. (2002) Neuroendocrine differentiation and prognosis in breast adenocarcinoma. Histopathology 40: 215-222.