

## Myelopathy in a Patient with Severe Diabetic Neuropathy

Seyed M Mirsattari\* and Donald H Lee

Departments of Clinical Neurological Sciences and Medical Biophysics, University of Western Ontario, B10-108, 339 Windermere Road, London, Ontario, Canada

### Abstract

Diabetic myelopathy is a common pathological finding in patients with diabetes mellitus, but its manifestations can be masked by advanced diabetic neuropathy. This case illustrates that it should be suspected in all diabetic patients with subacute progressive symptoms affecting all extremities even in the absence of dysfunction of bowel/bladder sphincters.

### Case Report

A high functioning 68-year-old man had known severe longstanding diabetic neuropathy that had resulted in gangrene toes with amputation of several toes and ataxia requiring a cane for ambulation. He developed a subacute onset of severe pain over the neck and shoulders followed by rapidly progressive weakness and paresthesia of the limbs and deterioration of his gait over three months. He gradually became bedridden with progressive loss of his driving abilities, feeding, shaving and ambulation unless using a walker. He had quadraparesis, ataxic gait, brisk reflexes except for absent ankle jerks, sensory gradient to pinprick and temperature sensations at the level of knees and elbows, impaired vibration, sensations and proprioception in all four limbs. Plantar responses could not be assessed on the right because of toe amputation and equivocal on the left. MRI of the spinal cord revealed severe focal myelopathy at C3-4 with central prolapse of the intervertebral disc and degenerative changes of the spine at that level (Figure 1 and 2, arrows) and less severe changes in the remainder of the cervical spine. Urgent decompressive laminectomy resulted in return of some function to almost near baseline but some persistence of the brisk reflexes and severe pain.

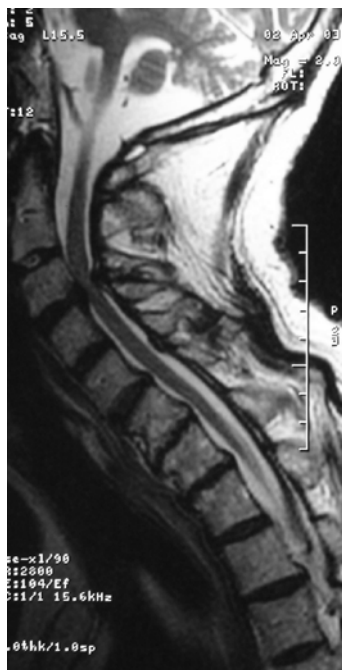


Figure 1: MRI of the spinal cord

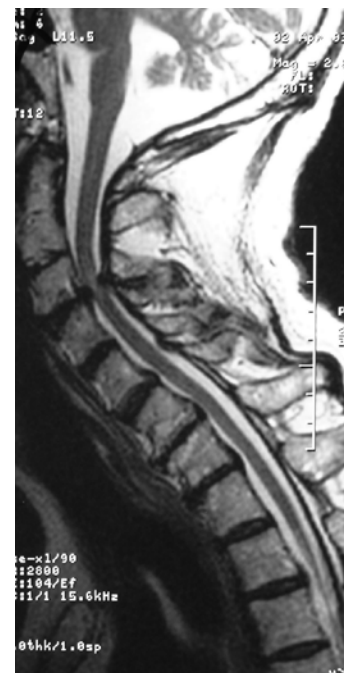

Figure 2: MRI of the spinal cord

### Discussion

Diabetic myelopathy is seemingly an uncommon clinical disorder [1,2] that is encountered in up to 41% of the cases in autopsy [3]. It should be suspected in all diabetic patients with subacute progressive symptoms affecting all extremities even in the absence of dysfunction of bowel/bladder sphincters. Patients with diabetic myelopathy invariably have advanced pre-existing neuropathy [3]. The presence of pyramidal signs in such patients can be suggestive of diabetic myelopathy. This case illustrates that not all the clinical manifestations of such patients can be attributed to the visible changes in MRI but neuroimaging

\*Corresponding author: Seyed M Mirsattari, Assistant Professor, Departments of Clinical Neurological Sciences and Medical Biophysics, University of Western Ontario, B10-108, 339 Windermere Road, London, Ontario, N6A 5A5, Canada, Tel: (519) 663-3348; Fax: (519) 663-3440; E-mail: [smirsat2@uwo.ca](mailto:smirsat2@uwo.ca)

Received March 17, 2012; Accepted April 22, 2012; Published May 02, 2012

Citation: Mirsattari SM, Lee DH (2012) Myelopathy in a Patient with Severe Diabetic Neuropathy. J Clin Case Rep 2:139. doi:10.4172/2165-7920.1000139

Copyright: © 2012 Mirsattari SM, et al. This is an open-access article distributed under the terms of the Creative Commons Attribution License, which permits unrestricted use, distribution, and reproduction in any medium, provided the original author and source are credited.

studies can help to demonstrate the complex pathology [4] of this disorder so that surgical candidates can receive appropriate therapy even if the recovery is partial.

#### References

1. Giladi N, Turezkite T, Harel D (1991) Myelopathy as a complication of diabetes mellitus. *Isr J Med Sci* 27: 316-319.
2. Anderson TJ, Donaldson IM, Scott RS (1987) Diabetic focal myelopathy. *Clin Exp Neurol* 24: 139-143.
3. Slager UT (1978) Diabetic myelopathy. *Arch Pathol Lab Med* 102: 467-469.
4. DeJong RN (1977) CNS manifestations of diabetes mellitus. *Postgrad Med* 61: 101-107.