

Monoclonal Antibody Therapy for Neuromyelitis Optica: A Systematic Review and Meta-Analysis

Caranfa JT^{1*}, Kohn CG¹, Baker WL² and Waitzman DM³

¹University of Connecticut-School of Medicine, Farmington, Connecticut, USA

²University of Connecticut-School of Pharmacy and UConn/Hartford Hospital Evidence-based Medicine, Hartford, Connecticut, USA

³Department of Ophthalmology, Division of Neuro-ophthalmology, University of Connecticut, Farmington, Connecticut, USA

Abstract

Background: Neuromyelitis optica (NMO) and NMO spectrum disorder (NMOSD) is a rare autoimmune disorder that often leaves patients severely disabled, despite aggressive treatment with traditional immunosuppressive medication. While monoclonal antibody therapy has shown efficacy in treating NMO/NMOSD, no large randomized control trials exist. In lieu of such trials, we performed a systematic review and meta-analysis to assess the efficacy and safety of rituximab, eculizumab and tocilizumab in NMO/NMOSD patients.

Methods: We searched MEDLINE, the Cochrane Central Register of Controlled Trials (CENTRAL) and Embase from January 1, 2006 through December 31, 2018 for prospective studies using rituximab, eculizumab or tocilizumab in NMO/NMOSD patients and reporting annual relapse rate (ARR) and Expanded Disability Status Scale (EDSS) score before and after monoclonal therapy.

Results: Sixteen studies involving 324 patients were included in the systematic review and meta-analysis. Monoclonal therapy resulted in a statistically significant mean reduction in ARR of 1.77 (95% CI, 1.37 to 2.17) and a statistically significant mean reduction in EDSS of 1.14 (95% CI, 0.87 to 1.41).

Conclusion: Treatment with monoclonal antibodies, specifically rituximab, eculizumab and tocilizumab, significantly reduced the frequency of disease relapses and improved neurological disability in NMO/NMOSD patients.

Keywords: Neuromyelitis optica; Devic's disease; Monoclonal antibodies; Rituximab; Tocilizumab; Eculizumab

Introduction

Classically, neuromyelitis optica (NMO) is a severely debilitating demyelination disease of the central nervous system (CNS) that affects both optic nerves and the spinal cord. The more recent literature has distinguished between NMO and NMO spectrum disorder (NMOSD), expanding criteria to incorporate cases of either unilateral or bilateral optic neuritis (ON), longitudinally extensive transverse myelitis (LETM) and/or area postrema syndrome [1]. Often the early clinical manifestations of NMOSD and multiple sclerosis (MS), another central demyelinating disorder, may overlap (e.g., acute ON, internuclear ophthalmoplegia (INO), transverse myelitis), leading to a misdiagnosis of MS. In contradistinction to MS, NMOSD primarily targets central visual pathways and the spinal cord, causing permanent disability. Therefore, distinguishing between these diseases is critical. Approximately 75% of patients with NMOSD demonstrate IgG antibodies directed against aquaporin 4 water channels (AQP4-IgG) on CNS astrocytes which are not only highly specific for NMOSD but most likely participate in the pathology of the disease [2,3]. Therefore, AQP4-Ab assays are crucial in distinguishing NMOSD from MS and have been helpful in predicting disease severity and duration [4].

NMOSD is similar to other autoimmune diseases in that it more often affects women with a mean age of 39 years. However, in contrast to MS, NMOSD affects a slightly older population and is more common in non-Caucasians [5]. Untreated, this disease follows a relapsing progressive course resulting in increased neurological disabilities [2,6]. As a result, prompt initiation of therapy and lifelong immunosuppression are paramount for this patient population.

Recent evidence points to B-cell mediated humoral immunity as an integral component in the pathogenesis of NMOSD. Rituximab, a monoclonal antibody that targets the CD20 receptor on pre-B cells, has been shown to reduce relapse rates and neurological disability.

However, a subset of patients remain refractory to treatment or experience disease progression despite treatment with rituximab [2-6]. As such, alternative monoclonal antibodies such as eculizumab and tocilizumab, which target specific complement proteins (complement protein 5 (C5)) or inflammatory chemokines (interleukin 6 (IL-6)) respectively, have been proposed as treatment alternatives [7,8]. To date only one previous quantitative study has evaluated the safety and efficacy of monoclonal therapy in NMOSD, however this study was confined to rituximab [2]. In this study, we sought to systematically identify, summarize and analyze information concerning relapse rates and degree of neurological disability before and after treatment with rituximab, eculizumab and tocilizumab in patients with NMOSD.

Literature Review

This meta-analysis conforms to standard guidelines and is written in accordance with the Preferred Items for Systematic Review and Meta-Analyses (PRISMA) statement [9].

We conducted a systematic literature search in MEDLINE, Cochrane Central Register of Controlled Trials (CENTRAL), and Embase from January 1, 2006 through December 31, 2018 using the terms neuromyelitis optica and rituximab, neuromyelitis optica and eculizumab or neuromyelitis optica and tocilizumab.

***Corresponding author:** Caranfa JT, University of Connecticut-School of Medicine, Farmington, Connecticut, USA, Tel: +(860) 930-3937; E-mail: caranfa@uchc.edu

Received October 9, 2019; **Accepted** October 15, 2019; **Published** October 22, 2019

Citation: Caranfa JT, Kohn CG, Baker WL, Waitzman DM (2019) Monoclonal Antibody Therapy for Neuromyelitis Optica: A Systematic Review and Meta-Analysis. J Neurol Disord 7: 412

Copyright: © 2019 Caranfa JT, et al. This is an open-access article distributed under the terms of the Creative Commons Attribution License, which permits unrestricted use, distribution, and reproduction in any medium, provided the original author and source are credited.

Two investigators independently reviewed all citations and screened potentially relevant articles for inclusion using a priori defined criteria, with disagreements resolved by discussion or by a third investigator. To be included in this systematic review, studies had to

- Employ an observational or experimental study design;
- Be Prospective in nature;
- Evaluate patients with NMO or NMOSD receiving either rituximab, eculizumab, or tocilizumab, alone or with a comparator arm;
- Provide data quantifying outcomes; and
- Be An English-language, full-text publication.

A preliminary search did not reveal any randomized control trials (RCTs). In order to increase the strength of evidence of included studies, we excluded studies that were retrospective in nature, including case studies, case series and retrospective chart reviews. Two investigators independently determined study eligibility, with disagreements resolved by discussion or by a third investigator.

For each study, participant characteristics, study design, treatment regimens and outcome measures were extracted. The primary efficacy outcomes evaluated were the mean difference in annual relapse rate (ARR) and Expanded Disability Status Scale (EDSS) score before and after monoclonal antibody treatment. Safety was assessed through the reporting of significant adverse events. Two investigators independently abstracted all data using a standardized data abstraction tool.

Outcomes were pooled using a Hartung-Knapp random-effects meta-analysis utilizing inverse-variance weighting [10,11]. Between-study variance was estimated using the Paule-Mandel estimator [12]. Continuous outcomes are reported as mean differences with corresponding 95% confidence intervals (CI). We assessed presence of statistical heterogeneity using the Cochrane p-value ($p < 0.10$ significant) and the I² statistic which represents the percentage (0-100%) of variability in the treatment estimate that is attributable to heterogeneity [13]. The presence of publication bias was assessed using visual funnel plot inspection and Egger's test of plot asymmetry when 10 or more studies reported a given outcome [14]. Statistical significance was set at a two-sided alpha of 0.05. All analyses were performed using the 'meta' package (version 4.9-0) in R 3.4.3 (www.r-project.org).

Results

Sixteen prospective studies were included in the systematic review and meta-analysis [15-28], representing a total of 324 patients (89% female) treated with either rituximab, eculizumab or tocilizumab (Figure 1). Characteristics of the included trials are detailed in Table 1. The mean age of patients at the onset of treatment ranged from 33-54 years. AQP4-IgG serostatus was reported in 14 of 16 studies with a range of 39% to 100% of patients testing positive. The mean disease duration at treatment onset was between 1-13 years. Rituximab regimens varied between studies with the majority of patients (41%) receiving 1 g every 2 weeks for 2 doses, 28% of patients received 375 mg/m² weekly for 4 weeks, 15% received 100 mg every week for 3-4 weeks and 16% received a different therapeutic regimen. Eculizumab and tocilizumab dosing was consistent across studies at 600 mg every week for 4 weeks and 8 mg/kg every month for up to 24 months, respectively. In 29% of patients, monoclonal antibodies were the first-line treatment, whereas the remaining patients received a variety of initial therapies: 46% received immunosuppressive drugs, 14% received immunomodulatory drugs, 9% received intravenous immunoglobulin (IVIG) and 4% had failed treatment with rituximab.

Relapse rates were reported in 15 studies (n = 319) [7,8,15-17,19-28]. Results of the mean difference in ARR before and after monoclonal antibody treatment are shown in Figure 2. Overall, monoclonal antibody therapy resulted in a statistically significant mean reduction in ARR of 1.77 (95% CI, 1.37 to 2.17). However, significant heterogeneity was detected, represented by an I² of 82%. Neither visual inspection of the funnel plot (Figure S1) nor the Egger's regression test ($p = 0.20$) suggested significant small study bias.

The EDSS score was reported in 14 studies (n = 282) [7,8,15,16,18-25,27,28]. Results of the mean difference in EDSS score before and after monoclonal antibody treatment are shown in Figure 3. Overall, monoclonal antibody therapy resulted in a statistically significant mean reduction in EDSS of 1.14 (95% CI, 0.87 to 1.41). No between

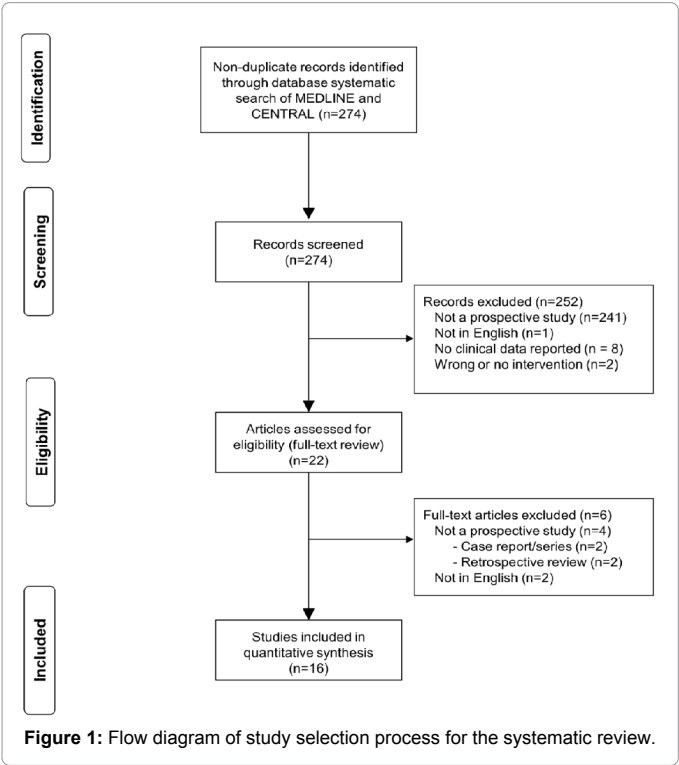
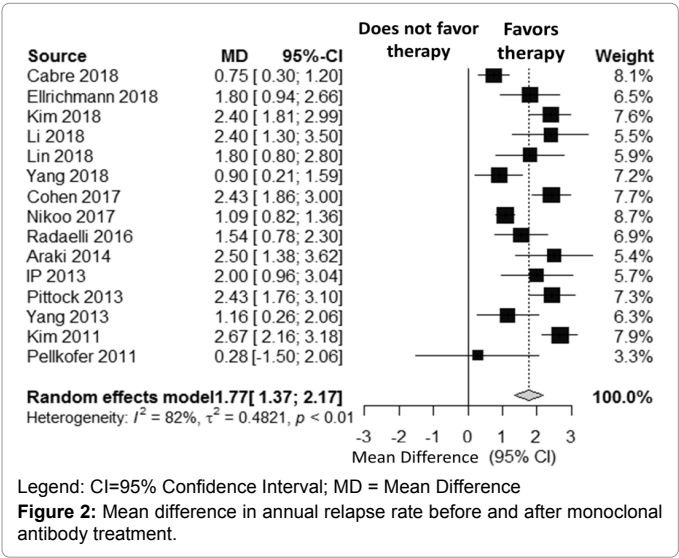
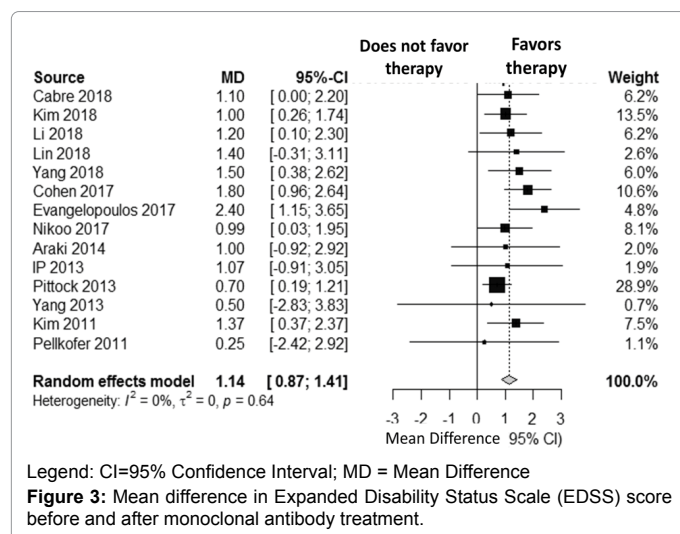


Figure 1: Flow diagram of study selection process for the systematic review.





study heterogeneity was detected ($I^2 = 0\%$). Neither visual inspection of the funnel plot (Figure S2) nor the Egger's regression test ($p=0.39$) suggested significant small study bias.

Significant adverse effects were reported in 25.6% (83/324) of patients. Specifically, 45 patients (13.9%) had a reactivation of a latent pathogen or a primary infection (3 patients developed sepsis and 1 patient developed tuberculosis), 23 patients (7.1%) experienced an infusion-related and/or allergic reaction, 8 patients (2.5%) developed leukopenia, 2 patients (0.6%) developed anemia, 2 patients (0.6%) developed enterocolitis, 1 patient (0.3%) developed rheumatoid arthritis, 1 patient experienced a transient ischemic attack (TIA) and 1 patient (0.3%) died (Table 1). Feared outcomes of monoclonal antibody therapy such as progressive multifocal leukoencephalopathy (PML) and invasive fungal infections were not observed.

Discussion

Clinical data from a variety of studies have shown monoclonal antibodies are efficacious in the treatment of NMOSD but small sample sizes, lack of controlled trials and heterogeneity of the treatment populations have limited their widespread use. The current meta-analysis is one of the first to confirm that treatment with a variety of monoclonal antibodies reduces relapse rates and can prevent development of additional neurological disability.

While the overall sample size of our systematic review and meta-analysis is small, the evidence demonstrated monoclonal antibody therapy, across 15 studies ($n = 319$), resulted in a statistically significant mean reduction in ARR of 1.77 (95% CI, 1.37 to 2.17) in patients with NMOSD. Similarly, monoclonal antibody therapy, across 13 studies ($n=282$), resulted in a statistically significant improvement in neurological disability over the course of treatment (mean reduction in EDSS scores of 1.14 (95% CI, 0.87 to 1.41)). Due to the relative paucity of studies and the lack of multi-armed trials, we were not able to perform an indirect treatment comparison assessing the efficacy and safety of each monoclonal antibody compared to one another. However, despite the small sample size of patients in the available literature ($n = 14$ and 7 for eculizumab and tocilizumab respectively) reductions in ARR and EDSS scores were similar to those seen in the rituximab trials.

Despite an overall positive effect, reductions in EDSS scores were

not consistent across all studies. Notably, patients with a longer duration from disease onset to initiation of monoclonal antibody therapy had only slight reductions or stable EDSS scores following therapy [7,8,15,19,21,24-27]. Meta-regression analysis by Damato et al. published similar findings, showing a negative correlation between disease duration and improvement in disability following rituximab therapy [2]. This suggests that earlier introduction of monoclonal antibody therapy, at the point of disease recognition, could better preserve neurological function.

Finding a treatment that can abort the disease process at an early stage is crucial for neuro-ophthalmologists. Close to 50% of NMOSD patients present with unilateral ON resulting in significant and often permanent loss of visual acuity secondary to optic atrophy [29]. Historically, 60% of NMO patients will eventually experience uni- or bilateral blindness compared with 4% of MS patients with a median time from initial onset of ON to ipsilateral blindness of two years and contralateral blindness of three years [3]. Therapeutic agents such as long-term corticosteroids, azathioprine, mycophenolate and methotrexate have demonstrated only partial efficacy in preventing relapses of NMOSD and are associated with a significant number of adverse effects [6,30,31].

Our data in conjunction with the already published clinical trials demonstrate that the three monoclonal antibodies analyzed here are beneficial in long-term treatment of patients with NMOSD. Rituximab, a monoclonal antibody directed against CD20, prevents the differentiation of immature B cells into antibody producing plasma cells. Eculizumab binds C5, inhibiting an initial step in complement activation. Tocilizumab targets IL-6 receptors; hastening the destruction of AQP4-IgG producing B cells [32]. In sum, each of these agents interferes with some aspect of B cell directed humoral immunity lending further support to the role of AQP4-IgG, in the pathogenesis of NMOSD [1,5]. However, despite the very narrow immunological targeting of each of these monoclonal antibodies, treatment adverse effects were observed in 25.6% (83/324) of patients. Events such as infusion-related or allergic reactions ($< 10\%$ of patients) can be prevented with premedication, while others such as leukopenia (2.5% of patients), should resolve upon cessation of treatment. Events such as invasive fungal infections and PML were not observed in the current selected review, but have been reported elsewhere. Therefore, physicians must consider the risk-benefit ratio of monoclonal antibody therapy when initiating treatment. Moreover, we hasten to add that despite their efficacy, monoclonal antibody treatment comes at a significant price. Therapies such as rituximab and tocilizumab cost approximately \$18,000 annually where eculizumab's cost can exceed \$400,000 per year. Therefore, a patient's ability to pay must be strongly considered before initiating treatment with one of these agents.

In response to the limited therapeutic options available for patients with NMOSD, additional monoclonal antibodies are being investigated. Inebilizumab, an anti-CD19 antibody and satralizumab, an anti-IL-6 antibody (similar to tocilizumab) are currently in phase 3 trials and near completion [33,34]. Data from these trials may allow for greater provider flexibility when considering initiating or changing therapy in NMOSD patients.

While the overall results of our study were positive, there are some limitations to our meta-analysis. First, despite our best efforts to reduce heterogeneity between studies, high degrees of statistical heterogeneity in our base-case analysis for ARR was present ($I^2 = 82\%$). This level of between-study heterogeneity has been previously reported in the literature with a meta-regression analysis demonstrating no significant correlation between ARR and relevant covariants. As such, we believe that the heterogeneity reported does not influence

Study (Year) (N=)	Female (%)	Age at treatment onset, Mean \pm SD or (range) *	Disease duration at first infusion, Mean \pm SD or (range) *	Regimen	Therapy prior to experimental treatment	AQP4-IgG positive serostatus	Significant Adverse Events Reported (n)
Cabre (2018) (N=32)	93.7	39.9 +/- 12.1	7.4 +/- 11.1	Rituximab -375 mg/m ² q weekly \times 4 weeks	Naïve: 13% Immunosuppressive therapy: 87%	62.5%	Infection (2) -Pharyngitis (1) -UTI (1) Infusion/allergic (1)
Ellrichmann (2018) (N=21)	66.7	44.2 +/- 17.1	3.1 +/- 4.7	Rituximab -dosage and interval varied by patient	--	--	Infection (2) -PNA (1) -Reactivation of hepatitis B (1)
Kim (2018) (N=47)	89	34 (9-62)	13 (9-29)	Rituximab -375 mg/m ² q weekly \times 4 weeks or -1 g q 2 weeks \times 2	Naïve: 81% Immunosuppressive therapy: 19%	96%	--
Li (2018) (N=19)	84%	34.8 +/- 13.7	3.4 +/- 3.4	Rituximab -100 mg q weekly \times 3 weeks then retreatment when CD19+ count > 1%	Immunosuppressive therapy: 21% IVIg: 79%	89%	--
Lin (2018) (N=14)	100	32.9 +/- 13.6	--	Rituximab -375 mg/m ² once then retreatment when CD19+ count was >1%	--	93%	Infection (2) -URI (1) -Tuberculosis (1)
Yang (2018) (N=20)	95	40.7 +/- 11.4	0.9 (0-20)	Rituximab -100 mg q weekly \times 4 weeks	Naïve: 70% IVIg: 30%	50%	Infusion/allergic (1)
Cohen (2017) (N=40)	88	40.2 (22-64)	3.3 (0.2-13.8)	Rituximab -375 mg/m ² q weekly \times 4 weeks or -1 g q 2 weeks \times 2	Naïve: 50% Immunosuppressive therapy: 50%	75%	--
Evangelopoulos (2017) (N=5)	100	54 +/- 10.2	6.8 (6-9)	Rituximab -375 mg/m ² q weekly \times 4 weeks	Naïve: 40% Immunomodulatory therapy: 40% Immunosuppressive therapy: 20%	100%	Infection (4) -URI (3) -Herpes zoster (1)
Nikoo (2017) (N=33)	88	35.3 +/- 9.0	6.23 +/- 4.3	Rituximab -1 g q 2 weeks \times 2	--	39%	Infusion/allergic (4)
Radaelli (2016) (N=21)	86	41 (19-67)	7.4 (0.5-27)	Rituximab -375 mg/m ² q weekly \times 4 weeks or -1 g q 2 weeks \times 2	Naïve: 19% Immunomodulatory therapy: 10% Immunosuppressive therapy: 66% IVIg: 5%	81%	Infection (6) -CE (1) -UTI (2) -PNA (2) -Sepsis (1) Leukopenia (5)
Araki (2014) (N=7)	86	38.6 (23-62)	10.0 (2-19)	Tocilizumab -8 mg/kg q month w/ current therapy \times 12	Immunomodulatory therapy: 43% Immunosuppressive therapy: 43% IVIg: 14%	100%	Infection (3) -URI (2) -Pyelonephritis (1) Infusion/allergic (1) Leukopenia (3) Anemia (2) Enterocolitis (2)
Ip (2013) (N=7)	86	52 (22-62)	7.1 (0.17-21.83)	Rituximab -375 mg/m ² q weekly \times 4 weeks or -1 g q 2 weeks \times 2	--	--	Infusion/allergic (2)
Pitcock (2013) (N=14)	100	41.1 (18-68)	4.3 (0.4-20.5)	Ecilizumab -600 mg IV q weekly \times 4 weeks then -900 mg week 5 then -900 mg q 2 weeks \times 48 weeks	Naïve: 29% Immunosuppressive therapy: 42% Rituximab: 29%	100%	Infection (7) -UTI (2) -URI (2) -Bronchitis (1) -Sepsis (1) -Sterile meningitis (1) RA (1) TIA (1)
Yang (2013) (N=5)	--	35.2 (26-43)	6.8 (1.8-14)	Rituximab -100 mg q weekly \times 3 weeks then additional infusions at same dose when CD19+ >1%	Immunomodulatory therapy: 20% Immunosuppressive therapy: 80%	80%	Infusion/allergic (2)
Kim (2011) (N=30)	90	38.4 (23-58)	4.5 (0.5-12.9)	Rituximab -375 mg/m ² q weekly \times 4 weeks or -1g q 2 weeks	Naïve: 20% Immunomodulatory therapy: 53% Immunosuppressive therapy: 27%	70%	Infection (12) -Unspecified (12) Infusion/allergic (12)

Pellkofer (2011) (N=9)	90	36.7 (16-45)	10.4 (3-23)	Rituximab -1 g q 2 weeks × 2	Immunomodulatory therapy: 33% Immunosuppressive therapy: 45% IVIg: 22%	100%	Infection (7) -UTI (3) -PNA (1) -Adnexitis (1) -Herpes zoster (1) -Sepsis (1) Death (1)
-----------------------------------	----	--------------	-------------	--	--	------	---

Table 1: Baseline characteristics of patients in included prospective studies.

the observed reduction in ARR. A second limitation is the limited number of included studies and small sample sizes. Due to the absence of randomized controlled trials demonstrating efficacy of monoclonal antibody therapy in patients with NMO/NMOSD, we sought to increase the strength of evidence of our study by only including prospective trials (i.e., excluding retrospective studies, case reports and/or case series). The studies included in our analysis did not always distinguish between the diagnosis of NMO or NMOSD and these studies were not limited to AQP4-IgG positive serostatus patients. As a result, we were forced to combine clinical and outcomes data for both diseases and serostatuses in our analysis. Finally, due to inconsistent or incomplete reporting of clinical data, several studies had to be excluded from our meta-analysis, which may have resulted in possible publication bias.

Conclusion

Despite the inability to demonstrate comparative efficacy between agents, our systematic review did provide sufficient data to justify the use of monoclonal antibody therapy in patients with NMOSD, including those with disease refractory to other immunosuppressive agents. Taken in the context of multiple case reports and retrospective studies, our findings provide strong support for pursuit of a larger, multi-center randomized control clinical trial that would compare the efficacy of each of the currently available monoclonal antibodies and would better characterize their adverse risk profile.

Declarations

- **Ethics approval and consent to participate:** Not applicable.
- **Consent for publication:** Not applicable.
- **Availability of data and materials:** All data generated or analyzed during this study are included in this published article [and its supplementary information files].
- **Competing interests:** Not applicable.
- **Funding:** Not applicable.

Authors' Contributions

- **Conception and design:** Jonathan T Caranfa, Christine G Kohn, David M Waitzman.
- **Provision of study materials:** Jonathan T Caranfa, David M Waitzman.
- **Collection and assembly of data:** Jonathan T Caranfa, Christine G Kohn.
- **Data analysis and interpretation:** Jonathan T Caranfa, Christine G Kohn, William L Baker.
- **Manuscript writing:** Jonathan T Caranfa, Christine G. Kohn, William L Baker, David M Waitzman.
- **Final approval of manuscript:** All authors.
- **Accountable for all aspects of the work:** All authors.
- **Acknowledgements:** Not applicable.

References

1. Wingerchuk DM, Banwell B, Bennett JL (2015) International Panel for NMO Diagnosis. International Consensus Diagnostic Criteria For Neuromyelitis Optica Spectrum Disorders. *Neurology* 85: 177-189.
2. Damato V, Evoli A, Iorio R (2016) Efficacy and safety of rituximab therapy in neuromyelitis optica spectrum disorders: A systematic review and meta-analysis. *JAMA Neurol* 73:1342-1348.
3. Levin MH, Bennett JL, Verkman AS (2013) Optic neuritis in neuromyelitis optica. *Prog Retin Eye Res* 36: 159-171.
4. Jarius S, Ruprecht K, Wildemann B (2012) Contrasting disease patterns in seropositive and seronegative neuromyelitis optica: A multi-centre study of 175 patients. *J Neuroinflammation* 9:14.
5. Wingerchuk DM, Lennon VA, Lucchinetti CF (2007) The spectrum of neuromyelitis optica. *Lancet Neurol* 6: 805-815.
6. Etemadifar M, Salari M, Mirmosayyeb O (2017) Efficacy and safety of rituximab in neuromyelitis optica: Review of evidence. *J Res Med Sci* 22: 18.
7. Araki M, Matsuoka T, Miyamoto K (2014) Efficacy of the anti-IL-6 receptor antibody tocilizumab in neuromyelitis optica: a pilot study. *Neurology* 82: 1302-1306.
8. Pittock SJ, Lennon VA, McKeon A (2013) Eculizumab in AQP4-IgG-positive relapsing neuromyelitis optica spectrum disorders: an open-label pilot study. *Lancet Neurol* 12: 554-562.
9. Moher D, Liberati A, Tetzlaff J, Altman DG, PRISMA group (2009) Preferred Reporting Items for Systematic Reviews and Meta-Analyses: The PRISMA statement. *Ann Intern Med* 151:1-6.
10. Hartung J, Knapp G (2001) On tests of the overall treatment effect in meta-analysis with normally distributed responses. *Stat Med* 20:1771-1782.
11. Hartung J, Knapp G (2001) A refined method for meta-analysis of controlled clinical trials with binary outcomes. *Stat Med* 20: 3875-3889.
12. Paule RC, Mandel J (1982) Consensus values and weighting factors. *J Res Natl Bur Stand* 87: 377-385.
13. Higgins JP, Thomas SG, Deeks JJ (2003) Measuring inconsistency in meta-analyses. *BMJ* 327:557-560.
14. Egger M, Davey Smith G, Schneider M (1997) Bias in meta-analysis detected by a simple, graphical test. *BMJ* 315: 629-634.
15. Cabre P, Mejdoubi M, Jeannin S (2018) Treatment of neuromyelitis optica with rituximab: a 2-year prospective multicenter study. *J Neurol* 265: 917-925.
16. Cohen M, Romero G, Bas J (2017) Monitoring CD27+ memory B-cells in neuromyelitis optica spectrum disorders patients treated with rituximab: Results from a bicentric study. *J Neurol Sci* 373: 335-338.
17. Ellrichmann G, Bolz J, Peschke M (2019) Peripheral CD19(+) B-cell counts and infusion intervals as a surrogate for long-term B-cell depleting therapy in multiple sclerosis and neuromyelitis optica/neuromyelitis optica spectrum disorders *J Neurol*. 266: 57-67.
18. Evangelopoulos ME, Andreadou E, Koutsis G (2017) Treatment of neuromyelitis optica and neuromyelitis optic spectrum disorders with rituximab using a maintenance treatment regimen and close CD19 B cell monitoring. A six-year follow-up. *J Neurol Sci* 372: 92-96.
19. Ip VH, Lau AY, Au LW (2013) Rituximab reduces attacks in Chinese patients with neuromyelitis optica spectrum disorders. *J Neurol Sci* 324: 38-39.
20. Kim SH, Kim W, Li XF (2011) Repeated treatment with rituximab based on the assessment of peripheral circulating memory B cells in patients with relapsing neuromyelitis optica over 2 years. *Arch Neurol* 68: 1412-1420.
21. Kim SH, Kim Y, Kim G (2019) Less frequent rituximab retreatment maintains

- remission of neuromyelitis optica spectrum disorder, following long-term rituximab treatment. *J Neurol Neurosurg Psychiatry* 90: 486-487.
22. Li T, Zhang LJ, Zhang QX (2018) Anti-Rituximab antibody in patients with NMOSDs treated with low dose Rituximab. *J Neuroimmunol* 316: 107-111.
 23. Lin J, Li X, Xue B (2018) Low-dosage of rituximab in Chinese patients with neuromyelitis optica spectrum disorder. *J Neuroimmunol* 317:1-4.
 24. Nikoo Z, Badihian S, Shaygannejad V (2017) Comparison of the efficacy of azathioprine and rituximab in neuromyelitis optica spectrum disorder: A randomized clinical trial. *J Neurol* 264: 2003-2009.
 25. Pellkofer HL, Krumbholz M, Berthele A (2011) Long-term follow-up of patients with neuromyelitis optica after repeated therapy with rituximab. *Neurology* 76: 1310-1315.
 26. Radaelli M, Moiola L, Sangalli F (2016) Neuromyelitis optica spectrum disorders: long-term safety and efficacy of rituximab in Caucasian patients. *Mult Scler* 22: 511-519.
 27. Yang CS, Yang L, Li T (2013) Responsiveness to reduced dosage of rituximab in Chinese patients with neuromyelitis optica. *Neurology* 81: 710-713.
 28. Yang Y, Wang CJ, Wang BJ (2018) Comparison of efficacy and tolerability of azathioprine, mycophenolate mofetil, and lower dosages of rituximab among patients with neuromyelitis optica spectrum disorder. *J Neurol Sci* 385: 192-197.
 29. Bennett JL, De Seze J, Lana-Peixoto M (2015) Neuromyelitis optica and multiple sclerosis: Seeing differences through optical coherence tomography. *Mult Scler* 21: 678-688.
 30. Lemos MD, Carvalho GB, Carvalho RS (2015) Neuromyelitis optica spectrum disorders: beyond longitudinally extensive transverse myelitis. *Clin Radiol* 70: 630-637.
 31. Mealy MA, Wingerchuk DM, Palace J (2014) Comparison of relapse and treatment failure rates among patients with neuromyelitis optica: multicenter study of treatment efficacy. *JAMA Neurol* 71: 324-330.
 32. Lin J, Xue B, Li X (2017) Monoclonal antibody therapy for neuromyelitis optica spectrum disorder: current and future. *Int J Neurosci* 127: 735-744.
 33. Cree B, Bennett J, Jin H, Brian K, Weinshenker SP, et al. (2016) A double-masked, placebo-controlled study with open label period to evaluate MEDI-551 in neuromyelitis optica and neuromyelitis Optica Spectrum Disorders. National Institutes of Health.
 34. US Library of Medicine (2014) Efficacy and safety study of satralizumab (SA237) as monotherapy to treat participants with neuromyelitis optica (NMO) and neuromyelitis optica spectrum disorders (NMOSD). *Clinical Trials*.