

## Misdiagnosing Bronchiectasis and Lymphangioleiomyomatosis

Malihe Ghadir\* and Katayoon Najafizadeh

Lung Transplantation Research Center, NRITLD, Masih Daneshvari Hospital, Shahid Beheshti University of Medical Sciences, Tehran, Iran

### Abstract

This report presents a 25 year old female with a history of exertional dyspnea since the age of three. She was wrongly diagnosed and managed as bronchiectasis although she had had no productive cough or recurrent infection. At the age of 23, because of her dyspnea she was referred to a pneumologist for the first time. High resolution computed tomography and open lung biopsy was performed at that time. High resolution computed tomography showed diffuse thin walled cysts and pathologic results also confirmed lymphangioleiomyomatosis as her definite diagnose. She was treated with sirolimus and progesterone for two years which resulted in significant increase in oxygen saturation. However, no change was seen in forced expiratory volume at first second.

**Keywords:** Bronchiectasis; Lymphangioleiomyomatosis; Sirolimus

### Introduction

Lymphangioleiomyomatosis (LAM) is a rare, cystic lung disease that most commonly affects young females [1,2] between menarche and menopause [3]. Case reports of LAM have been mentioned in a few men [4] and children [5,6]. LAM cells accumulate within lungs and axial lymphatics. Cystic lesions associated with LAM progressively destruct lung structure [7]. Ultimately it results in progressive dyspnea, recurrent pneumothorax, chylouse collection and occasional hemoptysis. Extrapulmonay manifestations are lymphadenopathy and cystic masses of the axial lymphatics termed as lymphangioleiomyomatosis [8].

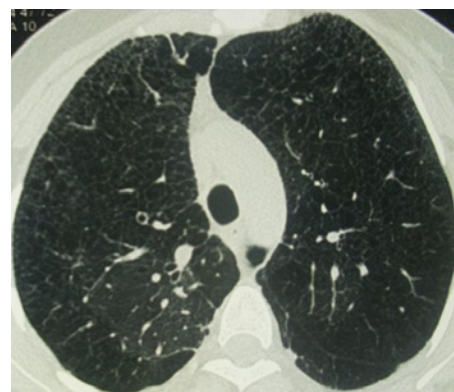
LAM is often wrongly diagnosed as obstructive lung disease such as asthma or bronchitis [9]. The disease follows an insidious course and the rate of progression is variable ranging from a few years to over three decades before culminating in respiratory failure [10]. The current treatment is primarily based on the antagonism of estrogen action but it is empiric and lacks of evidence [11]. Sirolimus is being explored as another potential treatment, but additional trials will be needed to assess its efficacy and potential side effects [12,13]. However, pulmonary transplantation remains the last option for patients with LAM [3].

This report presents a young female with LAM who was misdiagnosed and mismanaged as bronchiectasis since her childhood.

### Case Presentation

A 23 year old female came to the lung transplant clinic with complaint of exertional dyspnea. She had a sever dyspnea attack when she was three years old which was followed by exertional dyspnea since then. Productive cough was only present during respiratory infection which she had had occasionally and was mistakenly diagnosed as bronchiectasis. No further evaluation to find the underlying causes of brochiectasis was performed and no treatment was planned for her. She was only warned about respiratory infection by her pediatrician. She was suffering from exertional dyspnea since then till she encountered an exacerbation and was referred to pneumologist for the first time. She experienced no other respiratory symptoms.

On physical examination at her arrival in our clinic, clubbing on both hands was observed and auscultation revealed the presence of fine inspiratory crackles on both lungs. Her blood values including her immunoglobulin levels were normal. On 6-minute walking test (6MWT) she walked 324 meters without oxygen and her O<sub>2</sub> saturation fell from 65% to 50%. Pulmonary function test revealed moderate obstructive pulmonary disorder with FEV<sub>1</sub> 52% of predicted values, FVC 67% and FEV<sub>1</sub>/FVC 67.5%. Interstitial opacities were seen in chest x-ray. HRCT showed diffuse thin walled cysts (Figure 1). Abdominal



**Figure 1:** High-resolution CT scan reveals diffuse small thin walled cysts in both lungs.

CT scan was normal. The echocardiogram showed normal systolic function, mild RV dilatation and elevated pulmonary artery pressure.

She was reevaluated by pneumologist and based on her history, physical examination, PFT and HRCT, she considered LAM as her possible diagnosis. Open lung biopsy was carried out and pathologic results showed diffuse cystic structures associated with smooth muscle cells proliferation which was led to LAM as her definite diagnoses, but because of her worse respiratory conditions she was referred to our center for lung transplantation.

In her first visit to our center, medroxyprogesteron and sirolimus were started and continued for 24 months. After that period of treatment the FEV<sub>1</sub> and FVC were measured which was rose by 50% and 69% respectively. On 6MWT she could walk 416 meters and her oxygen saturation which was 84% at rest decreased to 67% after performing the test that was significantly improved than the previous years. During sirolimus therapy she had recurrent oral aphthous ulcers

**\*Corresponding author:** Ghadir Malihe, NRITLD, Lung Transplantation Research Center, NRITLD, Masih Daneshvari Hospital, Shahid Beheshti University of Medical Sciences, Tehran, Iran, E-mail: [Ghadirm12@gmail.com](mailto:Ghadirm12@gmail.com)

**Received** January 04, 2013; **Accepted** February 25, 2013; **Published** February 28, 2013

**Citation:** Ghadir M, Najafizadeh K (2013) Misdiagnosing Bronchiectasis and Lymphangioleiomyomatosis. J Pulmon Resp Med 3: 139. doi:10.4172/2161-105X.1000139

**Copyright:** © 2013 Ghadir M, et al. This is an open-access article distributed under the terms of the Creative Commons Attribution License, which permits unrestricted use, distribution, and reproduction in any medium, provided the original author and source are credited.

and increased rate of mild upper respiratory tract infections, but none of other sirolimus side effects was observed.

## Discussion

LAM is a cystic lung disease with variable progression rate [14]. The incidence of LAM is estimated around 1-2.6 per 1000000 women [15] but its true incidence is not clear because it is usually mistakenly diagnosed as other obstructive lung disease such as asthma and COPD [12]. And because of that, its diagnosis usually takes 3 to 5 years after onset of respiratory symptoms [1]. Our case is unique because LAM was misdiagnosed for 23 years as bronchiectasis.

LAM predominantly affects women in childbearing years [13] but, in a lesser extent, it has been reported in men, children and postmenopausal women [12,16]. In 1988, the first pediatric case of LAM was reported in a 12 year old girl [5]. One year later, in 1989, Sakano et al. reported another 13 year old prepubertal girl with LAM [6].

An exertional dyspnea without recurrent infection or other bronchiectatic signs (e.g. productive cough) should always raise a suspicion for another disease, i.e. LAM. However, because of its rarity and unfamiliarity of physician especially general physicians with this rare disease, it can easily be missed and diagnosed wrongly.

Dyspnea is the most common presenting symptom in patients with LAM which occurs in about three quarter of patients. Spontaneous pneumothorax, hemoptysis, chylothorax and chest pain are less common manifestations of LAM disease that occur in 43%, 14%, 12% and 12% of patients respectively [2,8]. However, LAM could be asymptomatic too [17,18]. Lymphadenopathy and lymphangioleiomyomatosis are extrapulmonary manifestations of LAM. Lymphangioleiomyomas are cystic masses of the axial lymphatics that can cause abdominopelvic lymphatic obstruction [1,19].

Our patient has never experienced hemoptysis, pneumothorax or chylouseffusion. Abdominal CT scans showed no lymphangioleiomyomas but HRCT and open lung biopsy confirmed her diagnose. She had significant clubbing that led physicians to diagnose of bronchiectasis. Although clubbing is an uncommon manifestation of LAM but it can be seen in less than 5% of cases [10].

It is unclear that early treatment could prevent LAM's progression and till now no effective treatment has been established [3]. Its treatment is primarily based on antagonism of estrogen action [11]. There have been no randomized controlled trials on the efficacy of progesterone to treat LAM, but in some case reports and case series it has been observed to be valuable in some patients.

Sirolimus (Rapamycin) which is a novel macrolid agent and acts as an mTOR inhibitor and immunosuppressive drug in solid organ transplantations and as a chemotherapeutic drug in various type of cancers, is another agent that showed effectiveness in treatment of LAM [20]. Bissler et al. conducted 24 months nonrandomized open label trial in which they treated tuberous sclerosis or LAM patients with sirolimus for one year. They concluded that one year treatment with sirolimus caused improvement in lung function and reduction in the size of lymphangioleiomyomas. After one year the drug was discontinued, though the size of angioleiomyomas increased and the FEV1 decreased but they never completely returned to base line values [21].

Spirometry findings in LAM patients revealed a restrictive pattern in initial stages and an obstructive pattern in late stages of disease progression [20]. Our patient also showed an obstructive pattern in her spirometry. Although, her FEV1 did not increase after two years of

treatment with sirolimus, it did not worse either. 6MWT is a helpful test in assessing cardiopulmonary function in LAM patients [19,20]. Our patient walked only 324 meters at the beginning of the therapy and her oxygen saturation fell from 65% at rest to 59% after test but after one year of treatment with sirolimus she was able to walk 416 meters and her oxygen saturation dropped from 84% at rest to 67% after waking that distance.

By presenting this case we would like to emphasize on the fact that LAM can easily be misdiagnosed especially in children. Diagnosis of bronchiectasis especially in a child should be made very cautiously and after through evaluations and investigations to find the underlying cause and to treat it appropriately. Our case report in combination with other case reports that confirmed the misdiagnosis of LAM in children, persuade the pediatricians to consider LAM in children with unexplained pulmonary symptoms [5]. We also demonstrated that sirolimus could be an effective alternative in treatment of LAM patients although further studies are required to establish its value.

## References

1. McCormack FX (2008) Lymphangioleiomyomatosis: a clinical update. *Chest* 133: 507-516.
2. Lu SH, Hou YY, Tan YS, Xu JF, Zeng HY, et al. (2009) Clinical and histopathological alterations of lymphangioleiomyomatosis in 14 Chinese patients. *Chin Med J* 122: 1895-1900.
3. McCormack FX (2006) Lymphangioleiomyomatosis. *MedGenMed* 8: 15.
4. Hancock E, Osborne J (2002) Lymphangioleiomyomatosis: a review of the literature. *Respir Med* 96: 1-6.
5. Nussbaum E, Groncy P, Finklestein J, Dickman P, Harrell JH 3rd (1988) Early onset of childhood pulmonary lymphangiomyomatosis. *Clin Pediatr (Phila)* 27: 279-284.
6. Sakano T, Hamasaki T, Kawaguchi Y, Tanaka Y, Ueda K, et al. (1989) Pulmonary lymphangiomyomatosis in childhood? Marked smooth muscle cell proliferation of the lung in a preadolescent girl with repeated pneumothorax and progressive dyspnea. *Hiroshima J Med Sci* 38: 147-149.
7. Taveira-DaSilva AM, Pacheco-Rodriguez G, Moss J (2010) The natural history of lymphangioleiomyomatosis: markers of severity, rate of progression and prognosis. *Lymphat Res Biol* 8: 9-19.
8. Johnson SR (2006) Lymphangioleiomyomatosis. *Eur Respir J* 27: 1056-1065.
9. Johnson SR, Cordier JF, Lazor R, Cottin V, Costabel U, et al. (2010) European Respiratory Society guidelines for the diagnosis and management of lymphangioleiomyomatosis. *Eur Respir J* 35: 14-26.
10. Hohman DW, Noghrehkar D, Ratnayake S (2008) Lymphangioleiomyomatosis: A review. *Eur J Intern Med* 19: 319-324.
11. Johnson SR, Tattersfield AE (2002) Lymphangioleiomyomatosis. *Semin Respir Crit Care Med* 23: 85-92.
12. Neuhr C, Hoffmann AL, Huppmann P, Herrera VA, Ihle F, et al. (2011) Is sirolimus a therapeutic option for patients with progressive pulmonary lymphangioleiomyomatosis? *Respir Res* 12: 66.
13. McCormack FX, Inoue Y, Moss J, Singer LG, Strange C, et al. (2011) Efficacy and safety of sirolimus in lymphangioleiomyomatosis. *N Engl J Med* 364: 1595-1606.
14. Taveira-Dasilva AM, Steagall WK, Moss J (2009) Therapeutic options for lymphangioleiomyomatosis (LAM): where we are and where we are going. *F1000 Med Rep* 1.
15. Harari S, Caminati A (2010) Update on diffuse parenchymal lung disease. *Eur Respir Rev* 19: 97-108.
16. Ryu JH, Moss J, Beck GJ, Lee JC, Brown KK, et al. (2006) The NHLBI lymphangioleiomyomatosis registry: characteristics of 230 patients at enrollment. *Am J Respir Crit Care Med* 173: 105-111.
17. Hancock E, Tomkins S, Sampson J, Osborne J (2002) Lymphangioleiomyomatosis and tuberous sclerosis. *Respir Med* 96: 7-13.

- 
18. Juvet SC, Hwang D, Downey GP (2006) Rare lung diseases I-- Lymphangioleiomyomatosis. *Can Respir J* 13: 375-380.
  19. Glasgow CG, Steagall WK, Taveira-Dasilva A, Pacheco-Rodriguez G, Cai X, et al. (2010) Lymphangioleiomyomatosis (LAM): molecular insights lead to targeted therapies. *Respir Med* 104 Suppl 1: S45-58.
  20. Chorianopoulos D, Stratakis G (2008) Lymphangioleiomyomatosis and tuberous sclerosis complex. *Lung* 186: 197-207.
  21. Bissler JJ, McCormack FX, Young LR, Elwing JM, Chuck G, et al. (2008) Sirolimus for angiomyolipoma in tuberous sclerosis complex or lymphangioleiomyomatosis. *N Engl J Med* 358: 140-151.